

## A remarkable intestinal lipoma case

### İlginç bir intestinal lipom olgusu

Şafak KIZILTAŞ,<sup>1</sup> Elif YORULMAZ,<sup>1</sup> Bülent BİLİR,<sup>2</sup> Feruze ENÇ,<sup>1</sup> İlyas TUNCER<sup>1</sup>

A 37-year-old female patient with a history of iron deficiency anemia for three years had been hospitalized and followed up with subileus. An obstruction at the proximal part of the jejunum was found by enteroclysis method and a filling defect due to a polypoid mass was determined. The small intestine was resected. It was reported as a submucosal lipoma based on results of the histopathological examination. In conclusion, benign tumors of the small intestine, including intestinal lipomas, should be considered during the diagnostic process of clinical ileus and anemia.

**Key Words:** Anemia; enteroclysis; lipoma.

Üç yıldır, demir eksikliği ve anemi şikayetleri olan otuz yedi yaşındaki kadın hasta, subileus nedeniyle hastaneye yatırılarak takibe alındı. Enteroklizis yöntemiyle jejunumun proksimal kısmında bir tıkanıklık ve polipoid kitleye ait dolma defekti gözlemlendi. Hastaya, ince bağırsak rezeksiyonu yapıldı. Histopatolojik değerlendirme sonucu submukozal lipomdu. Sonuç olarak, klinik ileus ve aneminin tanısal sürecinde lipomu da içeren ince bağırsak selim tümörleri göz önünde tutulmalıdır.

**Anahtar Sözcükler:** Anemi; enteroklizis; lipom.

The most frequently seen benign tumors of the small intestine are adenomas, leiomyomas and lipomas, respectively.<sup>[1]</sup> Lipomas are benign intramucosal tumors originating from mature lipocytes. They are generally identified casually during endoscopy and colonoscopy. While they may be seen in any segment of the gastrointestinal tract, they are observed more frequently in the distal ileum and ileocecal valve.<sup>[2]</sup> Less than 30% of lipoma cases reported in the literature are symptomatic.<sup>[3]</sup> While large lesions cause intestinal obstruction by mass effect, submucosal lipomas are reported to cause bleedings by inducing ulcerations in the mucosal surface.<sup>[4]</sup> Because they have no malignancy potential, asymptomatic lipomas are not necessarily removed. The treatment of symptomatic cases is surgical resection.<sup>[5,6]</sup>

We present herein a case with an approximately three-year history of iron deficiency anemia who

was referred for surgery due to a mass in the jejunum and was subsequently diagnosed histopathologically with “intestinal lipoma” following the surgical resection.

### CASE REPORT

A 37-year-old female patient presented to the emergency room of the hospital due to abdominal pain, nausea, vomiting, and inability to pass feces/gas, and had been hospitalized and followed up with subileus. The patient applied to our center due to persistence of her abdominal pain for four months. She had a history of iron deficiency anemia for three years, which was not responding to oral treatment and of a cholecystectomy five years before. Physical examination in our center revealed conjunctival paleness and subcostal incision scar in the right upper quadrant; no tenderness was present on deep palpation except around the periumbilical area.

Departments of <sup>1</sup>Gastroenterology and <sup>2</sup>Internal Medicine, Göztepe Training and Research Hospital, Istanbul, Turkey.

Göztepe Eğitim ve Araştırma Hastanesi, <sup>1</sup>Gastroenteroloji Kliniği, <sup>2</sup>İç Hastalıkları Kliniği, İstanbul.

Correspondence (İletişim): Elif Yorulmaz, M.D. Ebu Suud Cad., No: 67, 34460 Sirkeci, İstanbul, Turkey.  
Tel: +90 - 216 - 566 40 00 e-mail (e-posta): elifdahiliye@gmail.com

Laboratory results were as follows: hemoglobin (Hb): 7.9 g/dl, hematocrit (Hct): 24%, mean corpuscular volume (MCV): 78 fl, white blood cells (WBC): 7100/mm<sup>3</sup>, and platelets (PLT): 291000/mm<sup>3</sup>. Biochemical values were within normal range. Direct abdominal radiography taken in the standing position revealed one air-liquid level at the left upper quadrant. Total abdominal ultrasound and upper abdominal computed tomography (CT) revealed excess intraabdominal gas and no other pathology. Hyperemia was observed in the lower end of the esophagus in the upper gastrointestinal endoscopy. Colon radiography with barium was reported as normal. Jejunal and ileal loops revealed increase in wall thickness by total abdominal magnetic resonance imaging, but no mass formation was observed. The colon and terminal ileum were determined to be normal in the colonoscopy.

An obstruction at the proximal part of the jejunum was found by enteroclysis studies, and a filling defect due to a polypoid mass and dilated intestinal loops proximal to the obstructed segment were determined (Figs. 1a, b). The size of the mass was reported as 20 x 40 mm. No radiological pathological finding was observed in the distal jejunal loops, proximal ileal loops or pelvic ileal loops. Transit time to colon was 90 minutes, which is prolonged compared to the normal values. In light of these findings, the mass was first considered as an adenomatous polyp or polypoid carcinoma, and surgical intervention was planned due to its symptomatic nature. The small intestine of the patient was resected and a hemorrhagic polypoid mass, 40 x 40 x 20 mm and dirty yellow in color, was observed in patches. It was reported to be a submucosal lipoma

based on the results of the histopathological examination (Figs. 2a, b). There was no complaint during the follow-up of the patient, and Hb and Hct were 13 g/dl and 40%, respectively.

## DISCUSSION

Small bowel neoplasms are uncommon. Benign and malignant neoplasms of the small bowel account for only a small fraction of all gastrointestinal neoplasms.<sup>[3]</sup> Early detection and treatment are the most significant variables for outcome in small bowel tumors.<sup>[7,8]</sup> The variable nature of the symptoms, combined with the lack of physical findings, contributes to delay in diagnosis in many cases.<sup>[9]</sup> In one study, failure to obtain a proper diagnostic test or misinterpretation of the results accounted for delays of 8 and 12 months, respectively; in comparison, delay due to the patient's failure to report symptoms was less than two months.<sup>[8]</sup> It is very difficult to diagnose intestinal lipoma without development of a symptom.<sup>[10]</sup> Less than 30% of those lesions are reported to be symptomatic; moreover, it is known that approximately 70% of them are determined as a result of a surgical intervention due to an unrelated cause or as an autopsy finding.<sup>[3]</sup>

Intestinal lipomas usually express themselves clinically by occult hemorrhagia leading to weakness and tiredness as a result of the subsequent anemia or by a subileus-ileus profile due to obstruction or intussusception development because of the mass.<sup>[11]</sup> Our patient had been diagnosed with iron deficiency anemia for three years, which was not responding to oral treatment, and she was hospitalized with subileus.

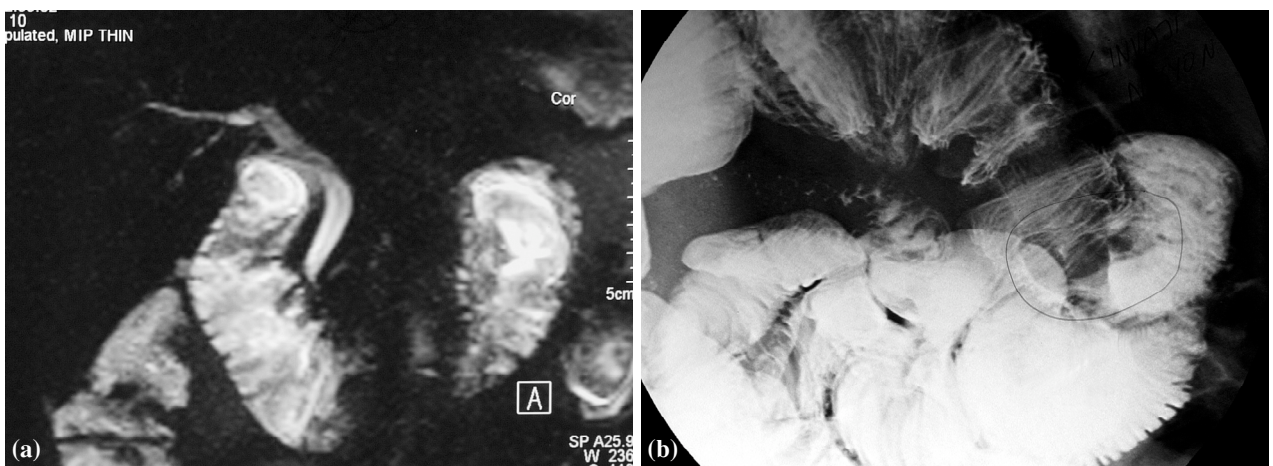


Fig. 1. (a, b) Enteroclysis examination showing a polypoid mass in the proximal jejunum.

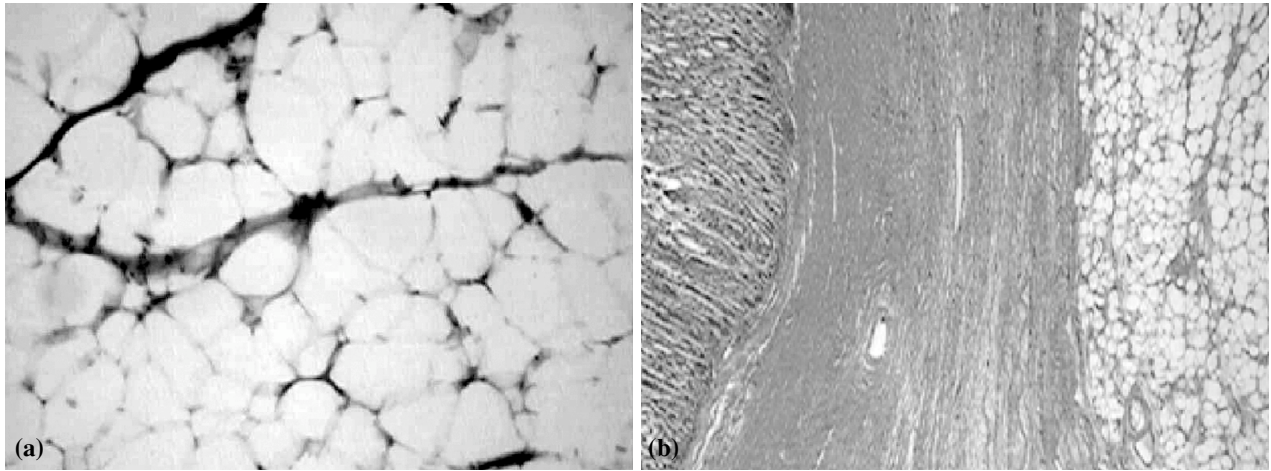


Fig. 2. (a, b) Submucosal lipoma appearance in histopathological examination of the lesion.

Preoperative diagnosis of these lesions is very difficult.<sup>[12]</sup> Radiology-surgery correlation in determining primary small intestinal tumors was found to be 100% in one study.<sup>[10]</sup> Benign tumors in the small intestine do not have a characteristic CT appearance and, in most instances, cannot be differentiated from malignant lesions. Lipomas can be definitively diagnosed by the recognition of fat attenuation within the mass.<sup>[13]</sup> In our case, upper abdominal CT revealed excess intraabdominal gas without giving a diagnosis. Examination of the small intestine by enteroclysis method determined a mass 40 x 20 mm in size in the jejunum, and adenomatous polyp or polypoid carcinoma were suspected as the radiological diagnosis; however, the surgical histopathological diagnosis was submucosal lipoma. This led to the conclusion that while the findings of a mass quite large in size and with atypical localization via enteroclysis method were correlated surgically and radiologically, they were not correlated with the histopathological diagnosis. Moreover, in our case, there was an iron deficiency anemia that had been non-responsive to treatment for three years. Since the most frequently encountered causes of iron deficiency anemia are reduction of iron absorption through the gastrointestinal system and low dietary iron intake, in order to prevent delays in diagnosis of occult malignancies and bleeding intestinal lesions, these diagnoses should be ruled out first.<sup>[14]</sup> The NHANES 1 study reported 9,024 individuals including males with iron deficiency anemia and postmenopausal females who were followed up for two months.

An increase in gastrointestinal malignancy was determined compared to the control group without iron deficiency anemia.<sup>[15]</sup> In a prospective study per-

formed on 100 patients with occult fecal blood, the underlying cause was determined in 62 patients by colonoscopy and esophagogastroduodenoscopy.<sup>[16]</sup> Because it was difficult to reach the small intestine through routine endoscopy, lesions of the small intestine could be diagnosed only after many months. Enteroclysis is a good and well-tolerated method in determining small intestinal tumors. It is much more sensitive than the conventional barium examinations and less invasive than enteroscopy. It is a method that can be used solely to determine the characteristics and stage of a given tumor.<sup>[17,18]</sup>

In conclusion, the diagnosis of small bowel tumors is often made late in the course of the disease because the condition is rare and the symptoms are nonspecific and of a variable nature. Benign tumors of the small intestine, including intestinal lipomas, should be considered during the diagnostic process of clinical ileus and anemia. However, while investigating the etiology of iron deficiency anemia, if small intestinal tumors are suspected, evaluation with enteroclysis method increases the value of preoperative diagnosis.

## REFERENCES

1. Lance P. Tumors and other neoplastic diseases of the small intestine. In: Yamada T, Alplers DH, Laine L, Owyang C, Powell DW, editors. Textbook of gastroenterology. 3rd ed. Lippincott Williams and Wilkins; 1999. p. 1722-38.
2. Hunt GC, Smith PP, Faigel DO. Yield of tissue sampling for submucosal lesions evaluated by EUS. *Gastrointest Endosc* 2003;57:68-72.
3. Fordtran JS, Sleisenger I. Small intestinal neoplasms. Textbook of gastrointestinal disease. 7th ed. 2002. p. 113: 2169-74.
4. Stoianov Kh, Arabadzhiev G, Zafirov G, Vasilev I. Clinical signs, diagnostics and treatment of the benign mesenchymal

- (submucosal) tumors of the gastrointestinal tract. [Article in Bulgarian] *Khirurgiia (Sofia)* 2004;60:40-3. [Abstract]
5. Ashley SW, Wells SA Jr. Tumors of the small intestine. *Semin Oncol* 1988;15:116-28.
  6. Zollinger RM Jr. Primary neoplasms of the small intestine. *Am J Surg* 1986;151:654-8.
  7. Maglinte DD, O'Connor K, Besette J, Chernish SM, Kelvin FM. The role of the physician in the late diagnosis of primary malignant tumors of the small intestine. *Am J Gastroenterol* 1991;86:304-8.
  8. North JH, Pack MS. Malignant tumors of the small intestine: a review of 144 cases. *Am Surg* 2000;66:46-51.
  9. Ciresi DL, Scholten DJ. The continuing clinical dilemma of primary tumors of the small intestine. *Am Surg* 1995;61:698-703.
  10. Nagi B, Verma V, Vaiphei K, Kochhar R, Bhasin D, Singh K. Primary small bowel tumors: a radiologic-pathologic correlation. *Abdom Imaging* 2001;26:474-80.
  11. Hozo I, Perkovic D, Grandic L, Kladije G, Simunic M, Piplovic T. Colonic lipoma intussusception: a case report. *Med Arh* 2004;58:382-3.
  12. Calvo AM, Montón S, Rubio T, Repiso M, Sarasibar H. Intestinal invagination in the adult secondary to jejunal lipoma. [Article in Spanish] *An Sist Sanit Navar* 2005;28:115-8. [Abstract]
  13. Kazerooni EA, Quint LE, Francis IR. Duodenal neoplasms: predictive value of CT for determining malignancy and tumor resectability. *AJR Am J Roentgenol* 1992;159:303-9.
  14. Annibale B, Capurso G, Chistolini A, D'Ambra G, DiGiulio E, Monarca B, et al. Gastrointestinal causes of refractory iron deficiency anemia in patients without gastrointestinal symptoms. *Am J Med* 2001;111:439-45.
  15. Ioannou GN, Rockey DC, Bryson CL, Weiss NS. Iron deficiency and gastrointestinal malignancy: a population-based cohort study. *Am J Med* 2002;113:276-80.
  16. Rockey DC, Cello JP. Evaluation of the gastrointestinal tract in patients with iron-deficiency anemia. *N Engl J Med* 1993;329:1691-5.
  17. Bender GN, Maglinte DD, Klöppel VR, Timmons JH. CT enteroclysis: a superfluous diagnostic procedure or valuable when investigating small-bowel disease? *AJR Am J Roentgenol* 1999;172:373-8.
  18. Orjollet-Lecoanet C, Ménard Y, Martins A, Crombè-Ternamian A, Cotton F, Valette PJ. CT enteroclysis for detection of small bowel tumors. [Article in French] *J Radiol* 2000;81:618-27. [Abstract]