

Decompressive craniectomy in traumatic brain injury: Transcranial Doppler sonography used as a guide

✉ Ramazan Sarı, M.D.,¹ ✉ Fatih Han Bölükbaşı, M.D.,² ✉ Eylem Burcu Kahraman Özlü, M.D.,¹
✉ Nejat Işık, M.D.,³ ✉ Melek Güra Çelik, M.D.,⁴ ✉ İlhan Elmacı, M.D.¹

¹Department of Neurosurgery, Acıbadem Maslak Hospital, İstanbul-Turkey

²Department of Neurosurgery, Rumeli University Faculty of Health Sciences, İstanbul-Turkey

³Department of Neurosurgery, İstanbul Medeniyet University, Göztepe Training and Research Hospital, İstanbul-Turkey

⁴Department of Anesthesia and Reanimation, İstanbul Medeniyet University, Göztepe Training and Research Hospital, İstanbul-Turkey

ABSTRACT

BACKGROUND: Decompressive craniectomy (DC) is performed in the management of intracranial hyper-tension after traumatic brain injury (TBI). This study aims to investigate the effects of transcranial Doppler ultrasonography (TCD) measurements on the indication of decompressive surgery.

METHODS: Sixteen TBI patients with a Glasgow Coma Score (GCS) <9 were included in this study. Intra-cranial pressure (ICP) monitoring and transcranial Doppler ultrasonography (TCD) measurements were recorded continuously. DC was performed according to the records of ICP and TCD. Glasgow Outcome Scale (GOS) scores were evaluated after three months.

RESULTS: Mean age of the patients was 31.18±17.51; GCS ranged between three and 14 with a mean of 9.62±3.95. Mean GOS was 3.12±1.85. Craniectomy was performed in two patients (12.5%) and craniectomy and lobectomy together were performed in 14 (87.5%) of them. The decline in ICP (22.12±10.41, 22.62±7.35, 15.50±6.64) and pulsatility index (PI) (1.96±1.10, 1.64±0.75, 1.91±2.48) were strongly significant between days 3–5, and 1–5. The range of PI and Vmax values through five days did not present any significance.

CONCLUSION: TCD, as a real-time monitor, may help for an early decision of surgical approach in the management of TBI patients.

Keywords: Decompressive craniectomy; neurointensive care; transcranial Doppler ultrasonography; traumatic brain injury.

INTRODUCTION

Traumatic brain injury causes brain edema and intracranial hypertension, which may lead to secondary brain insults. The Brain Trauma Foundation guidelines state that DC must be considered for the evacuation of a space-occupying lesion or in cases with diffuse brain swelling and intracranial hypertension due to intensive medical management.^[1–5]

DC is the removal of an area of the skull to augment the volume of the intracranial compartment. DC was first described by Kocher in the treatment of post-traumatic brain oedema in 1901. Even though the procedure is being performed in

rapidly relieving intracranial hypertension, there are no clear guidelines for indications and optimal timing of the DC.^[6] Several retrospective and prospective studies suggested the efficacy of DC in decreasing ICP and improve the outcome in patients with refractory intracranial hypertension following TBI. Massive oedema and brain swelling are the clinical conditions that lead the therapy to DC. Compression of the brain, as well as the impairment in cerebral blood flow, are the adverse effects of intracranial hypertension.^[3,5,6] ICP monitoring is the gold standard in TBI patients and PI of TCD sonography is correlated with ICP, the effects of ICP monitoring and TCD sonography to guide the medical and surgical treatment protocols are investigated in this study.

Cite this article as: Sarı R, Bölükbaşı FH, Kahraman Özlü EB, Işık N, Güra Çelik M, Elmacı İ. Decompressive craniectomy in traumatic brain injury: Transcranial Doppler sonography used as a guide. *Ulus Travma Acil Cerrahi Derg* 2020;26:418–424.

Address for correspondence: Ramazan Sarı, M.D.

Acıbadem Maslak Hastanesi, Beyin ve Sinir Cerrahisi Kliniği, İstanbul, Turkey

Tel: +90 212 - 304 44 44 / 5648 E-mail: drramazan@windowslive.com

Ulus Travma Acil Cerrahi Derg 2020;26(3):418-424 DOI: 10.14744/tjtes.2020.04640 Submitted: 27.09.2019 Accepted: 15.01.2020 Online: 15.05.2020

Copyright 2020 Turkish Association of Trauma and Emergency Surgery



MATERIALS AND METHODS

After the institutional ethical committee approved and informed consents waived, 52 TBI patients treated aggressively in the neurointensive care unit of Ministry of Health Goztepe Training Hospital were prospectively reviewed. Of these 52 patients (post-resuscitation GCS <9 in the emergency department, unilateral or bilateral motor posturing and computed tomography (CT) scans defined according to Marshall Classification and the patients who receded to lower GCS in the following days), 16 patients with an intracranial mass lesion on the admission CT, an abnormality of intracranial hemodynamic or who needed DC despite the medical management protocol were included in this study.^[7] Patients who died within five days of admission, who had organ failure or severe infection before admission were excluded from this study. The neurological and hemodynamic status of the patients was assessed and the patients were intubated and mechanical ventilation was performed consequently. The CT scans of the patients were performed according to the cerebral and hemodynamic status of the patients on the following days. The control of elevated ICP was considered according to the guidelines of the Brain Trauma Foundation. Once admitted to the intensive care unit, mean arterial pressure of 90 mmHg, CPP 60–70 mmHg, ICP <20 mmHg, central venous pressure 5–10 mmHg, SaO₂ >95% and PaCO₂ of 30–35 mmHg were targeted. The head of the patients was routinely elevated at 30° up to improve jugular venous return. Anticonvulsants were performed in case of seizures. Euvolemia, normothermia and normoglycemia were considered. Antibiotic therapy for the intracranial process was performed with vancomycin, according to the guidelines of the Local Committee of Infection. GOS of the patients were evaluated after three months. GOS 1–3 was evaluated as unfavourable and GOS 4–5 was evaluated as a favourable outcome.

The elevation of ICP was managed in three steps, moving from one step to another if the ICP values remained constant.^[8]

Step 1- If ICP >20 mmHg, slight hyperventilation and targeting a PCO₂ of 35 mmHg.

Step 2- Mannitol 20% 0.5–1.0 g/kg performed with intermittent boluses watching for plasma osmolarity <320 mOsm/kg. High doses of mannitol (1.4 g/kg) used when ICP >30–40 mmHg. CPP maintained at a minimum of 60 mmHg with fluid administration, vasopressors like dopamine or norepinephrine in cases of low arterial pressure values.

Step 3- If ICP remained high, following CT scan, barbiturates and early decision for decompressive craniectomy were considered.

Arterial blood pressure was monitored in all patients by radial artery catheter. A parenchymal catheter with a fiberoptic

tip transducer into the frontal region or an intraventricular catheter (Integra MPM-1) was placed. The ICP catheters were inserted for five days and the catheters were changed if a longer period was required. ICP was measured continuously in software data. CPP was calculated from the difference between mean arterial pressure and ICP. Daily TCD mean flow velocity measurements of MCA were made by bilaterally and continuously. The TCD measurements were conducted transtemporally using a traditional 2 MHz transducer (DWL). The depth and angle of insonation, giving the highest mean flow velocity were chosen. Pathological PI values were considered as PI >1.0. The PI was calculated according to the Gosling index, from the difference between end-systolic and diastolic MCA velocities divided by the mean MCA velocity.

For the statistical analysis, the first, third and fifth days measurements were considered. The statistical analysis was performed in SPSS 15.0 for Windows for data processing and analysis. The definitive analysis was used for mean, standard deviation, minimum and maximum variables. Pearson's Correlation Analysis[®] for correlations, paired samples t-test for the differences between days was used. Simple Linear Regression analysis was used to achieve the effects of ICP upon PI. The statistical significance of the correlation between the investigated quantitative variables was achieved by the p level and the significance level was recorded as p<0.05.

RESULTS

In 18 months, 16 TBI patients who had undergone decompressive craniectomy were investigated. The clinical data of the patients are summarized in Table 1. The mean age of the patients was 31.18±17.51, three of them (18.8%) were woman. GCS ranged between 3 and 14 with a mean of 9.62±3.95. Mean GOS was 3.12±1.85 with a median value of 4. Craniectomy was performed to two patients (12.5%) and craniectomy and lobectomy together were performed to 14 (87.5%) of them.

The intracranial hemodynamic parameters were followed for five days, and 1st, 3rd, 5th days were evaluated. The de-

Table 1. Clinical data of the total group and decompressive surgery patients

	Total (n=52)	DC (n=16)
Traumatic subarachnoid haematoma	19	3
Contusional haematoma	11	7
Diffuse oedema	7	2
Epidural haematoma	6	1
Diffuse axonal injury	5	1
Subdural haematoma	4	2

DC: Decompressive craniectomy.

Table 2. The mean ICP measurements on days 1, 3 and 5

Days	ICP		+p	Days 1-3 **p	Days 1-5 **p	Days 3-5 **p
	Mean±SD	Median				
1	22.12±10.41	19	0.007**	0.938	0.024*	0.001**
3	22.62±7.35	22.5				
5	15.50±6.54	12				

*Friedman's Test; **Wilcoxon sign test; *p<0.05; **p<0.01. ICP: Intracranial pressure; SD: Standard deviation.

Table 3. The correlation coefficients between ICP and PI and Vmax on days 1, 3 and 5

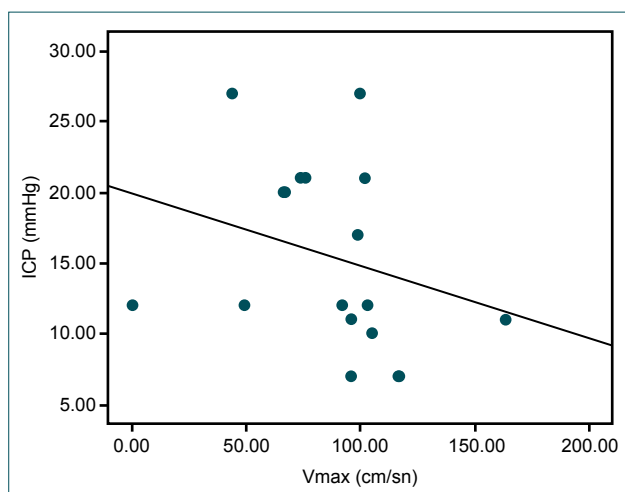
Days	ICP-PI		ICP-Vmax	
	r	p	r	p
1	0.105	0.699	-0.202	0.454
3	0.164	0.545	0.083	0.759
5	0.004	0.987	-0.520	0.039*

Spearman's rho correlation coefficient *p<0.05. ICP: Intracranial pressure; PI: Pulsatility index; Vmax: Maximum flow velocity.

cline in ICP (22.12±10.41, 22.62±7.35, 15.50±6.64) and PI (1.96±1.10, 1.64±0.75, 1.91±2.48) values were strongly significant between days 3-5, and 1-5 (p<0.001) (Table 2). The range of PI and Vmax values through five days did not present any significance (1.96±1.10, 1.64±0.75 and 1.91±0.48) and (112.50±51.12, 99.93±40.15, 86.06±36.09), respectively.

In the means of correlation, it was estimated as significant between ICP and Vmax on the fifth day (Table 3, Fig. 1).

A relationship was also observed between GCS and GOS (Spearman's correlation coefficient of 0.534, p<0.05) (Fig. 2).

**Figure 1.** Plots demonstrating the correlation between ICP and Vmax on day five. ICP: Intracranial pressure.**Table 4.** GOS evaluated in patients with DC and others

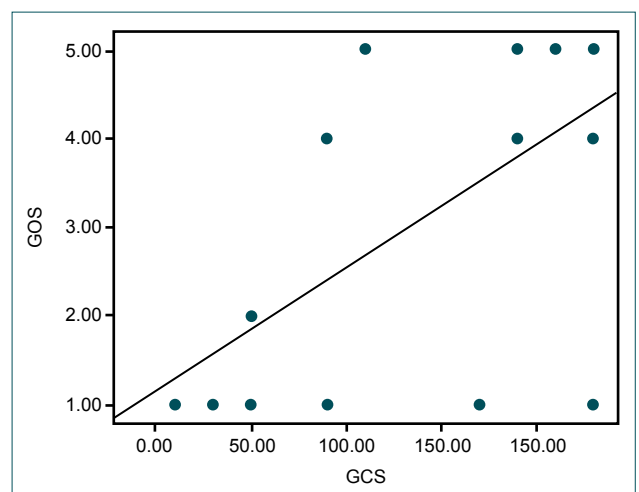
DC	GOS		*p
	Mean±SD	Median	
Yes (n=16)	3.18±1.90	4	0.227
No (n=36)	2.59±1.51	2	

*Mann-Whitney U test. GOS: Glasgow outcome score; DC: Decompressive craniectomy.

The mean GOS of the 16 patients who had DC was higher than the 36 patients who had medical therapy, but no statistical significance was observed (Table 4).

DISCUSSION

TBI is one of the most common causes of death. Marked elevation of ICP which causes cerebral ischemia and secondary insults is sometimes difficult to treat with medical managements alone. The adverse effects of intracranial hypertension are due to compression of the brain resulting with impairment in cerebral blood flow.^[6] To prevent additional brain damage due to elevated ICP, neurosurgeons perform DC which improves clinical outcome.

**Figure 2.** The correlation graphics of GCS and GOS of 16 patients. GCS: Glasgow Coma Score; GOS: Glasgow Outcome Scale.

In taking the decision to operate, the risk of complications should be weighed with the potential benefits of the procedure. Factors that should be considered in patient selection are failed conservative strategies, early intervention of surgery (before 48 hours), before the development of features of brain herniation, GCS at least 8, age <50, no primary brain stem injury, abnormal pupillary findings, ICP <40 mmHg, midline shift <1 cm.^[6]

DC is the temporary removal of a portion of the skull for the relief of intractable intracranial hypertension.^[9] High intracranial hypertension resulting from cerebral oedema, intracranial haemorrhage or space occupying hematoma may lead to secondary brain damage, herniation or death.^[9] DC may minimize the ischemic damage by increasing the cerebral blood flow and tissue oxygenation. DC decreases the mortality and improve outcome especially when performed in the early phase. However, DC is still used as a salvage procedure after all options of ICP management are exhausted. Cochrane database reveals that DC must be performed in two completely different situations as follows: prophylactic decompression or primary decompressive craniectomy and therapeutic decompression or secondary decompressive craniectomy. The former decision is taken during the surgery, independent of ICP. The latter indication is to control high ICP supported by monitoring systems.^[10] Close monitoring is the key in patients with TBI to make DC successful; however, this review concluded that there is no evidence to support the routine use of DC in TBI for refractory elevated ICP. In contrast to this, the American Brain Trauma Foundation guidelines mention bifrontal DC within 48 hours of injury as a treatment option in patients with elevated ICP.^[9]

The effects of the ICP and TCD measurements and their trends on the decision of craniectomy as a treatment option in individual cases are investigated in this study. As the presentation of ICP >20 mmHg was seen in TBI patients, and it was managed firstly with conservative treatment strategies as sedation, head up position, mannitol therapy, cerebrospinal fluid drainage, barbiturate coma. DC was handled as the last option for intractable intracranial hypertension except the ones who had surgery immediately for mass lesions. Of the 52 patients, seven contusion haematoma, three traumatic subarachnoid haematoma, one diffuse axonal injury and four epidural and subdural haematomas had DC (Table 1, Fig. 3).

Elevated ICP is an important secondary insult in TBI patients. When a direct measurement of ICP is not possible, Middle cerebral artery (MCA) evaluation with TCD has been proposed as an alternative monitoring technique.^[11-14] It has been demonstrated that waveforms obtained with TCD are affected by both increases of ICP or decreases of cerebral perfusion pressure (CPP). When ICP increases due to resistance of cerebral blood flow, diastolic flow velocity decreases, but PI increases. Diastolic velocities decrease more than systolic values which are directly correlated with PI, an

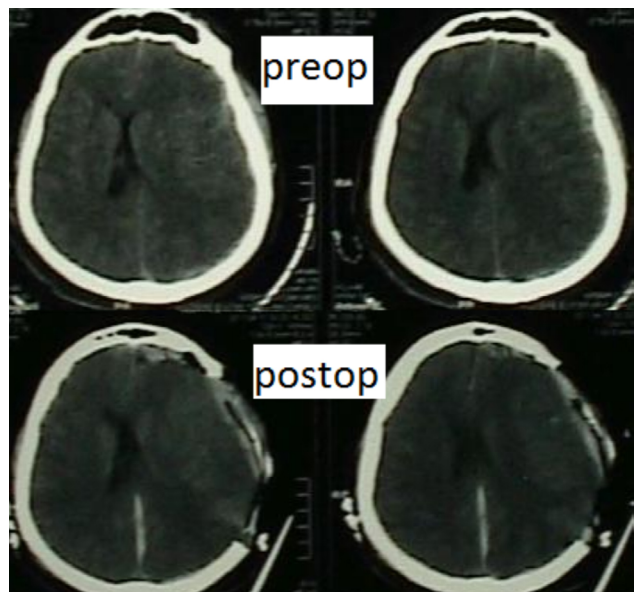


Figure 3. Preoperative and postoperative CT scans of a TBI patient.

indicator of disturbed cerebral perfusion.^[15-21] Several studies have focused on the changes in MCA flow velocity measurements after head injuries and they reinforce the use of TCD together with multimodality monitoring to understand the patterns of perfusion, oxygenation and auto regulation.^[15,22-24]

In the observational study of Bellner et al.,^[17] 81 patients with various diagnoses, including aneurismal subarachnoid haemorrhage, head injury and encephalitis, have had intraventricular catheter for ICP monitoring and multiple TCD measurements have been performed parallel to ICP recordings. Independent of the intracranial pathology, a significant correlation between PI and ICP and between flow velocity and ICP has been found. As a result of this study, PI measurements have given a good estimation of ICP in unconscious patients.

Homburg et al.^[11] have investigated 10 TBI patients and also found a positive correlation of PI and epidural pressures ($r=0.82$) and suggested that TCD may be a useful marker of ICP (9). Splavski et al.,^[25] also, have concluded that measuring the MCA blood velocity after TBI has been proven a worthy tool to estimate ICP, as well as to evaluate early post-traumatic cerebral hemodynamic.

Voulgaris et al. have inspected 37 patients with TBI. ICP monitoring and TCD examinations have been carried on subsequently during the first 48 hours. They have found that PI correlated significantly with CPP and ICP. When ICP values were below 20 mmHg, the correlation was not significant. When CPP has approached the lower auto regulatory limit, PI has started to increase rapidly. As CPP has decreased from 70 mmHg, an inverse correlation between CPP and PI has been obtained. PI has had a high predictive value for detecting low CPP and it has been a sensitive indicator for the need to monitor ICP.^[26]

Martin et al. studied on 14 TBI patients investigating the TCD measurement changes through the treatment period. Distal vascular vasospasm was diagnosed with increases of mean velocities of middle cerebral artery and PI in the early period.^[27]

The similar changes are also observed in our patients. CT and TCD parameters guided the treatment protocol. In 62.5 % of the patients, surgery is performed in the first six hours. These patients had higher CPP and lower ICP values. There was no correlation observed between ICP and PI. The mean PI and ICP values were increased in the first day and declined in the following days (Table II) Vmax of MCA was correlated well with ICP in the fifth day, that is as ICP decreased with DC, MCA flow velocities improved (Table 3, Fig. 1).

Early intervention of DC for TBI has resulted with good outcome in recently published case series. However, the term 'early' has not been defined. The 'late' group is defined as unmanageable ICP despite maximum medical treatment. It is concluded that patients presenting brain stem dysfunction upon their first neurological exam must be excluded as the procedure holds little hope for improvement from this stage.^[9]

Guerra et al. have recommended DC to be moved to the first step in case of intractable intracranial hypertension. They have compared DC to hyperventilation, barbiturate coma and hypothermia and have concluded that surgery was safer with lower mortality and fewer complications.^[28]

Akyuz et al. also state that to obtain favourable outcomes in TBI, early decision making and patient selection are important. In a group of 36 TBI patients who had early intervention of bilateral DC, declined ICP values presented a reduced mortality rate and improved outcome, especially in GCS 6–8 patients.^[29]

In properly selected patients, a systematic approach for DC instituted within the first hours of trauma, had beneficial effects in the patient population of Rubiano et al. Early application of the DC protocol within less than 12 hours from injury, GCS less than nine, Marshall CT finding between III and IV and isolated TBI resulted with significantly less mortality than the conventional approach.^[30]

Eberle et al. performed DC to 106 patients and 43 of them had DC for decompression of intracranial hypertension as a rescue therapy in cases where herniation was expected. They concluded that DC had the potential to improve both survival and functional outcome in a selected group of patients who might have a chance of an improved outcome.^[31]

Munch et al. retrospectively analyzed 49 patients with GCS ≤ 8 and age >50 and who had early decompression within 4.5 hours. Rapid surgical decompression was performed to 63.3% of the patients, craniectomy had significantly decreased

midline shift and improved visibility of mesencephalic cisterns. Alterations in ICP and CPP were not significant and no beneficial effect on patient outcome was reported.^[1,32]

In the study of Howard et al. DC was performed to 152 patients and the surgery resulted with decreases in ICP and increases in CPP values. They propose that DC must be considered as early as possible to prevent secondary brain insults.^[33]

Bilateral DC was performed to 37 patients who had malignant diffuse brain swelling after TBI. The ICP values significantly decreased after bone removal and a larger decrease were recorded after opening of the Dura mater. However, ICP was elevated after surgery but remained lower than the initial values and could be controlled with medical treatment. Of these 37 patients, 54.1% had a favourable outcome.^[34]

Patients with lower GCS have had low GOS. If a chance is used, it must be given immediately. Even though there is no significance observed, the patients who had DC had higher GOS. If it is foreseen that surgery might be performed with the algorithmic approach in the following hours or days, then it must be done early. Craniectomy is performed to 62.5% of the patients in the first six hours. The other 37.5% had higher GCS and CT findings did not demonstrate a necessity for emergent surgery (Table 4, Fig. 2).

Complications of DC develop from pathophysiological changes in ICP, cerebrospinal fluid circulation and cerebral blood flow following the removal of skull. Contusion expansion, new intracranial hematoma may develop early after DC and subdural effusion, infectious problems and posttraumatic hydrocephalus are the delayed ones.^[35,36]

Although it has been shown that higher the decompression, higher the reduction in ICP, delayed complications, such as intracranial hematoma, contra lateral subdural effusion, infection and hydrocephalus, can be observed. DC reduces mortality, improves recovery, and reduces the duration in ICU. Outcome is also correlated with the timing of DC, age >50 and GCS <8 patients.^[6]

Cerebrospinal fluid fistula in four patients, infection in two patients and osteomyelitis observed in late period in one patient were the complications seen in our study group. These complications did not affect the GOS scores. Cranioplasty is performed in 8–12 weeks to 14 patients and two of them had cranioplasty late because of infection.

In this study, TCD is used as a real-time monitor and the three steps therapy protocol was introduced step by step according to the measurements obtained. As van Santbrink et al. says, we have also concluded that an early insight in post-traumatic cerebral hemodynamic using TCD sonography is important to guide the management protocol and improve outcome.^[37] According to the results of this study, PI may

offer an insight about the post-traumatic cerebral hemodynamic, low cerebral blood flow resulting in low MCA flow velocity and high PI values.

Conclusion

Transcranial Doppler ultrasonography is a noninvasive and reliable method to determine the intracranial pressure. If the TCD demonstrates an increased intracranial pressure, decompressive craniectomy must be performed as early as possible. The need for additional medications due to elevated ICP is lesser when decompressive craniotomy is performed. Lastly, early re-implantation of the bone flap will decrease the morbidity.

Ethics Committee Approval: Approved by the local ethics committee.

Peer-review: Internally peer-reviewed.

Authorship Contributions: Concept: R.S.; Design: R.S.; Supervision: İ.E.; Materials: F.H.B.; Data: F.H.B.; Analysis: F.H.B.; Literature search: E.B.K.Ö.; Writing: R.S.; Critical revision: İ.E., M.G.Ç.

Conflict of Interest: None declared.

Financial Disclosure: The authors declared that this study has received no financial support.

REFERENCES

- Münch E, Horn P, Schürer L, Piepgras A, Paul T, Schmiedek P. Management of severe traumatic brain injury by decompressive craniectomy. *Neurosurgery* 2000;47:315–23. [CrossRef]
- Toussaint CP, Oritano TC. Decompressive Craniectomy Review of indication, outcome and implication. *Neurosurg Q* 2008;18:45–53.
- Rosengart AJ, Park SM, Segal AZ, Fink ME. Recognition and management of intracranial hypertension. *J Neurocrit Care* 2008;1:87–100.
- Mathai KI, Sudumbreakar SM, Shashivadhanan MS, Sengupta SK, Rappai TJ. Decompressive craniectomy in traumatic brain injury rationale and practice. *Indian J Neurotrauma* 2010;7:9–12. [CrossRef]
- Wani AA, Zargar J, Ramzan AU, Malik NK, Qayoom A, Kirmani AR, et al. Head injury caused by tear gas cartridge in teenage population. *Pediatr Neurosurg* 2010;46:25–28. [CrossRef]
- Eghwudjakpor P, Allison A. Decompressive craniectomy following brain injury: factors important to patient outcome. *Libyan J Med* 2010;5:4620.
- Marshall LF, Marshall SB, Klauber MR, Van Berkum Clark M, Eisenberg H, Jane JA, et al. The diagnosis of head injury requires a classification based on computed axial tomography. *J Neurotrauma* 1992;9:S287–92.
- Vincent JL, Berré J. Primer on medical management of severe brain injury. *Crit Care Med* 2005;33:1392–9. [CrossRef]
- Schirmer CM, Ackil AA Jr, Malek AM. Decompressive Craniectomy. *Neurocrit Care* 2008;8:456–70. [CrossRef]
- Sahuquillo J, Arkan F. Decompressive craniectomy for the treatment of refractory high intracranial pressure in traumatic brain injury. *Cochrane Database Syst Rev* 2006;(1):CD003983. [CrossRef]
- Homburg AM, Jakobsen M, Enevoldsen E. Transcranial Doppler recordings in raised intracranial pressure. *Acta Neurol Scand* 1993;87:488–93.
- Moreno JA, Mesalles E, Gener J, Tomasa A, Ley A, Roca J, et al. Evaluating the outcome of severe head injury with transcranial Doppler ultra-

- sonography. *Neurosurg Focus* 2000;8:e8. [CrossRef]
- Rincon F, Mayer SA. Neurocritical care: a distinct discipline?. *Curr Opin Crit Care* 2007;13:115–21. [CrossRef]
- Stocchetti N, Longhi L, Zanier ER. Intracranial pressure monitoring for traumatic brain injury: available evidence and clinical implications. *Minerva Anestesiol* 2008;74:197–203.
- Moppett IK, Mahajan RP. Transcranial Doppler ultrasonography in anaesthesia and intensive care. *Br J Anaesth* 2004;93:710–24. [CrossRef]
- Splavski B, Radanović B, Muzević D, Has B, Janculjak D, Kristek J, et al. Assessment of intra-cranial pressure after severe traumatic brain injury by transcranial Doppler ultrasonography. *Brain Inj* 2006;20:1265–70.
- Bellner J, Romner B, Reinstrup P, Kristiansson KA, Ryding E, Brandt L. Transcranial Doppler sonography pulsatility index (PI) reflects intracranial pressure (ICP). *Surg Neurol* 2004;62:45–51. [CrossRef]
- Kincaid MS, Lam AM. Monitoring and managing intracranial pressure. *Continuum Lifelong Learning in Neurology* 2006;12:93–108. [CrossRef]
- Klingelhöfer J, Conrad B, Benecke R, Sander D. Intracranial flow patterns at increasing intracranial pressure. *Klinische Wochenschrift* 1987;65:542–5. [CrossRef]
- Saqqur M, Zygun D, Demchuk A. Role of transcranial Doppler in neurocritical care. *Crit Care Med* 2007;35:S216–23. [CrossRef]
- White H, Venkatesh B. Applications of transcranial Doppler in the ICU: a review. *Intensive Care Med* 2006;32:981–94. [CrossRef]
- Czosnyka M, Smielewski P, Piechnik S, Steiner LA, Pickard JD. Cerebral autoregulation following head injury. *J Neurosurg* 2001;95:756–63.
- Sorteberg A, Sorteberg W. Transcranial doppler ultrasonography: part II: basic principles and applications in neurosurgery. *Contemporary neurosurgery* 2007;29:1–7. [CrossRef]
- Tisdall MM, Smith M. Multimodal monitoring in traumatic brain injury: current status and future directions. *Br J Anaesth* 2007;99:61–7. [CrossRef]
- Splavski B, Radanović B, Vranković D, Has B, Muzević D, Janculjak D, et al. Transcranial doppler ultrasonography as an early outcome forecaster following severe brain injury. *Br J Neurosurg* 2006;20:386–90. [CrossRef]
- Voulgaris SG, Partheni M, Kaliora H, Haftouras N, Pessach IS, Polyzoidis KS. Early cerebral monitoring using the transcranial Doppler pulsatility index in patients with severe brain trauma. *Med Sci Monit* 2005;11:CR49–52.
- Martin NA, Patwardhan RV, Alexander MJ, Africk CZ, Lee JH, Shalmon E, et al. Characterization of cerebral hemodynamic phases following severe head trauma: hypoperfusion, hyperemia, and vasospasm. *J Neurosurg* 1997;87:9–19. [CrossRef]
- Guerra WK, Gaab MR, Dietz H, Mueller JU, Piek J, Fritsch MJ. Surgical decompression for traumatic brain swelling: indications and results. *J Neurosurg* 1999;90:187–96. [CrossRef]
- Akyuz M, Ucar T, Acikbas C, Kazan S, Yilmaz M, Tuncer R. Effect of early bilateral decompressive craniectomy on outcome for severe traumatic brain injury. *Turk Neurosurg* 2010;20:382–9. [CrossRef]
- Rubiano AM, Villarreal W, Hakim EJ, Aristizabal J, Hakim F, Diez JC, et al. Early decompressive craniectomy for neurotrauma: an institutional experience. *Ulus Travma Acil Cerrahi Derg* 2009;15:28–38.
- Eberle BM, Schnüriger B, Inaba K, Gruen JP, Demetriades D, Belzberg H. Decompressive craniectomy: surgical control of traumatic intracranial hypertension may improve outcome. *Injury* 2010;41:894–8. [CrossRef]
- Rossi-Mossuti F, Fisch U, Schoettker P, Gugliotta M, Morard M, Schucht P, et al. Surgical Treatment of Severe Traumatic Brain Injury in Switzerland: Results from a Multicenter Study. *J Neurol Surg A Cent Eur Neurosurg* 2016;77:36–45. [CrossRef]
- Howard JL, Cipolle MD, Anderson M, Sabella V, Shollenberger D, Li

- PM, et al. Outcome after decompressive craniectomy for the treatment of severe traumatic brain injury. *J Trauma* 2008;65:380–6. [CrossRef]
34. Bao YH, Liang YM, Gao GY, Pan YH, Luo QZ, Jiang JY. Bilateral decompressive craniectomy for patients with malignant diffuse brain swelling after severe traumatic brain injury: a 37-case study. *J Neurotrauma* 2010;27:341–7. [CrossRef]
35. Stiver SI. Complications of decompressive craniectomy for traumatic brain injury. *Neurosurg Focus* 2009;26:E7. [CrossRef]
36. Khalili H, Sadraei N, Niakan A, Ghaffarpasand F, Sadraei A. Role of Intracranial Pressure Monitoring in Management of Patients with Severe Traumatic Brain Injury: Results of a Large Level I Trauma Center in Southern Iran. *World Neurosurg* 2016;94:120–5. [CrossRef]
37. van Santbrink H, Schouten JW, Steyerberg EW, Avezaat CJ, Maas AI. Serial transcranial Doppler measurements in traumatic brain injury with special focus on the early posttraumatic period. *Acta Neurochir (Wien)* 2002;144:1141–9. [CrossRef]

ORİJİNAL ÇALIŞMA - ÖZET

Travmatik beyin hasarında dekompresif kraniektomi: Transkraniyal Doppler ultrasonografi yol gösterici olabilir mi?

Dr. Ramazan Sarı,¹ Dr. Fatih Han Bölükbaşı,² Dr. Eylem Burcu Kahraman Özlü,¹
Dr. Nejat Işık,³ Dr. Melek Güra Çelik,⁴ Dr. İlhan Elmacı¹

¹Acıbadem Maslak Hastanesi, Beyin ve Sinir Cerrahisi Kliniği, İstanbul

²Rumeli Üniversitesi Sağlık Bilimleri Fakültesi, İstanbul

³İstanbul Medeniyet Üniversitesi, Göztepe Eğitim ve Araştırma Hastanesi, Beyin ve Sinir Cerrahisi Kliniği, İstanbul

⁴İstanbul Medeniyet Üniversitesi, Göztepe Eğitim ve Araştırma Hastanesi, Anestezi ve Reanimasyon Kliniği, İstanbul

AMAÇ: Dekompresif kraniektomi (DC), travmatik beyin hasarı (TBH) sonrası intrakraniyal hipertansiyon tedavisinde kullanılan etkin bir yöntemdir. Transkraniyal Doppler ultrasonografi (TCD) ölçümlerinin dekompresif cerrahi endikasyonundaki etkisini göstermektedir.

GEREÇ VE YÖNTEM: Çalışmaya Glasgow Koma Skoru (GCS) <9 olan 16 TBH hastası alındı. Intrakraniyal basınç (ICP) izleme ve TCD ölçümleri sürekli olarak kaydedildi. DC, ICP ve TCD kayıtlarına göre yapıldı. Glasgow Sonuç Ölçeği (GOS) skorları 3 ay sonra değerlendirildi.

BULGULAR: Hastaların yaş ortalaması 31.18±17.51, GCS 3 ile 14 arasında değişmekte olup, ortalama 9.62±3.95 idi. Ortalama GOS 3.12±1.85 idi. İki hastaya (%12.5) kraniektomi, 14 hastaya (%87.5) kraniektomi ve lobektomi birlikte yapıldı. ICP'deki düşüş (22.12±10.41, 22.62±7.35, 15.50±6.64) ve pulsatilite indeksi (PI) (1.96±1.10, 1.64±0.75, 1.91±2.48) 3–5 ve 1–5 günleri arasında belirgin olarak anlamlıydı. Beş güne kadar olan PI ve Vmax değerleri arasında anlamlı bir fark bulunmamıştır.

TARTIŞMA: TCD, gerçek zamanlı bir monitör olarak, TBH hastalarının tedavisinde cerrahi yaklaşımın erken kararına yardımcı olabilir.

Anahtar sözcükler: Dekompresif kraniektomi; nöroyoğun bakım; transkraniyal Doppler ultrasonografi; travmatik beyin hasarı.

Ulus Travma Acil Cerrahi Derg 2020;26(3):418-424 doi: 10.14744/tjtes.2020.04640