

Effects of garlic oil (*allium sativum*) on acetic acid-induced colitis in rats: Garlic oil and experimental colitis

 Yusuf Tanrikulu, M.D.,¹  Ceren Şen Tanrikulu, M.D.,²  Fahriye Kılınc, M.D.,³
 Murat Can, M.D.,⁴  Füzünan Köktürk, M.D.⁵

¹Department of General Surgery, KTO Karatay University Faculty of Medicine, Konya-Turkey

²Department of Emergency Medicine, University of Health Sciences, Konya Training and Research Hospital, Konya-Turkey

³Department of Pathology, Necmettin Erbakan University Meram Faculty of Medicine, Konya-Turkey

⁴Department of Biochemistry, Bülent Ecevit University Faculty of Medicine, Zonguldak-Turkey

⁵Department of Biostatistics, Bülent Ecevit University Faculty of Medicine, Zonguldak-Turkey

ABSTRACT

BACKGROUND: Inflammatory bowel disease (IBD) is an important health problem. The most important hypotheses for the pathogenesis of this disease are the deterioration of immune responses and loss of tolerance against bacteria in the enteric flora. Although IBD has been widely investigated, its treatment remains difficult. This study aims to investigate the effects of garlic oil (GO) on an experimental colitis model.

METHODS: Twenty-eight rats were randomly divided into four equal groups as follows: group 1 (sham), group 2 (control), group 3 (topical treatment) and group 4 (topical and systemic treatment). An acetic acid-induced colitis model was produced in groups 2, 3 and 4 and was administered normal saline, topical GO and topical and systemic GO, respectively.

RESULTS: Hydroxyproline levels were lower in the treatment groups than in the control group. TNF- α levels were significantly lower in group 3 than in group 2. Macroscopic scores were significantly lower in group 4 than in group 2. Significant differences were observed between the treatment and control groups according to their epithelial loss.

CONCLUSION: GO can reduce colonic damage and inflammation in the acetic acid-induced colitis model, with effects on both local and systemic treatments, but with a more pronounced effect in local treatment.

Keywords: Acetic acid; colitis; diallyl sulphide; garlic oil; inflammatory bowel disease; TNF- α .

INTRODUCTION

Inflammatory bowel disease (IBD), mainly includes ulcerative colitis (UC) and Crohn's disease (CD), is an inflammatory disease primarily involving the gastrointestinal tract. While various infectious agents, allergens, nutrition habits, psychosomatic factors and immune responses to auto-antigens take part in the etiology of IBD, changes in the balance of mucosal protective factors and excessive bacterial proliferation, as well as changes in cytokine and mediator synthesis, can be responsible for the pathogenesis of this disease.^[1-3] The most important hypotheses for the pathogenesis of IBD are both

deterioration of immune reactions and lack of tolerance to bacteria in the enteric flora.

The fundamental changes seen in the immune reaction are an increase in macrophage counts and activation of dendritic cells in the lamina propria, which causes nuclear factor κ B (NF κ B) stimulation, and proinflammatory cytokines (interleukin (IL)-1 β , tumour necrosis factor (TNF)- α , IL-6 and IL-8) production, as well as increased expression of adhesion molecules.^[4,5] Therefore, the development of colitis can be reduced with many experimental agents, which cause changes in the immune response as well as the release of inflammatory molecules.

Cite this article as: Tanrikulu Y, Şen Tanrikulu C, Kılınc F, Can M, Köktürk F. Effects of garlic oil (*allium sativum*) on acetic acid-induced colitis in rats: Garlic oil and experimental colitis. *Ulus Travma Acil Cerrahi Derg* 2020;26:503-508.

Address for correspondence: Yusuf Tanrikulu, M.D.

KTO Karatay Üniversitesi Tıp Fakültesi, Genel Cerrahi Anabilim Dalı, Konya, Turkey

Tel: +90 332 - 221 80 80 E-mail: drtanrikulu@hotmail.com



Ulus Travma Acil Cerrahi Derg 2020;26(4):503-508 DOI: 10.14744/tjtes.2019.01284 Submitted: 13.06.2019 Accepted: 05.11.2019 Online: 15.06.2020

Copyright 2020 Turkish Association of Trauma and Emergency Surgery

Hydroxyproline is an important constituent of the major structural protein and plays a key role in the synthesis and stability of the collagen. A normal and stable cellular structure of the extracellular matrix is a sign of a complete wound healing process after a tissue injury. Increased hydroxyproline content in granulation tissue is the indicator of increased collagen turnover, which indicates better maturation and proliferation of collagen during wound healing. Therefore, IBD shows both acute and chronic wound healing, measurement of tissue hydroxyproline levels contributes to revealing wound healing.^[6]

Garlic oil (GO) is beneficial to human health and contains effective natural organosulfur compounds, such as allicin, allium, diallyl sulphide (DAS) and diallyl trisulphide (DATS).^[7] Because GO has a broad diversity of pharmacological properties including anticancer, antibacterial, anti-inflammatory, fibrinolytic, wound-healing, antioxidant and anti-adhesive, it has been used in many different areas of clinical medicine.^[8,9] Studies have shown that purified garlic compounds inhibit NF κ B activation and TNF- α production.^[10] Another study found that DAS inhibits both pro- and anti-inflammatory cytokines, including TNF- α , IL-1 β , IL-6 and IL-10, in LPS (lipopolysaccharide)-stimulated RAW264.7 macrophages.^[11] In this study, we presented the effects of GO on cellular damage and inflammation in an acetic acid-induced colitis rat model.

MATERIALS AND METHODS

Study Design

Twenty-eight female adult Wistar–Albino rats, weighing 260 \pm 20 g, were enclosed at room temperature (22 $^{\circ}$ C \pm 1 $^{\circ}$ C) with 12 h:12 h light/dark cycle and fed a standard diet and water. Diet and water were stopped 12 h and 2 h, respectively, before inducing anaesthesia. No antibiotics were administered during the experiment. The experimental protocol was accepted by the Animal Ethics Committee of Bülent Ecevit University (Date/Number: 2014/13b).

Induction of the colitis model

The rats were anaesthetised with intramuscular ketamine (50 mg/kg) and xylazine (6 mg/kg). After inducing anaesthesia, 1 mL of (5%) acetic acid (AA) was instilled using a soft 6-Fr paediatric catheter inserted into the anus up to 6–8 cm. Eventually, after 15–20 seconds of exposure, the fluid was withdrawn. Before the withdrawal of the catheter, 2 mL of air was applied to distribute AA into the colon. In the treatment groups, the GO was administered one hour after induction. This experimental model has been shown to have similar histopathological features in human colitis.^[12]

Experimental Groups

Twenty-eight rats were randomly divided into four equal groups. The colitis model was produced in all groups except the sham group.

Group 1 (Sham): After each rat was rectally administered saline, 1 mL of saline was intraperitoneally applied.

Group 2 (Control): After the colitis model was produced, 1 mL of saline was intrarectally applied. No treatment was administered.

Group 3 (Topical treatment): One hour after the colitis model was produced, 5 mL/kg of GO (Oleum Allii Sativi[®], Arifoglu, Avcilar, İstanbul) was rectally applied. The rats were incubated for 10 min in a Trendelenburg position to provide sufficient mucosal contact with the drug. Subsequently, 1 mL of saline was intraperitoneally administered.

Group 4 (Topical + systemic treatment): One hour after the colitis model was produced, 5 mL/kg of GO was rectally administered. The rats were kept in Trendelenburg position for 10 minutes to ensure adequate drug-mucosal interaction. Subsequently, 5 mL/kg of GO was intraperitoneally applied as a single daily dose for 10 days.

On the tenth day, the abdomen and thorax were opened by a midline incision under anesthesia. Blood samples were taken by cardiac puncture method for biochemical analysis and rats were sacrificed by the same method. Later, the distal 8 cm of the colon was extracted for histopathological evaluation.

Histopathological Examination

After cleaning the mucosa with saline, the mucosal injury was macroscopically evaluated using the grading scale of Morris et al.^[13] (Table 1). A single well-experienced pathologist, who was also blind for the study design, examined each specimen. For this examination, 8 cm distal colon samples were obtained. The colon samples were fixed using 10% formaldehyde, and 4- μ m-thick tissue samples in paraffin blocks were obtained and stained with haematoxylin and eosin (H&E) and then analysed under a light microscope (Olympus BX53, Tokyo, Japan). The degree of inflammation of the colon was semiquantitatively graded from 0 to 11, according to the criteria defined by Özgün et al.^[14] (Table 2).

Table 1. Variables used for macroscopic evaluation^[13]

Score	Macroscopic variable
0	No damage
1	Localized hyperemia, but no ulcers
2	Linear ulcers with no significant inflammation
3	Linear ulcer with inflammation at one site
4	Two or more sites of ulceration and/or inflammation
5	Two or more major sites of inflammation and ulceration or one more site of inflammation and ulceration extending >1 cm along the length of the colon

Table 2. Variables used in the classification of the inflammatory histological score^[14]

Score	Epithelial loss	Inflammatory infiltrate	Integrity of crypts	Stress to goblet cells
0	None	None	Intact	Absent
1	<5%	Mild	<10%	Present
2	5–10%	Moderate	10–20%	N/A
3	>10%	Severe	>20%	N/A

Table 3. Comparison of groups according to biochemical results

Groups	Hydroxyproline	TNF- α
	Mean \pm SD	Mean \pm SD
Grup 1 (Sham)	3.55 \pm 0.48	26.93 \pm 6.35
Grup 2 (Control)	4.98 \pm 0.59	60.82 \pm 26.05
Grup 3 (Topical treatment)	2.95 \pm 0.70 ^x	45.99 \pm 8.97 ^a
Grup 4 (Topical+ systemic treatment)	3.17 \pm 1.11 ^y	50.16 \pm 24.33

TNF- α : Tumor necrosis factor alpha; SD: Standard deviation.

^xp=0.002, ^yp=0.015, and ^ap=0.008 vs. control groups.

Biochemical Analysis

Blood

Blood was collected into tubes at the time of death. Blood samples were centrifuged at 1000 g for 10 minutes at 4°C to remove plasma. Aliquots of the samples were transferred into polyethylene tubes to be used in the assay of biochemical parameters and were stored at -80°C until analysis. TNF- α levels were measured in the serum using a rat TNF alpha ELISA kit (Eastbiopharm, Hangzhou) on fully automatic devices.

Tissue

All tissues were washed twice with cold saline solution, placed into glass bottles, labeled, and stored in a deep freezer (-80°C) until processing. Colon tissues were homogenized in 10 volumes of 150 mM ice-cold KCL using a glass Teflon Homogenizer (Ultra Turrax IKA T18 Basic; IKA, Wilmington, NC, USA) after cutting the tissues into small pieces with scissors (for two minutes at 5000 rpm). The homogenate was then centrifuged 5000 g for 15 minutes. The supernatant was used for analysis. Later, spectrophotometry was used to detect tissue hydroxyproline concentrations, and the results were denoted as micrograms per milligram of tissue.^[15] First, the samples, standards, and streptavidin-HRP were added to the well. The antibodies were labeled with an enzyme, and the plate was incubated for 60 minutes at 37°C. The plate was washed five times, and chromogen solutions were added. The plate was incubated for 10 minutes at 37°C, and the stop solution was added into the wells. The optical density

(OD) was measured under 450 nm wavelengths with a microplate reader. According to standards concentration, the corresponding OD values were calculated using the standard curve linear regression equation to calculate the corresponding sample's concentration.

Statistical Analysis

Results were analysed using the SPSS (Statistical Package for Social Science) for Windows 19.0 package programme. The normality of the data was determined using the one-sample Kolmogorov–Smirnov test. Continuous variables were analysed using the Kruskal–Wallis variance analysis. While continuous variables were expressed as mean \pm standard error, non-continuous variables were expressed as the median (min–max). The chi-square test was used to compare non-continuous variables. A P-value of <0.05 was considered to be a statistically significant difference for all tests.

RESULTS

Hydroxyproline and TNF- α results of all groups are summarised in Table 3. Hydroxyproline levels in the treatment groups were significantly lower than the control group (p=0.002, group 3; p=0.015, group 4). There was no difference in the TNF- α levels between groups 2 and 4; however, they were significantly lower in group 3 than TNF- α levels in the control group (p=0.008).

The distribution of the histopathological results is summarised in Table 4 and is shown in Fig. 1. The method described by Morris et al.^[13] was used to assess macroscopic damage in the colon samples. The results of the macroscopic scores in group 4 were significantly lower than those in the control group (p=0.015). Microscopic damage was also evaluated according to criteria defined by Özgün et al.^[14] The sham group had histopathological findings similar to the normal colonic mucosa. There was a significant difference between the treatment groups and the control group as it relates to epithelial loss (p=0.001, group 3; p=0.021, group 4). There was no difference between the groups in terms of inflammatory infiltrate, the integrity of crypts and stress to goblet cells. The total damage score was significantly lower in the treatment groups compared to the control group (p=0.001).

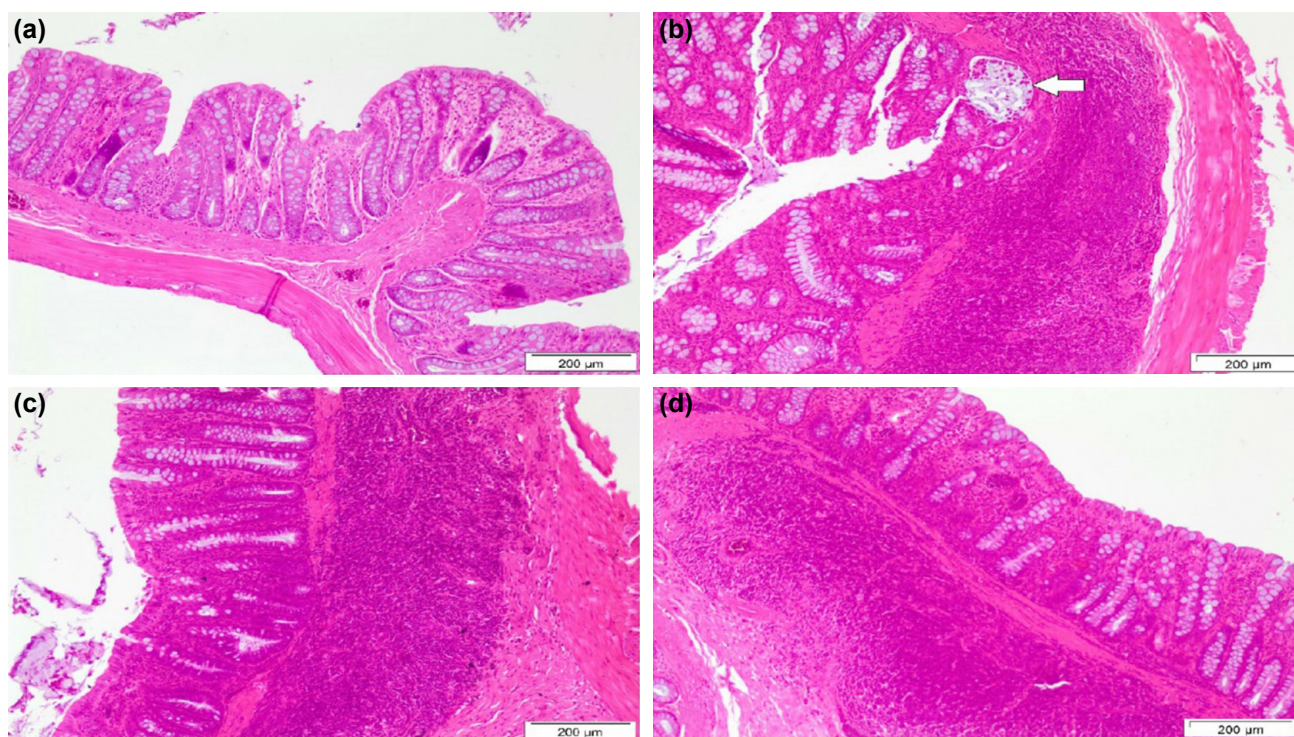


Figure 1. In the sham group: the mucosal surface epithelium and crypts in the colon wall are regular structures and a large number of goblet cells are observed. The stromal structure between the crypts is thin and few mononuclear cells are observed (a). In the control group: in the surface and crypt epithelium, there is a decrease in goblet cells, irregularity in crypts, and expansion between crypts and stroma in the submucosa. Inflammatory mixed cells infiltrating the epithelium and crypt abscess (arrow) in one focus are seen (b). In the local treatment group: there is a mild irregularity in the crypts, with a decrease and a slight increase in the stroma between them, a decrease in the goblet cells in the surface epithelium and fewer crypts, inflammatory cell infiltration in the lamina propria and submucosa (c). In the systemic treatment group: there is a slight decrease in goblet cells, a slight decrease in crypts, irregularity in crypts and mild enlargement of the stroma between them. Mixed inflammatory cells in the lamina propria and submucosa are observed (d) (Hematoxylin-eosin, x100).

DISCUSSION

The present study indicates that systemic and local administration of GO reduces the inflammation and cellular damage in an AA-induced colitis model.

IBDs, including UC and CD, are inflammatory diseases that primarily affect the gastrointestinal tract. The etiopathogenesis of the disease is multifactorial. While various infectious agents, allergens, nutrition habits, psychosomatic factors and immune response to auto-antigens take part in the etiology of IBDs, changes in the balance of mucosal protective factors and excessive bacterial proliferation as well as changes in cytokine and mediator synthesis can be responsible for the pathogenesis of the disease.^[1-3] The most important hypotheses for the pathogenesis of the disease are both deterioration of immune reactions and lack of tolerance against bacteria in the enteric flora. This inappropriate inflammatory response disrupts micro-vascular structures, increases vascular permeability and destroys the intestinal epithelial barrier. Because endothelial cells are the main cells of microvascular structures, cellular damage becomes inevitable.^[16,17]

Many proinflammatory cytokines are upregulated in IBD, of which TNF- α and IL-1 are the most important. TNF- α is the

main mediator of intestinal inflammation. It is synthesised by many inflammatory cells and activates many genes in the NF κ B pathway. Other important mechanisms accused in the pathogenesis of IBD include oxidative stress and reactive oxygen products. Reactive oxygen products that are formed due to oxidative stress cause mucosal damage along with proinflammatory mediators. Therefore, the effects of various antioxidant and anti-inflammatory agents have been the subject of research in IBD.^[18,19]

Garlic has been used in many fields of medicine for centuries. The part of the garlic that is responsible for its biological activity is the active organosulphuric compounds, which include allicin, alliin, DAS and DATS. Many studies have shown that garlic compounds have antioxidant, antimicrobial, antimutagenic and anticancer properties.^[20,21] Ho et al.^[21] found that DAS reduces TNF- α in rat aortic smooth muscles and suggested that DAS could prevent oxidative stress in inflammation. Furthermore, immunohistochemical studies have indicated that DAS reduces inflammatory biomarkers, such as TNF- α and IL-1 β , by affecting inducible nitric oxide synthase (iNOS) and activating NF κ B.^[21,23] Another study demonstrated that allicin inhibits NF κ B activation as well as TNF- α and iNOS production.^[10] Likewise, it was shown that DAS

inhibits both pro- and anti-inflammatory cytokines in LPS-stimulated macrophages.^[11]

Very few studies that investigate the effects of garlic on intestinal diseases are available in the literature. Balaha et al.^[24] showed that GO reduces inflammation in the UC model. Blackler et al.,^[25] in their studies investigating the protective effects of hydrogen sulphide on encephalopathy associated with naproxen, found that the co-administration of DAS reduced naproxen-induced intestinal injury and inflammation. In another study, Voltes et al.^[26] found that topically applied hydrocortisone, pectin/alginate and olive oil combination may be effective against inflammatory infiltration in the colitis model. In our study, we found that TNF- α levels in the topical treatment group were lower than those in the control group ($p=0.008$). Although TNF- α levels were also lower in systemic + topical treatment, the results were not significant.

Hydroxyproline is an important constituent of the major structural protein and plays a key role in the synthesis and stability of the collagen. Hydroxyproline is an important indicator of collagen accumulation. Deficiency of protein during wound healing may diminish new capillary development, fibroblast proliferation, collagen and proteoglycans synthesis and remodeling and contraction of the wound. A normal and stable cellular structure of the extracellular matrix is a sign of a complete wound healing process after a tissue injury. Breakdown of collagen releases free hydroxyproline and its peptides. Thus, hydroxyproline as a biochemical marker during wound healing is extensively used to evaluate the tissue collagen content and as an indicator for collagen turnover after wound-healing. Increased hydroxyproline content in granulation tissue is the indicator of increased collagen turnover, which indicates better maturation and proliferation of collagen during wound healing. There are numerous reasons to support the use of hydroxyproline as a biomarker of the collagen content within tissues after the wound-healing process as it is abundantly found in collagen and plays a vital role in wound healing.^[6] Sadar et al.^[27] found that increased hydroxyproline levels significantly correlated with accumulated collagen in the colonic tissue after trinitrobenzene sulfonic acid (TNBS) administration, whereas ferulic acid treatment significantly reduced colonic hydroxyproline activity. Motawi et al.^[28] also found similar results. In our study, we found that hydroxyproline levels were significantly higher in the control group and significantly lower in the treatment groups, which was in accordance with the literature ($p=0.002$, topical treatment group; $p=0.015$, topical + systemic treatment group).

Macroscopic and histopathological examinations are the gold standard for evaluating inflammation in the colon. Appleyard and Wallace^[29] found that total histopathological damage score was higher in the colitis group compared to the saline group in the original colitis studies in which they underwent histopathological evaluation. Balaha et al.^[24] found that GO ameliorated the marked macroscopic and microscopic

changes of colonic mucosa in a dose-dependent manner. In our study, we found that the total damage score was significantly lower in the treatment groups compared to the control group ($p=0.001$).

Conclusion

In conclusion, GO able to inhibit AA-induced colitis in rats, maybe through its anti-inflammatory and immunomodulatory properties. This effect is seen in both local and systemic treatments; however, the effect is more pronounced in local treatment. Moreover, further investigations are currently in progress to determine the precise underlying protective mechanism of GO on AA-induced colitis. Therefore, GO can be used both to reduce cellular damage and disease severity during the exacerbation period and to be recommended as a protective agent recommended for UC patients.

Acknowledgements

We would like to thank the employees of the operating room and the Department of Pathology.

Ethics Committee Approval: The Ethics Committee approval for this study was received from the Ethics Committee of Bülent Ecevit University Faculty of Medicine.

Peer-review: Internally peer-reviewed.

Authorship Contributions: Concept: Y.T.; Design: Y.T., C.Ş.T.; Supervision: Y.T., C.Ş.T.; Fundings: Y.T.; Materials: Y.T., C.Ş.T., Fah.K., M.C., Für.K; Data: Y.T., C.Ş.T.; Analysis: Y.T.; Literature search: Y.T.; Writing: Y.T.; Critical revision: Y.T.

Conflict of Interest: None declared.

Financial Disclosure: The authors declared that this study has received no financial support.

REFERENCES

1. Safarpour AR, Hosseini SV, Mehrabani D. Epidemiology of inflammatory bowel diseases in iran and Asia; a mini review. *Iran J Med Sci* 2013;38:140–9.
2. Daneshmand A, Mohammadi H, Rahimian R, Habibollahi P, Fakhfour G, Talab SS, et al. Chronic lithium administration ameliorates 2,4,6-trinitrobenzene sulfonic acid-induced colitis in rats; potential role for adenosine triphosphate sensitive potassium channels. *J Gastroenterol Hepatol* 2011;26:1174–81. [CrossRef]
3. Nagib MM, Tadros MG, ElSayed MI, Khalifa AE. Anti-inflammatory and anti-oxidant activities of olmesartan medoxomil ameliorate experimental colitis in rats. *Toxicol Appl Pharmacol* 2013;271:106–13. [CrossRef]
4. Sartor RB, Hoentjen F. Proinflammatory cytokines and signaling pathways in intestinal innate immune cells. In: *Mucosal Immunology*. Mestecky J, Lamm ME, Ogra P, Strober W, Bienenstock J, McGhee JR, et al, editors. 3rd edition. Elsevier Inc 2005.p.681–701. [CrossRef]
5. Fuss IJ, Neurath M, Boirivant M, Klein JS, de la Motte C, Strong SA, et al. Disparate CD4+ lamina propria (LP) lymphokine secretion profiles in inflammatory bowel disease. Crohn's disease LP cells manifest increased secretion of IFN-gamma, whereas ulcerative colitis LP cells manifest increased secretion of IL-5. *J Immunol* 1996;157:1261–70. [CrossRef]
6. Yun HM, Ban JO, Park KR, Lee CK, Jeong HS, Han SB, et al. Potential therapeutic effects of functionally active compounds isolated from garlic.

- Pharmacol Ther 2014;142:183–95. [CrossRef]
7. Srivastava AK, Khare P, Nagar HK, Raghuvanshi N, Srivastava R. Hydroxyproline: A Potential Biochemical Marker and Its Role in the Pathogenesis of Different Diseases. *Curr Protein Pept Sci* 2016;17:596–602.
 8. Sakthivel KM, Guruvayoorappan C. Amentoflavone inhibits iNOS, COX-2 expression and modulates cytokine profile, NF- κ B signal transduction pathways in rats with ulcerative colitis. *Int Immunopharmacol* 2013;17:907–16. [CrossRef]
 9. Bradley PP, Priebe DA, Christensen RD, Rothstein G. Measurement of cutaneous inflammation: estimation of neutrophil content with an enzyme marker. *J Invest Dermatol* 1982;78:206–9. [CrossRef]
 10. Bruck R, Aeed H, Brazovsky E, Noor T, Hershkoviz R. Allicin, the active component of garlic, prevents immune-mediated, concanavalin A-induced hepatic injury in mice. *Liver Int* 2005;25:613–21. [CrossRef]
 11. Chang HP, Huang SY, Chen YH. Modulation of cytokine secretion by garlic oil derivatives is associated with suppressed nitric oxide production in stimulated macrophages. *J Agric Food Chem* 2005;53:2530–4. [CrossRef]
 12. Randhawa PK, Singh K, Singh N, Jaggi AS. A review on chemical-induced inflammatory bowel disease models in rodents. *Korean J Physiol Pharmacol* 2014;18:279–88. [CrossRef]
 13. Morris GP, Beck PL, Herridge MS, Depew WT, Szwedczuk MR, Wallace JL. Hapten-induced model of chronic inflammation and ulceration in the rat colon. *Gastroenterology* 1989;96:795–803. [CrossRef]
 14. Özgün E, Sayılan Özgün G, Eskiocak S, Yalçın Ö, Süer Gökmen S. Effect of L-carnitine on serum paraoxonase, arylesterase and lactonase activities and oxidative status in experimental colitis. *Turk J Biochem* 2013;38:145–53. [CrossRef]
 15. Bergman R, Loxley R. Two improved and simplified methods for the spectrophotometric determination of OH-proline. *Anal Chem* 1963;35:1961–5. [CrossRef]
 16. Podolsky DK. Inflammatory bowel disease. *N Engl J Med* 2002;347:417–29. [CrossRef]
 17. Xavier RJ, Podolsky DK. Unravelling the pathogenesis of inflammatory bowel disease. *Nature* 2007;448:427–34. [CrossRef]
 18. Mayer B, Brunner F, Schmidt K. Inhibition of nitric oxide synthesis by methylene blue. *Biochem Pharmacol* 1993;45:367–74. [CrossRef]
 19. Kalaycı MU, Eroğlu HE, Kubilay D, Soylu A, Sancak B, Uğurluoğlu C, et al. The effects of methylene blue on adhesion formation in a rat model of experimental peritonitis. *Ulus Travma Acil Cerrahi Derg* 2011;17:205–9. [CrossRef]
 20. Hall A, Troupin A, Londono-Renteria B, Colpitts TM. Garlic Organosulfur Compounds Reduce Inflammation and Oxidative Stress during Dengue Virus Infection. *Viruses* 2017;9:159. [CrossRef]
 21. Ho CY, Weng CJ, Jhang JJ, Cheng YT, Huang SM, Yen GC. Diallyl sulfide as a potential dietary agent to reduce TNF- α - and histamine-induced proinflammatory responses in A7r5 cells. *Mol Nutr Food Res* 2014;58:1069–78. [CrossRef]
 22. Suman S, Shukla Y. Diallyl Sulfide and Its Role in Chronic Diseases Prevention. *Adv Exp Med Biol* 2016;929:127–44. [CrossRef]
 23. Kalayarasan S, Sriram N, Sudhandiran G. Diallyl sulfide attenuates bleomycin-induced pulmonary fibrosis: critical role of iNOS, NF- κ pB, TNF- α and IL-1 β . *Life Sci* 2008;82:1142–53. [CrossRef]
 24. Balaha M, Kandeel S, Elwan W. Garlic oil inhibits dextran sodium sulfate-induced ulcerative colitis in rats. *Life Sci* 2016;146:40–51. [CrossRef]
 25. Blackler RW, Motta JP, Manko A, Workentine M, Bercik P, Surette MG, et al. Hydrogen sulphide protects against NSAID-enteropathy through modulation of bile and the microbiota. *Br J Pharmacol* 2015;172:992–1004. [CrossRef]
 26. Voltas A, Bermúdez A, Rodríguez-Gutiérrez G, Reyes ML, Olano C, Fernández-Bolaños J, et al. Anti-Inflammatory Local Effect of Hydroxytyrosol Combined with Pectin-Alginate and Olive Oil on Trinitrobenzene Sulfonic Acid-Induced Colitis in Wistar Rats. *J Invest Surg* 2020;33:8–14. [CrossRef]
 27. Sadar SS, Vyawahare NS, Bodhankar SL. Ferulic acid ameliorates TNBS-induced ulcerative colitis through modulation of cytokines, oxidative stress, iNOS, COX-2, and apoptosis in laboratory rats. *EXCLI J* 2016;15:482–99.
 28. Motawi TK, Rizk SM, Shehata AH. Effects of curcumin and Ginkgo biloba on matrix metalloproteinases gene expression and other biomarkers of inflammatory bowel disease. *J Physiol Biochem* 2012;68:529–39.
 29. Appleyard CB, Wallace JL. Reactivation of hapten-induced colitis and its prevention by anti-inflammatory drugs. *Am J Physiol* 1995;269:G119–25.

DENEYSSEL ÇALIŞMA - ÖZET

Şıçanlarda asetik asitle indüklenen kolit üzerine sarımsak yağının etkileri: Sarımsak yağı ve deneysel kolit

Dr. Yusuf Tanrikulu,¹ Dr. Ceren Şen Tanrikulu,² Dr. Fahriye Kılıncı,³ Dr. Murat Can,⁴ Dr. Füzün Köktürk⁵

¹KTO Karatay Üniversitesi Tıp Fakültesi, Genel Cerrahi Anabilim Dalı, Konya

²Sağlık Bilimleri Üniversitesi, Konya Eğitim ve Araştırma Hastanesi, Acil Tıp Kliniği, Konya

³Necmettin Erbakan Üniversitesi Meram Tıp Fakültesi, Patoloji Anabilim Dalı, Konya

⁴Bülent Ecevit Üniversitesi Tıp Fakültesi, Biyokimya Anabilim Dalı, Zonguldak

⁵Bülent Ecevit Üniversitesi Tıp Fakültesi, Biyoistatistik Anabilim Dalı, Zonguldak

AMAÇ: Enflamatuvar bağırsak hastalığı (EBD) önemli bir sağlık sorunudur. Hastalığın patogenezinde ileri sürülen en önemli hipotezler bağırsak florasındaki bakterilere karşı tolerans kaybı ve immün yanıtın bozulmasıdır. Çok geniş araştırmalara rağmen, EBD'nin tedavisi hala zordur. Bu çalışmada deneysel kolit modelinde sarımsak yağının (GO) etkilerinin araştırılması amaçlandı.

GEREÇ VE YÖNTEM: Yirmi sekiz şıçan rastgele dört eşit gruba ayrıldı; grup 1 (sham), grup 2 (kontrol), grup 3 (topikal tedavi grubu) ve grup 4 (topikal ve sistemik tedavi grubu). Grup 2, 3 ve 4'te asetik asitle indüklenen kolit modeli oluşturuldu. Grup 2'ye salin, grup 3'e topikal GO ve grup 4'e topikal ve sistemik GO verildi.

BULGULAR: Hidroksiprolin seviyeleri tedavi gruplarında kontrol grubundan daha düşüktü. Grup 3'teki TNF- α seviyeleri kontrol grubuna göre anlamlı olarak düşüktü. Makroskopik skorları grup 4'te kontrol grubundan anlamlı olarak düşüktü. Tedavi grupları ve kontrol grubu arasında epitelyal kayba göre anlamlı fark gözlemlendi.

TARTIŞMA: Sarımsak yağı asetik aside bağlı kolit modelinde kolonik hasarı ve enflamasyonu azaltır. Bu etki, topikal uygulamada daha belirgin olmakla birlikte hem topikal hem de sistemik uygulamada ortaya çıkmaktadır.

Anahtar sözcükler: Asetik asit; dialil sülfid; enflamatuvar bağırsak hastalığı; kolit; sarımsak yağı; TNF- α .

Ulus Travma Acil Cerrahi Derg 2020;26(4):503-508 doi: 10.14744/tjtes.2019.01284