

## CLOSED DEGLOVING INJURY COMPLICATED WITH PARAPLEGIA

## PARAPLEJİ İLE BİRLİKTE OLAN KAPALI SIYRILMA (DEGLOVING) YARALANMASI

Dr. Kaya YORGANCI\*, Dr. Mesut ATLI\*\*, Dr. Aycan KAYIKÇI\*, Dr. Volkan KAYNAROĞLU\*

## ÖZET

Sıyrılma yaralanmaları acil servislerde sık görülen bir yaralanma türüdür. Ancak kapalı sıyrılma yaralanmaları nadir görülür ve kolaylıkla gözden kaçabilir. Bu olgu sunumunda 47 yaşında bir erkek hastada travmatik parapleji ile birlikte görülen bir kapalı sıyrılma yaralanması sunulmaktadır. Hastanın seyri, yaralanma mekanizmasının farklılığı, yandaş yaralanmaların olması, vertebra kırığına yönelik cerrahi girişim ile birlikte sıyrılma yaralanmasına uygulanan konservatif cerrahi girişim ile komplike bir hal aldı. Kapalı sıyrılma yaralanması ve bu yaralanmanın olası komplike seyri, travma hastaları ile sık karşılaşan cerrahların farkında olması gereken bir patolojidir.

**Anahtar kelimeler :** Sıyrılma yaralanması, travma, parapleji, yaralanma mekanizması, vertebra kırığı

## INTRODUCTION

Degloving injury defined as the traumatic separation of the skin and subcutaneous tissue from the underlying fascia after a sudden, severe shearing force. Usually skin surface is not intact and there is an open wound. Open degloving injuries are easily recognized and managed. However closed degloving injuries are infrequently encountered and rarely complicated. There are only a few reports in the English literature regarding this type of injury [1-3]. We herein report a massive closed degloving injury complicated by traumatic paraplegia. To our knowledge this is the first seriously complicated closed degloving injury in the literature.

## CASE REPORT

In the winter, a 47-year-old man was admitted to the emergency room one hour later of a motor vehicle accident. The victim was rushed out from the rear window of the automobile and dragged on the iced and sharp stony surface for about one hundred meters on his buttocks (Figure 1). He was taken to our hospital by ambulance.

On admission, his vital signs were normal. He was complaining of severe back pain and inability to move his lower extremities. On physical examination, touch and pinprick sensations, deep tendon reflexes were absent in his both lower extremities. A small laceration close to anus was found and the sphincter tonus was absent. The anterior-posterior lumbar film showed widening of L2 interpedicular distance, and lateral lumbar film showed a decrease of vertebral height of L2. Vertebral computerized tomography revealed a burst fracture of the second lumbar vertebra with middle column destruction. While evaluating the patient for a need of colostomy, a massive, soft, fluctuant area was found within the entire sacrum expanding over the buttocks and lumbar region. A massive closed degloving injury covering one third of the back (

18% total body surface area) was diagnosed and a diverting colostomy seemed necessary.

The patient was admitted to the operating room for an emergency surgery. After positioning the patient with knee-chest frame, interbody fusion through the posterolateral root was performed with an iliac bone graft. Orthopedic procedure was completed with posterior fixation with pedicle screws and rods. With the same position, several small incisions were made over the degloved area, approximately 20-cm aside, for irrigation and drainage. The patient was re-positioned and a sigmoid loop colostomy was performed through a small laparotomy incision.

The patient was observed for 18 days, postoperatively. The wound cavity was daily irrigated with normal saline and closed with soft cotton dressings. However, no healing of the degloved area was observed in this period. Degloved skin was floating, and there was an increase in sero-purulent wound discharge. Cultures taken from the wound grew *Pseudomonas aeruginosa*. In a second operation, the degloved area was opened widely and the necrotic subcutaneous tissue was debrided. The open wound was closed using a rotation flap of lateral buttock skin, tensor fasciae latae myocutaneous flap and a small skin graft. The patient had twelve days of uneventful course and was discharged. One year later, the patient remained paraplegic.

## DISCUSSION

Closed degloving injuries are very rarely seen and mostly related to lower extremities, lower back and buttocks. This injury may occur following either domestic or traffic accidents [4-7]. Although the introduction of automatic appliances like washing machines- has led to a decrease in the frequency of domestic injuries, traffic accidents may still cause this type of injury [2]. The mecha-

nism of injury usually occurs as a result of entrapment between the tyre of a motor vehicle and a fixed surface [2]. In our case, the shearing force was dragging on the iced and sharp stony surface for a long distance. This type of injury was not reported previously and may be considered as a new type of mechanism that cause closed degloving injury.

The diagnosis of the closed degloving injury was mainly based on a careful physical examination. Unlike open injuries, closed ones may be easily missed, because the overlying skin may seem entirely normal and the focus of both the surgeon and the patient may be on other severe or external injuries. Hudson et al. initially diagnosed only one third of the injuries [2]. Local contusion, loss of sensation, tyre marks, friction burns and the skin hypermobility over the injured are useful clues [1]. The hallmark of the diagnosis is the presence of a soft fluctuant area. Should there be any doubt, needle aspiration of the cavity should be performed. In our patient, there was a small laceration at the tip of the coccyx on inspection. If we had not palpated the fluctuation, the degloving injury might have been missed.

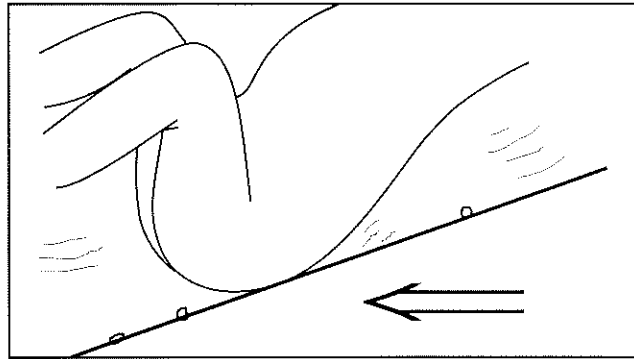
Most of the closed degloving injuries are related to lower extremity and the pelvic region. Injuries involving the lower back, as in our patient, are rarely seen. In a recent report, 23 of the 24 closed degloving injuries were over the region of the greater trochanter [3]. In another series, in only one of the 16 patients, the injury was located in the lower back [2]. In our opinion, the location of the closed degloving injury is strongly related with the mechanism of injury.

The extent of the degloving wound is usually between 2 to 12 percent of the total body surface area [2]. In our case, 18 percent of the body surface area was effected. This amount of massive injury can be attributed to the mechanism and the severity of the shearing force.

The management of the closed degloving injuries is controversial. Various methods like aspiration, injection of sclerosing agents such as tetracycline, compression dressings, and prolonged closed surgical drainage have been suggested in the literature [1-3]. We agree with Hak et al. that the best method of the treatment is open debridement [3]. The wounds can than be left open to heal by secondary intention. In selected patients delayed primary closure can be also considered. If skin necrosis occurs in time like in our patient, flaps or grafts may be used to close the defect.

Although 24 to 98 percent of the reported patients had associated injuries (intraabdominal, pelvic or musculo-skeletal), none of the authors reporting closed degloving

Figure 1: Scheme showing the mechanism of injury.



injuries stressed the impact of associated injuries on the healing of the degloved area [1-3]. Massive external or internal bleeding that cause hemorrhagic shock, orthopaedic injuries that require operation through degloved area, immobilization due to neurologic deficit may have a negative impact on the healing of the degloved wound. On the other hand, life-threatening injuries at the initial presentation may also prevent optimal treatment. While making the treatment plan for closed degloving injuries, associated injuries and the disability of the patient should be kept in mind.

Finally although rarely seen, surgeons who deal with trauma patients should keep in their mind the closed degloving injuries, and their possible difficult management.

#### REFERENCES

1. Hudson DA. Missed closed degloving injuries: late presentation as a contour deformity. *Plast Reconstr Surg* 1996;98:334-337.
2. Hudson DA, Knottenbelt JD, Krige JE. Closed degloving injuries: results following conservative surgery. *Plast Reconstr Surg* 1992;89:853-855.
3. Hak DJ, Olson SA, Matta JM. Diagnosis and management of closed internal degloving injuries associated with pelvic and acetabular fractures: the Morel-Lavallee lesion. *J Trauma* 1997;42:1046-1051.
4. Wynn-Williams D. The treatment of traumatic avulsion of the skin of the extremities. *Physiotherapy* 1970;56:88-90.
5. McGrouther DA, Sully L. Degloving injuries of the limbs: long-term review and management based on whole-body fluorescence. *Br J Plast Surg* 1980;33:9-24.
6. Letts RM. Degloving injuries in children. *J Pediatr Orthop* 1986;6:193-197.
7. Kudsk KA, Sheldon GF, Walton RL. Degloving injuries of the extremities and torso. *J Trauma* 1981;21:835-839.