

# Dieulafoy lesions: One patient, two different localizations

Ali Şenkaya, M.D., Ferit Çelik, M.D., Ahmet Ömer Özütemiz, M.D.

Department of Internal Medicine, Division of Gastroenterology, Ege University Faculty of Medicine, İzmir-Türkiye

## ABSTRACT

Dieulafoy lesions (DLs) are dilated submucosal arterial structures visualized on endoscopy as bleeding foci on the superficial mucosa without erosion or ulceration. DLs account for 1–5.8% of acute non-variceal upper gastrointestinal bleeding cases. A 72-year-old male patient with known Alzheimer's disease and coronary artery disease, being followed up at a nursing home, presented to our emergency department with foul-smelling, loose, and tarry stool. Esophagogastroduodenoscopy revealed a 3 mm DL immediately adjacent to the Z line in the distal esophagus, demonstrating a fresh blood clot without the appearance of a surrounding ulcer. Two endoscopic hemoclips were applied to this lesion. The patient was monitored at the intensive care unit for the following 2 days and later transferred to internal medicine inpatient unit. He developed hematochezia on the 8<sup>th</sup> day of hospitalization. Emergent rectosigmoidoscopy was performed showing two separate 3 and 4 mm sized DLs, located immediately proximal to the dentate line. These lesions were successfully treated using two endoscopic band ligations. DLs can occur synchronously, albeit very rarely, and a careful search for multiple lesions is necessary to avoid further bleeding.

**Keywords:** Dieulafoy lesions; gastrointestinal bleeding; synchronous.

## INTRODUCTION

Dieulafoy lesions (DLs) are dilated submucosal arterial structures visualized on endoscopy as bleeding foci on the superficial mucosa without erosion or ulceration. They are believed to be caused by localized mucosal ischemic damage and acquired vascular ectasia eroding through atrophic mucosa. DLs account for 1–5.8% of acute non-variceal upper gastrointestinal (GI) bleeding cases. Although DLs are generally asymptomatic, melena is seen in 44%, hematemesis in 30%, both melena and hematemesis in 18%, hematochezia in 6%, and iron deficiency anemia in 1% among symptomatic cases.<sup>[1]</sup>

DLs are more commonly seen in men and older age group.<sup>[2]</sup> Comorbidities are present in 90% of patients, with the most common being cardiovascular disease, hypertension, diabetes mellitus, liver disease, and kidney failure.<sup>[3]</sup> Disease etiology includes nonsteroidal anti-inflammatory medication and anticoagulant use, alcoholism, and fecalomas.<sup>[4]</sup> Approximately

70% of DLs are detected in the stomach and of those gastric lesions, 75% are localized in the proximal stomach, especially within 6 cm of the gastroesophageal junction. DLs can also occur as a source of lower GI bleeding, developing along the GI tract, including the duodenum, jejunum, ileum, cecum, appendix, colon, and anal canal.<sup>[1,2]</sup> Here, we describe a peculiar case, presented with recurrent upper and lower GI bleeding at the same inpatient setting due to separate synchronous DLs in the esophagus and rectum, which were successfully treated using endoscopy.

## CASE REPORT

A 72-year-old male patient with known Alzheimer's disease and coronary artery disease, being followed up at a nursing home, presented to our emergency department with foul-smelling, loose, and tarry stool. At the time of presentation, his pulse was 126 beats/min, blood pressure was 126/86 mmHg, and melena was detected on rectal examination. The patient

Cite this article as: Şenkaya A, Çelik F, Özütemiz AÖ. Dieulafoy lesions: One patient, two different localizations. *Ulus Travma Acil Cerrahi Derg* 2022;28:1531-1533.

Address for correspondence: Ferit Çelik, M.D.

Ege Üniversitesi Tıp Fakültesi, İç Hastalıkları Anabilim Dalı, Gastroenteroloji Bilim Dalı, İzmir, Türkiye

Tel: +90 444 13 43 E-mail: drferitcelik35@yahoo.com.tr

*Ulus Travma Acil Cerrahi Derg* 2022;28(10):1531-1533 DOI: 10.14744/tjtes.2021.95602 Submitted: 02.01.2021 Accepted: 16.02.2021

Copyright 2022 Turkish Association of Trauma and Emergency Surgery



## DISCUSSION

Although not common, DLs are severe and life-threatening causes of GI bleeding. They are most frequently localized in the stomach, they have also been described in the duodenum, colon, esophagus, and rectum.<sup>[1,2,4]</sup> DLs are generally seen in a single localization, and to the best of our knowledge, no case report presenting with synchronous DLs in the esophagus and rectum, was reported in the English literature before; thus, our paper is the first case report in this respect. According to Reilly and Al-Kawas, only 49% of DLs are identified during the first endoscopic examination, 33% of patients require a second examination, and 18% require explorative laparotomy for an accurate diagnosis. DLs can easily be overlooked on endoscopy due to mucosal inflammation and lack of ulceration. Therefore, DLs must be suspected in all patients without a clear GI bleeding focus.<sup>[5,6]</sup> CTA must be considered when investigating less affected areas, such as the esophagus and rectum, as possible localizations of DLs. In the current case, CTA was performed because of hematochezia. The presence of active extravasation from the distal rectum, as demonstrated in CTA, indicates the need for a more careful examination.

Hemostasis can be endoscopically achieved by mechanical methods, such as thermal or argon plasma coagulation, regional epinephrine or cyanoacrylate injection, endoscopic band ligation, and hemoclip application in patients with DLs. Mechanical methods are generally more effective than sclerotherapy and coagulation techniques. The recurrent bleeding rate in mechanical therapy combined with epinephrine injection is lower than that in monotherapy.<sup>[7-9]</sup> In the current case, hemostasis was achieved by endoscopic hemoclip application and band ligation to the lesions in the esophagus and rectum, respectively, without any recurrent bleeding.

Our case is highly peculiar because the patient presented with synchronous DLs in two different rare foci, as well as different presenting findings, such as melena and hematochezia that developed within a week. In the available English literature, we found a report of a 3-year-old child with four different DLs detected in the stomach that was treated endoscopically.<sup>[10]</sup> Another case report described a 15-year-old child with a DL in the stomach that was first treated with injection sclerotherapy, but surgical treatment was required after recurrent bleeding and detection of a synchronous separate focus in the jejunum on CTA.<sup>[11]</sup>

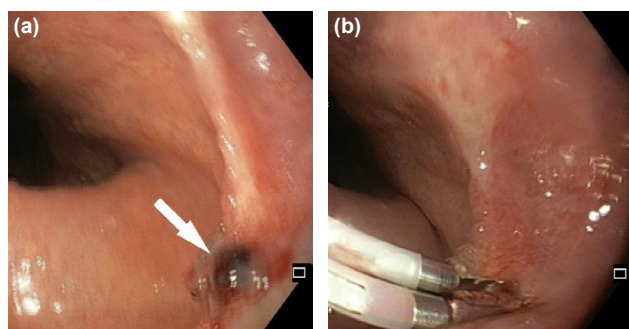
## Conclusion

To the best of our knowledge, our patient is the first adult case in the literature in which synchronous DLs caused bleeding both in the esophagus and the rectum, treated successfully with endoscopic approach. DLs can occur synchronously, albeit very rarely, and a careful search for multiple lesions is necessary to avoid further bleeding.

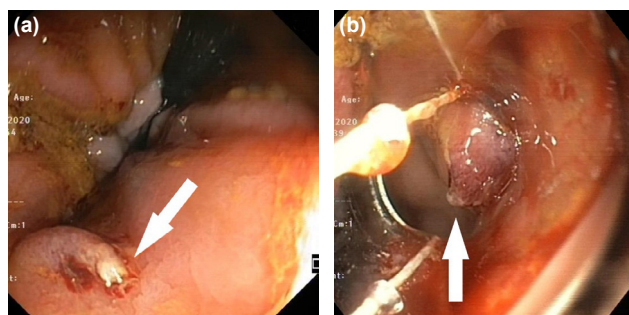
was taking 20 mg/day memantine and 100 mg/day acetylsalicylic acid. His hemoglobin (Hb) level (11.9 g/dl), platelet count (531,000/mm<sup>3</sup>), and coagulation parameters were within normal limits. Esophagogastroduodenoscopy (Olympus, GIFHD 190, Tokyo, Japan) revealed a 3 mm DL immediately adjacent to the Z line in the distal esophagus, demonstrating a fresh blood clot without the appearance of a surrounding ulcer (Fig. 1a). Two endoscopic hemoclips (QuickClip 2™ Olympus) were applied to this lesion (Fig. 1b).

The patient was monitored at the intensive care unit for the following 2 days and later transferred to internal medicine inpatient unit. He developed hematochezia on the 8<sup>th</sup> day of hospitalization. His Hb level was 7.9 g/dl, and subsequent computed tomography angiography (CTA) demonstrated active extravasation from the distal rectum. Subsequently, an emergent rectosigmoidoscopy was performed (Olympus GIFHD 190, Tokyo, Japan) showing two separate 3 and 4 mm sized DLs, located immediately proximal to the dentate line (Fig. 2a). These lesions were successfully treated using two endoscopic band ligations (Speedband Superview Super 7™ Boston multiple band ligator), as shown in Figure 2b.

The patient was transfused with two units of erythrocyte suspension during the hospital stay. Since his hemogram parameters remained stable during the follow-up without any evidence of bleeding, he was discharged on the 10<sup>th</sup> day of hospitalization. The patient, who has been followed up by phone since then, has been taking low-dose acetylsalicylic acid for 5 months and no recurrent bleeding has occurred.



**Figure 1.** (a) Dieulafoy lesion (white arrow) in the distal of the esophagus and (b) endoscopic hemoclips applied to the lesion.



**Figure 2.** (a) Dieulafoy lesion (white arrow) in the rectum and (b) endoscopic band ligation to the lesion (white arrow).

**Informed Consent:** Written informed consent was obtained from the patient for the publication of the case report and the accompanying images.

**Peer-review:** Internally peer-reviewed.

**Authorship Contributions:** Concept: A.Ö.Ö.; Design: F.Ç., A.Ş.; Supervision: A.Ö.Ö.; Data: A.Ş.; Analysis: F.Ç.; Literature search: A.Ö.Ö., F.Ç., A.Ş.; Writing: A.Ş., F.Ç.; Critical revision: A.Ö.Ö.

**Conflict of Interest:** None declared.

**Financial Disclosure:** The authors declared that this study has received no financial support.

## REFERENCES

1. Baxter M, Aly EH. Dieulafoy's lesion: Current trends in diagnosis and management. *Ann R Coll Surg Engl* 2010;92:548–54. [CrossRef]
2. Nojkov B, Cappell MS. Gastrointestinal bleeding from Dieulafoy's lesion: Clinical presentation, endoscopic findings, and endoscopic therapy. *World J Gastrointest Endosc* 2015;7:295–307. [CrossRef]
3. Senger JL, Kanthan R. The evolution of Dieulafoy's lesion since 1897: Then and now—a journey through the lens of a pediatric lesion with literature review. *Gastroenterol Res Pract* 2012;2012:432517. [CrossRef]
4. Norton ID, Peterson BT, Sorbi D, Balm RK, Alexander GL, Gostout CJ. Management and long-term prognosis of Dieulafoy lesion. *Gastrointest Endosc* 1999;50:762–7. [CrossRef]
5. Reilly HF 3rd, Al-Kawas FH. Dieulafoy's lesion. *Dig Dis Sci* 1991;36:1702–7. [CrossRef]
6. Squillace SJ, Johnson DA, Sanowski RA. The endosonographic appearance of a Dieulafoy's lesion. *Am J Gastroenterol* 1994;89:276–7.
7. Christoffersen RK, Nielsen TS, Vesterby A. Dieulafoy lesion of the esophagus causing massive upper gastrointestinal bleeding and death: A case report. *Am J Forensic Med Pathol* 2012;33:186–7. [CrossRef]
8. Batouli A, Kazemi A, Hartman MS, Heller MT, Midian R, Lupetin AR. Dieulafoy lesion: CT diagnosis of this lesser-known cause of gastrointestinal bleeding. *Clin Radiol* 2015;70:661–6. [CrossRef]
9. Dulic-Lakovic E, Dulic M, Hubner D, Fuchssteiner H, Pachofszky T, Stadler B, et al. Bleeding dieulafoy lesions of the small bowel: A systematic study on the epidemiology and efficacy of enteroscopic treatment. *Gastrointest Endosc* 2011;74:573–80. [CrossRef]
10. Baldwin CL, Wilsey M. Three year old male with multiple Dieulafoy lesions treated with epinephrine injections via therapeutic endoscopy. *Pediatr Gastroenterol Hepatol Nutr* 2016;19:276–80. [CrossRef]
11. Marangoni G, Cresswell AB, Faraj W, Shaikh H, Bowles MJ. An uncommon cause of life-threatening gastrointestinal bleeding: 2 synchronous Dieulafoy lesions. *J Pediatr Surg* 2009;44:441–3. [CrossRef]

## OLGU SUNUMU - ÖZ

### Dieulafoy lezyonu: Bir hasta, iki farklı lokalizasyon

Dr. Ali Şenkaya, Dr. Ferit Çelik, Dr. Ahmet Ömer Özütemiz

Ege Üniversitesi Tıp Fakültesi, İç Hastalıkları Anabilim Dalı, Gastroenteroloji Bilim Dalı, İzmir

Dieulafoy lezyonu, erozyon veya ülserasyon olmaksızın, yüzeysel mukozada kanama odakları olarak endoskopide görülebilen, dilate submukozal arter yapılarıdır. Dieulafoy lezyonları, akut varis dışı üst gastrointestinal kanama vakalarının %1–%5.8'ini oluşturur. Huzurevinde kalan Alzheimer hastalığı ve koroner arter hastalığı olduğu bilinen 72 yaşında erkek hasta, acil servisimize kötü kokulu, cıvık kıvamlı ve katran renginde dışkı ile başvurdu. Özofagogastroduodenoskopide, distal özofagusta Z çizgisinin hemen proksimalinde 3 mm'lik bir Dieulafoy lezyonu izlendi ve çevreleyen ülser görünümü olmaksızın taze bir kan pıhtısı görüldü. Bu lezyona iki endoskopik hemoklip uygulandı. Hasta işlem sonrasında iki gün yoğun bakım ünitesinde izlendi ve daha sonra serviste tedavi ve takibe alındı. Yatışının sekizinci gününde hematokezya gelişti. Yapılan rektosigmoidoskopide dentat hattın hemen proksimalinde yer alan iki adet 3 ve 4 mm boyutlu Dieulafoy lezyonu saptandı. Bu lezyonlara, iki endoskopik bant ligasyonu uygulanarak başarıyla tedavi edildi. Dieulafoy lezyonları çok nadir de olsa eşzamanlı olarak ortaya çıkabilir ve daha fazla kanamayı önlemek için birden fazla lezyonun dikkatli bir şekilde araştırılması gerekir.

**Anahtar sözcükler:** Dieulafoy lezyonu; gastrointestinal kanama; senkron.

*Ulus Travma Acil Cerrahi Derg* 2022;28(10):1531-1533 doi: 10.14744/tjtes.2021.95602