

Do MRI agents cause or worsen acute pancreatitis?

MR ajanları akut pankreatite neden olabilir mi?

Cengiz ERENOĞLU,¹ Ahmet Haldun ULUUTKU,¹ Cihan TOP,²
Mehmet Levhi AKIN,¹ Tuncay ÇELENK¹

Acute pancreatitis is still one of the challenging issues in general surgical practice in terms of diagnosis, management and follow-up. CT evaluation of the patients with acute pancreatitis gained popularity in order to document necrosis within the pancreatic tissue which is one of the most important factor linked to the morbidity and even mortality of the disease. Recent studies evidenced that agents used for CT evaluation might also contribute to pancreatic inflammation and cause necrosis. Recently, magnetic resonance imaging (MRI) with gadolinium has been speculated as a safer mean of providing optimum imaging of the pancreas than contrast enhanced CT. In this article we report an unusual case of acute pancreatitis which might have been initiated and/or worsened by gadolinium.

Key Words: Gadolinium DTPA/diagnostic use; Magnetic Resonance Imaging; pancreatitis, acute necrotizing/diagnosis.

Akut pankreatit tanı, tedavi ve takip açısından cerrahinin hala baş etmekte zorlandığı önemli konularından birisidir. Akut pankreatitli hastaların bilgisayarlı tomografi (BT) ile değerlendirilmesi, hastalığın morbidite ve mortalitesini etkileyen en önemli faktörlerden birisi olan pankreatik nekrozu görüntüleme başarıları nedeniyle popülerite kazanmıştır. Son çalışmalar BT için kullanılan ajanların pankreas enflamasyonu ve nekrozuna katkıda bulunabileceğine işaret etmektedir. Ayrıca manyetik rezonans görüntüleme için verilen gadoliniumun ise pankreası görüntülemeye kontrast BT ajanlarından daha güvenli olduğu ifade edilmektedir. Bu yazıda gadolinium tarafından tetiklenmiş ve/veya şiddetlenmiş bir akut pankreatit olgusu irdelendi.

Anahtar Sözcükler: Gadolinium DTPA/tanı; manyetik rezonans görüntüleme; pankreatit, akut nekroz/tanı.

Although, imaging pancreas with contrast enhanced computed tomography (CT) in patients having or suspected to have acute pancreatitis, has become increasingly popular, several experimental and clinical studies supported that ionic and nonionic contrast agents used for CT evaluation increased the severity of necrotizing acute pancreatitis by aggravating the already existing impairment of pancreatic microcirculation.^[1,2]

Recently, magnetic resonance imaging (MRI) with gadolinium has been speculated as a safer mean of providing optimum imaging of the pancreas than contrast enhanced CT.^[3] In this article we report an unusual case of acute pancreatitis which might have been triggered and/or worsened by gadolinium.

CASE REPORT

A 45-year old woman presented with complaints of acute onset of upper abdominal pain and vomiting four hours after cranial MRI evaluation for her two month-lasting visual and neurological symptoms that revealed hypophyseal macroadenoma. Following intravenous injection of 15 mL (0.2 mL/kg body weight) gadodiamide (Magnevist TM, Schering Ltd., Germany) she developed abdominal symptoms and clinical deterioration. On initial examination, the patient was afebrile and tachycardic. Abdominal palpation revealed tenderness on the upper quadrants of the abdomen. Blood tests revealed values within normal ranges except for total white cell count (16x10⁹/L), glucose (10.56 mmol/L), serum amylase (3145 U/L) and lactic

Departments of ¹General Surgery and ²Internal Medicine, Gülhane Military Medicine Academy, Istanbul, Turkey.

Gülhane Askeri Tıp Akademisi, ¹Genel Cerrahi Anabilim Dalı, ²Dahiliye Anabilim Dalı, İstanbul.

Correspondence (İletişim): Cengiz Erenoglu, M.D. Altunizade Konutları, Sırmaperde Sok., B Blok D:1, 34662 Altunizade, İstanbul, Turkey.
Tel: +90 - 216 - 651 20 09 Fax (Faks): +90 - 216 - 348 78 80 e-mail (e-posta): cengizerenoglu@hotmail.com

dehydrogenase (912 IU/L). Abdominal sonography proved pancreatitis by stating enlarged and heterogeneous pancreas as well as a single 13 mm diameter gallbladder stone which was not known by the patient. Upon deterioration of the clinical findings, twelve hours after the onset of the abdominal symptoms, abdominal MRI was employed in order to document the severity of the pancreatitis and MRI proved severe necrotizing pancreatitis (Fig. 1). According to clinical and MRI findings, the patient was fully monitored, allowed nothing *per os* and admitted to the intensive care unit. Deterioration of the clinical and abdominal signs along with laboratory tests necessitated urgent laparotomy which proved intense inflammation at the site of porta hepatis and necrosis on the pancreatic corpus. According to these findings the patient underwent cholecystectomy, T-tube drainage of the bile duct as well as pancreatic necrosectomy. Patient did well after the operation and postoperative course was uneventful except for a low volume pancreatic fistula. Patient was discharged on postoperative day 20 with pancreatic fistula which was closed completely following endoscopic sphincterotomy via ERCP.

DISCUSSION

Although it has become increasingly popular to image the pancreas with CT, several experimental and clinical studies supported that ionic and non-ionic contrast agents used for CT evaluation increased the severity of necrotizing acute pancreatitis by aggravating the already existing impairment of pancreatic microcirculation.^[1,2] Because of its relative safety over CT agents, gadolinium is increasingly being used as a contrast agent in interventional radiology. Despite its safety, however, there have been two recent case reports of pancreatitis triggered by administration of gadolinium for MRI investigation.^[4,5] Although in our case the gallbladder stone might have been an etiological factor for the pancreatitis, the acute onset of the abdominal symptoms just four hours following the MRI evaluation in such an asymptomatic patient and worsening of the pancreatitis after the second MRI evaluation increased the likelihood of gadolinium as have being the etiologic agent for pancreatitis or at least the co-factor worsening the course of the inflammation in necrotizing pancreatitis along with the gallstone. Even though the exact mechanism of

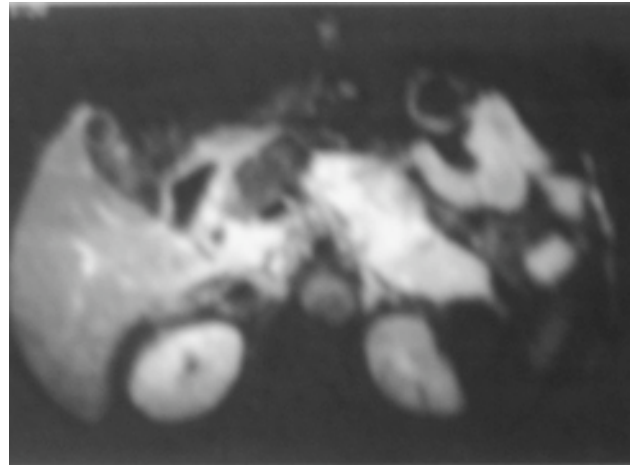


Fig. 1. MRI of abdomen with enlarged and necrotic pancreas.

gadolinium as an etiologic factor for pancreatitis is unknown, the administration of this contrast agent in patients with an already inflamed pancreas might aggravate the impairment of pancreatic microcirculation. Further experimental and clinical studies must be conducted in order to investigate the pathogenic consequences of gadolinium-triggered acute necrotizing pancreatitis. Our experience with this patient emphasizes that despite the safety of gadolinium over contrast agents used for CT imaging, it should still be kept in mind that gadolinium might either be an inducing factor alone or a worsening factor along with other etiologic factors such as gallstones for necrotizing pancreatitis.

REFERENCES

1. Schmidt J, Hotz HG, Foitzik T, Ryschich E, Buhr HJ, Warshaw AL, et al. Intravenous contrast medium aggravates the impairment of pancreatic microcirculation in necrotizing pancreatitis in the rat. *Ann Surg* 1995;221:257-64.
2. Foitzik T, Bassi DG, Schmidt J, Lewandrowski KB, Fernandez-del Castillo C, Rattner DW, et al. Intravenous contrast medium accentuates the severity of acute necrotizing pancreatitis in the rat. *Gastroenterology* 1994;106:207-14.
3. Werner J, Schmidt J, Warshaw AL, Gebhard MM, Herfarth C, Klar E. The relative safety of MRI contrast agent in acute necrotizing pancreatitis. *Ann Surg* 1998;227:105-11.
4. Schenker MP, Solomon JA, Roberts DA. Gadolinium arteriography complicated by acute pancreatitis and acute renal failure. *J Vasc Interv Radiol* 2001;12:393.
5. Terzi C, Sokmen S. Acute pancreatitis induced by magnetic-resonance-imaging contrast agent. *Lancet* 1999;354:1789-90.