

# Early surgical repair or conservative treatment? Comparing patients with penile fracture concerning long-term sexual functions

✉ Kubilay Sarıkaya, M.D., ✉ Çağrı Şenocak, M.D., ✉ Fahri Erkan Sadioğlu, M.D.,  
✉ Ömer Faruk Bozkurt, M.D., ✉ Mehmet Çiftçi, M.D.

Department of Urology, University of Health Sciences, Keçiören Training and Research Hospital, Ankara-Turkey

## ABSTRACT

**BACKGROUND:** To compare the patients who underwent early surgical repair of penile fracture, which is one of the urological emergencies, and patients who recovered with conservative treatment concerning long-term sexual functions.

**METHODS:** The data of 42 patients who applied to our clinic with penile fracture between January 2010 and January 2020 were retrospectively analyzed. The patients were categorized into two groups as early operated and followed-up conservatively. The pre-operative and postoperative findings of the patients were compared with the International Erectile Function Scale (IIEF-6) scores in the long-term follow-up.

**RESULTS:** The median age of the patients was 35 (20–65) years and the median follow-up period was 52 (8–120) months. The postoperative mean IIEF-6 score of the patients was  $22.98 \pm 6.52$ . There was no significant difference between the surgical and the conservative groups concerning postoperative complications ( $p=0.460$ ). In the follow-up period, the presence of palpable plaque on the rupture area was significantly higher in the conservative group ( $p=0.041$ ). However, there was no significant difference between the groups concerning IIEF-6 scores ( $p=0.085$ ).

**CONCLUSION:** Although there is no significant difference in long-term IIEF-6 scores between the two groups, the rate of palpable plaque formation is higher in patients followed-up conservatively. Therefore, early surgical repair should be considered in the foreground, especially in patients with a large rupture area.

**Keywords:** Conservative treatment; penile fracture; sexual functions.

## INTRODUCTION

Penile fracture is one of the rare urological emergencies that arises from the rupture of the corpus cavernosa tunica albuginea layer as a result of external trauma of the erect penis.<sup>[1]</sup> Its incidence is reported as 1/175,000.<sup>[2]</sup> The most common etiological factor is reported as sexual intercourse in the USA and European countries.<sup>[3]</sup> However, forceful bending applied to the penis to provide fast detumescence of the erect penis known as “Taqaandan” in Middle Eastern and North African countries has an important place in fracture etiology.<sup>[4]</sup> Masturbation, falling on the erect penis and Clostridium

histoliticum collagen injection into the penis for the treatment of Peyronie’s disease is among other etiological factors.<sup>[5]</sup> Generally, the “pop” sound of a fracture in the penis after trauma and the subsequent pain and sudden detumescence story are typical in patients.<sup>[6]</sup> Edema, ecchymosis and shape deformity in the penis, known as “eggplant deformity”, are observed in the physical examination (Fig. 1). The diagnosis can be almost certainly made by history and physical examination, but additional tests may be required to evaluate the location and size of the rupture and the presence of urethral defect.<sup>[7]</sup> Ultrasonography and MRI are helpful tests in diagnosis. In addition, retrograde urethrogram (RGU) and

Cite this article as: Sarıkaya K, Şenocak Ç, Sadioğlu FE, Bozkurt ÖF, Çiftçi M. Early surgical repair or conservative treatment? Comparing patients with penile fracture concerning long-term sexual functions. *Ulus Travma Acil Cerrahi Derg* 2021;27:249-254.

Address for correspondence: Kubilay Sarıkaya, M.D.

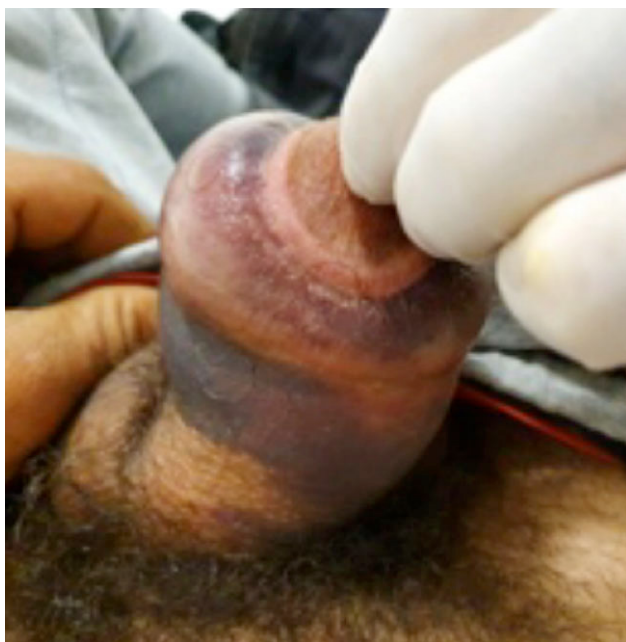
Sağlık Bilimleri Üniversitesi, Keçiören Eğitim ve Araştırma Hastanesi, Üroloji Kliniği, Ankara, Turkey

Tel: +90 312 - 356 90 00 E-mail: drkubilay.sarikaya76@outlook.com

*Ulus Travma Acil Cerrahi Derg* 2021;27(2):249-254 DOI: 10.14744/tjtes.2021.92662 Submitted: 15.11.2020 Accepted: 14.02.2021

Copyright 2021 Turkish Association of Trauma and Emergency Surgery



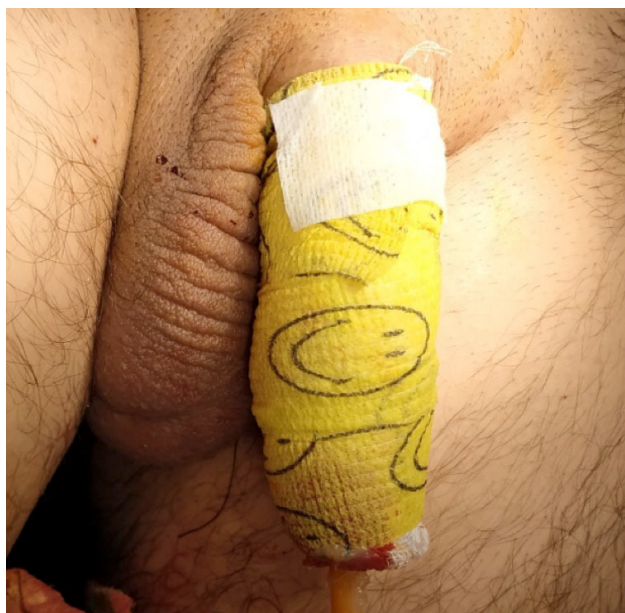


**Figure 1.** “Eggplant deformity” of penile fracture.

cystoscopy are recommended in the trauma guideline of the European Association of Urology (EAU) to evaluate urethral integrity.<sup>[8]</sup> Although penile fractures were initially followed conservatively, early surgical repair has been reported to yield better results since 1971, and surgical repair has taken its place as the priority treatment option.<sup>[9]</sup> The conservative approach is currently recommended in selected cases with small defects and limited penile deformity.<sup>[10]</sup> One of the most important problems in patients with penile fractures is sexual problems, such as erectile dysfunction (ED), penile pain and penile plaque formation that may develop in the long term. There are several studies in which penile fracture patients with surgical repair and patients followed conservatively were evaluated separately in terms of sexual functions.<sup>[11,12]</sup> However, the number of studies comparing these two approaches concerning sexual functions in the long term is very limited in the literature. Therefore, in this study, we aimed to compare the effects of these two treatment options on the long-term sexual functions of patients.

## MATERIALS AND METHODS

After obtaining ethical approval from the ethics committee of our hospital, the data of 42 patients who admitted to our clinic with a penile fracture between January 2010 and January 2020 were analyzed retrospectively. Etiological factors of fracture, tunica albuginea defect size, fracture localization and accompanying urethral rupture were determined and recorded. While emergency ultrasonography was performed in all patients, MRI was performed in eight patients and RGU was performed in six patients with a suspected urethral rupture, and cystoscopy was performed in five patients. Tunica albuginea defect size was measured by penile Doppler ultrasonography. The tunical defect <1.5 cm was classified as small



**Figure 2.** Conservative treatment of penile fracture with mild-moderate pressure bandage.

defect. Patients were divided two groups as a conservative follow-up group and surgical repair group, according to the treatment approach applied. Conservative treatment was considered in the foreground in patients with a defect area smaller than 1.5 cm, with no advanced hematoma and penile deformity, while early surgical treatment was applied in other patients.

Following urethral catheterization, mild-to-moderate pressure penile bandage was applied to the patients in the conservative follow-up group (Fig. 2), oral 3<sup>rd</sup> generation cephalosporin was administered and the penile bandage was removed on the 7<sup>th</sup> day. Later, the patients were called for control once a week for a month. In three patients with de novo urethral rupture, a urethral catheter was placed during cystoscopy and the catheter was removed after 7<sup>th</sup> day. Then, the patients were called for control at 3<sup>rd</sup>, 6<sup>th</sup>, and 12<sup>th</sup> months and were evaluated for possible urethral stricture and penile plaque development. Penile plaque formation was determined by physical examination and the patients with a suspected penile plaque were investigated by penile Doppler ultrasonography. Surgery was performed with circumferential penile degloving technique in patients with an early surgical repair. After a 16–18 F urethral catheter was placed in the bladder, a suspension suture was placed on the glans penis and the penis was degloved all around, then, the tunical defect area was detected. Hematoma and necrotic tissue were excised carefully and the defect area was seen clearly. Then, absorbable 2/3-zero Vicryl suture was used for the repair of the rupture area using the brying knot technique. On the postoperative 1<sup>st</sup> day, the patients were discharged by starting oral 3<sup>rd</sup> generation cephalosporin after the urethral catheters were removed. Patients in the surgery group were given daily outpatient dressing for one week and were called for control at the 1<sup>st</sup>

3<sup>rd</sup>, 6<sup>th</sup> and 12<sup>th</sup> months after the 1<sup>st</sup> week. A ban of sexual intercourse for at least six weeks was recommended for all patients in both groups. International Erectile Function Scale (IIEF-6) scores were determined by telephone calling and questioning the patients. Six questions were asked by patients and score points between 1–30 points are obtained from the IIEF-6 scoring system, which has been validated in Turkish.<sup>[13]</sup> According to this scoring system, 10 points or less severe ED, 11–16 points moderate ED, 17–21 points mild-moderate ED, 22–25 points mild ED and 26–30 points are considered normal. The results of the patients were evaluated and the groups were compared.

## Statistical Analysis

All statistical analyses were performed using the SPSS 24.0 (IBM Corp., Chicago) software for Windows. In the univariate analysis, the Chi-Square Test was used for nominal data, while the Mann-Whitney U test was used for nonparametric variables. A p-value of <0.05 was considered statistically significant.

## RESULTS

The patients' median age was 35 (20–65) years, and the median follow-up time was 52 (8–120) months. It was observed that 22 (52.4%) of the patients were in the surgical repair group, and 20 (47.6%) were in the conservative follow-up group. While sexual intercourse was the etiological factor causing fractures in 30 (71.4%) of the patients, trauma caused by falling on the erect penis in six (14.3%) patients, rigid masturbation maneuver in four (9.5%) patients and a history of taqaandan in two (4.8%) patients. The mean IIEF-6 score was 22.98±6.52 in the long-term follow-up. The total characteristic data and follow-up results of the patients are shown in Table 1. The patients' median age was 29.5 (20–65) years in the conservative follow-up group, while it was 39.5 (21–57) years in the surgical repair group, but there was no significant difference between the groups (p=0.221). There was no significant difference between conservative and surgical groups concerning etiological factors of fracture and fracture location (p=0.998 and p=0.984, respectively). De-novo urethral rupture was detected in three (15%) patients in the conservative follow-up group, whereas no urethral rupture was detected in the surgical repair group (p=0.099). The mean size of TA defects in the conservative follow-up group was 9.55±3.34 mm, while it was 11.23±5.87 mm in the surgical repair group, but there was no significant difference between the groups (p=0.621). Penile plaque development was observed in six (30.0%) patients in the conservative follow-up group, while it was detected in only one (4.5%) patient in the surgical repair group, and penile plaque development was significantly higher in the conservative follow-up group (p=0.041). Concerning IIEF-6 scores, it was observed that the surgical repair group was slightly more advantageous than the conservative follow-up group, but there was no statistical-

**Table 1.** Characteristics of the patients (n=42)

Age, median (range), years	35 (20–65)
Follow-up, median (range), months	52 (8–120)
Tunica albuginea defect size, mean±SD, mm	10.43±4.86
IIEF-6 score, (0–30), mean±SD	22.98±6.52
Etiology, n (%)	
Sexual intercourse	30 (71.4)
Trauma	6 (14.3)
Masturbation	4 (9.5)
Taqaandan	2 (4.8)
Treatment method, n (%)	
Operation	22 (52.4)
Conservative	20 (47.6)
Fracture location, n (%)	
Distal penile	4 (9.5)
Mid-penile	11 (26.2)
Proximal penile	27 (64.3)
Complication, n (%)	
Skin infection	3 (7.1)
Skin necrosis	2 (4.7)
Urine retention	2 (4.7)
Urethral stricture	2 (4.7)

SD: Standard deviation.

ly significant difference between the groups (24.91±4.83 vs 20.85±7.54, p=0.085). Comparative data of the groups are shown in Table 2.

## DISCUSSION

Penile fracture, which is one of the rare, urgent urological cases, was first described by Malis and Zur in 1924 and present in the modern medical literature.<sup>[14]</sup> External trauma to the erect penis is mostly caused by the backward bending of the erect penis in the position where the woman is on top during sexual intercourse.<sup>[15]</sup> In our study, it was determined that while sexual intercourse took the first place in 30 (71.4%) patients in fracture etiology, the “Taqaandan” maneuver was culturally present, especially in the Eastern and Southeastern regions of our country and two (4.8%) patients applied with a penile fracture formed for this reason. External trauma caused by falling onto the erect penis was detected in six (14.6%) patients, while four (9.5%) patients had a history of hard masturbating manipulation, and our findings are consistent with the literature data.

Penile fractures are commonly seen in the region close to the suspensory penile ligament and more rarely in the mid-penile and distal penile regions.<sup>[16]</sup> Similar to the literature in our study, the most common localization of the

**Table 2.** Comparison of the groups

	Conservative (n=20)	Operation (n=22)	p-value
Age, median (range), years	29.5 (20–65)	39.5 (21–57)	0.221
TA defect size, mean±SD, mm	9.55±3.34	11.23±5.87	0.621
IIEF-6 score, (0–30), mean±SD	20.85±7.54	24.91±4.83	0.085
Etiolog, n (%)			0.998
Sexual intercourse	14 (70.0)	16 (72.7)	
Trauma	3 (15.0)	3 (13.6)	
Masturbation	2 (10.0)	2 (9.1)	
Taqaandan	1 (5.0)	1 (4.5)	
Fracture location, n (%)			0.984
Distal penile	2 (10.0)	2 (9.1)	
Mid-penile	5 (25.0)	6 (27.3)	
Proximal penile	13 (65.0)	14 (63.6)	
De-novo urethral rupture, n (%)	3 (15.0)	0 (0)	0.099
Penile plaque, n (%)	6 (30.0)	1 (4.5)	0.041
Complication, n (%)			0.460
Skin infection	2 (10.0)	1 (4.5)	
Skin necrosis	2 (10.0)	0 (0)	
Urine retention	0 (0)	2 (9.0)	
Urethral stricture	1 (5.0)	1 (4.5)	

SD: Standard deviation.

fracture was observed in 27 (64.3%) patients in the ventrolateral of the proximal penis. Many surgical techniques aiming to reach the fracture area easily and reduce the risk of neurovascular damage have been defined. Circumferential penile degloving, a direct longitudinal incision in the damaged area, inguino-scrotal approach, midline raphe incision and suprapubic approach techniques are the main surgical methods.<sup>[17]</sup> In our study, the penile degloving technique with a circumferential incision was applied in all patients in the surgical repair group. This technique allows all hematoma accumulated in the dartos layer to be evacuated and all necrotic tissues caused by hematoma to be removed. In addition, De-novo urethral damage repair can be performed easily in necessary cases. On the other hand, although the selection of the suture material used in the repair of the fracture area varies in various studies, it has been reported that the use of both non-absorbable and absorbable sutures provides similar results.<sup>[16,17]</sup>

In many studies, early surgical repair of penile fracture has been shown to be very successful in preserving sexual functions in the postoperative period. Zargooshi reported the results of 352 patients who were operated on for penile fracture.<sup>[18]</sup> In this study, 214 (98.6%) of 217 patients who had sexual partners in the postoperative period were reported to be potent and the mean IIEF-6 score of the patients was 29.8±1.1. Additionally, in this study, it was report-

ed that an insignificant palpable nodule was detected in the proximal penis in 330 (93.7%) patients. In another similar study, Sharma et al.<sup>[19]</sup> reported the results of 20 patients, 14 of whom were sexually active, who underwent surgical repair. In this study, it was reported that the mean Sexual Health Inventory for Men (SHIM) score was 21.36±1.33 and the mean Erection Hardness Score (EHS) was 3.21±0.43, and as a result, sexual functions were well preserved. On the other hand, in this study, it was reported that four of 20 patients had penile nodules and two of them developed insignificant penile curvature. In another recent study, Kati et al.<sup>[20]</sup> compared the preoperative and postoperative IIEF-5 scores of 56 patients who underwent penile fracture repair and aimed to show the effect of surgical repair on erectile functions. According to this study, the preoperative mean IIEF-5 score of the patients was 22±0.6, while the mean IIEF-5 score at the postoperative 6th month was 20±1.1, and it was reported that erectile functions were well preserved after surgery. In another similar study, Nason et al.<sup>[17]</sup> reported the results of 17 patients in whom they performed penile fracture repair. According to this study, in the postoperative period, 14 patients had an IIEF-5 score of >22 and their erectile functions were well preserved. Other one patient's IIEF-5 score was 17–21 (mild ED), and one patient's IIEF-5 score was 12–16 (mild-moderate ED). However, it was reported that none of the patients had severe ED that could not provide vaginal penetration.

Similar to the literature data, in our study, the mean IIEF-6 score was  $24.91 \pm 4.83$  in patients with an early surgical repair and it was observed that erectile functions were preserved quite well. In the postoperative period, the palpable nodule was detected in only one (4.5%) patient in the early surgery group, and this result supports the idea that early surgical repair significantly reduces the rate of palpable nodule formation and secondary penile curvature. On the other hand, "inverted stitch" suture burying technique with 2/3-zero absorbable Vicryl suture was used in all patients we underwent surgical repair. The suture burying technique we used and the absorbability of the suture might contribute to the reduction of palpable plaque development in the long term. Although early surgical repair is currently the gold standard of penile fracture treatment, conservative follow-up is still an alternative treatment option, especially in selected patients with small TA defects and no advanced penile deformity and penile hematoma.<sup>[11,12]</sup> The advantages of conservative follow-up include no need for anesthesia, minimal invasiveness, low cost and easy application. Martinez et al.<sup>[21]</sup> in their article discussing conservative and surgical treatment in penile fracture they stated that early surgical repair provides better results and that it is more advantageous in returning to sexual activity with lower morbidity and shorter hospitalization time. In another recent study, Ouellette et al.<sup>[22]</sup> reported the results of 32 patients in which they compared conservative follow-up and surgical repair in penile fracture treatment.

According to this study, conservative treatment was applied to 14 (44%) patients with minimal pain, no difficulty in urination, and small ultrasound tear area, while 18 (56%) patients underwent emergency surgical repair. In this study, it was reported that no early postoperative complications developed in 18 (56%) patients who underwent emergency surgery. Additionally, in this study, it was reported that there were no major complications in any patient who underwent conservative treatment or surgical repair; however, five patients with conservative treatment required further surgical repair. In our study, it was observed that there was no difference between the conservative follow-up group and the surgical treatment group in terms of early complications. None of the patients in the conservative follow-up group required subsequent surgical repair. Similar to the literature in our study, it was observed that the mean IIEF-6 score of the patients in the surgical treatment group was slightly better than the conservative treatment group in the long-term follow-up, but there was no statistically significant difference between the groups. However, as a result of our study, it was seen that the formation of palpable plaques causing discomfort in the penis in the conservative follow-up group was significantly higher than the surgical repair group in the long-term follow-up. This result is in accordance with the literature and supports the idea that the defect area is more risky concerning plaque development in the spontaneous recovery process in patients who undergo conservative follow-up.

## Limitations

Our study has some limitations. The most important limitation was the retrospective nature of our study. Also, the IIEF-6 data of the patients before penile fracture were not recorded. Another limitation was that the presence of penile curvature could not be detected in patients with palpable plaques.

## Conclusion

Early surgical repair should be considered as the first choice in penile fracture treatment. Early postoperative complication rate of early surgical repair is very low. In addition, early surgical repair is very advantageous in terms of preserving the erectile functions of patients in the long term and achieving good cosmetic results. Although conservative follow-up provides erectile functions similar to early surgical repair, conservative follow-up should be considered, especially in selected patients with a small fracture area and it should be known that the risk of palpable penile plaque that may develop in the long term is high. Early surgical repair should be the primary choice, especially in the presence of extensive hematoma, with a large rupture area and severe penile deformity.

**Ethics Committee Approval:** Approved by the local ethics committee.

**Peer-review:** Internally peer-reviewed.

**Authorship Contributions:** Concept: K.S., Ç.Ş., F.E.S.; Design: K.S., Ç.Ş., Ö.F.B.; Supervision: Ç.Ş., Ö.F.B., M.Ç.; Resource: K.S., M.Ç.; Materials: K.S., F.E.S., M.Ç.; Data: K.S., F.E.S., M.Ç.; Analysis: Ç.Ş., F.E.S., Ö.F.B.; Literature search: K.S., Ç.Ş.; Writing: K.S., F.E.S.; Critical revision: Ç.Ş., Ö.F.B.

**Conflict of Interest:** None declared.

**Financial Disclosure:** The authors declared that this study has received no financial support.

## REFERENCES

1. Mazaris EM, Livadas K, Chalikopoulos D, Bisas A, Deliveliotis C, Skolarikos A. Penile fractures: immediate surgical approach with a midline ventral incision. *BJU Int* 2009;104:520–3. [\[CrossRef\]](#)
2. Amer T, Wilson R, Chlosta P, AlBuheissi S, Qazi H, Fraser M, et al. Penile Fracture: A Meta-Analysis. *Urol Int* 2016;96:315–29. [\[CrossRef\]](#)
3. Kamdar C, Mooppan UM, Kim H, Gulmi FA. Penile fracture: preoperative evaluation and surgical technique for optimal patient outcome. *BJU Int* 2008;102:1640–4. [\[CrossRef\]](#)
4. Falcone M, Garaffa G, Castiglione F, Ralph DJ. Current Management of Penile Fracture: An Up-to-Date Systematic Review. *Sex Med Rev* 2018;6:253–60. [\[CrossRef\]](#)
5. Beilan JA, Wallen JJ, Baumgarten AS, Morgan KN, Parker JL, Carrion RE. Intralesional Injection of Collagenase Clostridium histolyticum May Increase the Risk of Late-Onset Penile Fracture. *Sex Med Rev* 2018;6:272–8. [\[CrossRef\]](#)
6. Mydlo JH, Hayyeri M, Macchia RJ. Urethrography and cavernosography imaging in a small series of penile fractures: a comparison with surgical

- findings. *Urology* 1998;51:616–9. [CrossRef]
7. Gupta N, Goyal P, Sharma K, Bansal I, Gupta S, Li S, et al. Penile fracture: role of ultrasound. *Transl Androl Urol* 2017;6:580–4. [CrossRef]
  8. Kitrey ND, Djakovic N, Hallscheidt P, Kuehhas FE, Lumen N, Serafetinidis E, et al. EAU Guidelines presented at the EAU Annual Congress Copenhagen 2018. Available from: <https://uroweb.org/wp-content/uploads/EAU-Guidelines-on-Urological-Trauma-2018-large-text.pdf>.
  9. Thompson RF. Rupture of the penis. *J Urol* 1954;71:226. [CrossRef]
  10. Gedik A, Kayan D, Yamiş S, Yılmaz Y, Bircan K. The diagnosis and treatment of penile fracture: our 19-year experience. *Ulus Travma Acil Cerrahi Derg* 2011;17:57–60. [CrossRef]
  11. Wong NC, Dason S, Bansal RK, Davies TO, Braga LH. Can it wait? A systematic review of immediate vs. delayed surgical repair of penile fractures. *Can Urol Assoc J* 2017;11:53–60. [CrossRef]
  12. Gamal WM, Osman MM, Hammady A, Aldahshoury MZ, Hussein MM, Saleem M. Penile fracture: long-term results of surgical and conservative management. *J Trauma* 2011;71:491–3. [CrossRef]
  13. Rosen RC, Cappelleri JC, Smith MD, Lipsky J, Peña BM. Development and evaluation of an abridged, 5-item version of the International Index of Erectile Function (IIEF-5) as a diagnostic tool for erectile dysfunction. *Int J Impot Res* 1999;11:319–26. [CrossRef]
  14. Malis J, Zur K. Der fractura penis. *Arch Klin Chir* 1924;129:651. [Article in German]
  15. Barros R, Schulze L, Ornellas AA, Koifman L, Favorito LA. Relationship between sexual position and severity of penile fracture. *Int J Impot Res* 2017;29:207–9. [CrossRef]
  16. Kominsky H, Beebe S, Shah N, Jenkins LC. Surgical reconstruction for penile fracture: a systematic review. *Int J Impot Res* 2020;32:75–80.
  17. Nason GJ, McGuire BB, Liddy S, Looney A, Lennon GM, Mulvin DW, et al. Sexual function outcomes following fracture of the penis. *Can Urol Assoc J* 2013;7:252–7. [CrossRef]
  18. Zargooshi J. Sexual function and tunica albuginea wound healing following penile fracture: An 18-year follow-up study of 352 patients from Kermanshah, Iran. *J Sex Med* 2009;6:1141–50. [CrossRef]
  19. Sharma AP, Narain TA, Devana SK, Tyagi S, Parmar KM, Bora GS, et al. Clinical spectrum, diagnosis, and sexual dysfunction after repair of fracture penis: Is no news good news? *Indian J Urol* 2020;36:117–22. [CrossRef]
  20. Kati B, Akin Y, Demir M, Boran OE, Gumus K, Ciftci H. Penile fracture and investigation of early surgical repair effects on erectile dysfunction. *Urologia* 2019;86:207–10. [CrossRef]
  21. Martínez Portillo FJ, Seif C, Braun PM, Spahn M, Alken P, Jünemann KP. Penile fractures: controversy of surgical vs. conservative treatment. [Article in German]. *Aktuelle Urol* 2003;34:33–6.
  22. Ouellette L, Hamati M, Hawkins D, Bush C, Emery M, Jones J. Penile fracture: Surgical vs. conservative treatment. *Am J Emerg Med* 2019;37:366–7. [CrossRef]

## ORIJİNAL ÇALIŞMA - ÖZET

### Erken cerrahi onarım mı konservatif tedavi mi? Penil fraktürlü hastaların uzun dönem seksüel fonksiyonlar bakımından karşılaştırılması

**Dr. Kubilay Sarıkaya, Dr. Çağrı Şenocak, Dr. Fahri Erkan Sadioğlu, Dr. Ömer Faruk Bozkurt, Dr. Mehmet Çiftçi**

Sağlık Bilimleri Üniversitesi, Keçiören Eğitim ve Araştırma Hastanesi, Üroloji Kliniği, Ankara

**AMAÇ:** Ürolojik acil olgulardan olan penil fraktürde erken dönem cerrahi onarım yapılan hastalarla konservatif tedaviyle iyileşen hastaları uzun dönemde cinsel fonksiyonlar bakımından karşılaştırmak.

**GEREÇ VE YÖNTEM:** Kliniğimize Ocak 2010 ile Ocak 2020 tarihleri arasında penil fraktür nedeniyle başvuran toplam 42 hastanın verileri geriye dönük olarak incelendi. Hastalar erken dönemde ameliyat edilenler ve konservatif olarak takip edilenler olarak iki gruba ayrıldı. Hastaların ameliyat öncesi ve sonrası bulguları ile uzun dönem takipte Uluslararası Eretil Fonksiyon Ölçeği (IIEF-6) skorları karşılaştırıldı.

**BULGULAR:** Hastaların median yaşı 35 (20–65) yıl ve median takip süreleri 52 (8–120) aydı. Hastaların ameliyat sonrası ortalama IIEF-6 skoru  $22.98 \pm 6.52$  bulundu. Ameliyat sonrası komplikasyon varlığı açısından cerrahi yapılan grupla konservatif izlenen grup arasında anlamlı fark bulunmadı ( $p=0.460$ ). Uzun dönem takipte rüptür alanında palpe edilen plak varlığı konservatif tedavi grubunda anlamlı olarak yüksek bulundu ( $p=0.041$ ). Ancak IIEF-6 skorları bakımından gruplar arasında anlamlı fark olmadığı görüldü ( $p=0.085$ ).

**TARTIŞMA:** Penil fraktür hastalarında erken cerrahi yapılanlarla, konservatif izlem yapılanlar arasında uzun dönemde IIEF-6 skorları bakımından anlamlı fark yoktur. Ancak konservatif takip edilen hastalarda peniste plak oluşum oranı daha yüksektir. Bu nedenle özellikle rüptür alanı büyük hastalarda acil cerrahi onarım ön planda düşünülmelidir.

**Anahtar sözcükler:** Konservatif tedavi; penil fraktür; seksüel fonksiyonlar.

*Ulus Travma Acil Cerrahi Derg* 2021;27(2):249-254 doi: 10.14744/tjtes.2021.92662