

# Life-threatening hematomas in COVID-19 patients

Ümit Alakuş, M.D.,<sup>1</sup> Umut Kara, M.D.,<sup>2</sup> Şebnem Çimen, M.D.,<sup>1</sup>

Cantürk Taşçı, M.D.,<sup>3</sup> Mehmet Eryılmaz, M.D.<sup>1</sup>

<sup>1</sup>Department of General Surgery, University of Health Sciences, Gülhane Training and Research Hospital, Ankara-Turkey

<sup>2</sup>Department of Anesthesiology and Reanimation, University of Health Sciences, Gülhane Training and Research Hospital, Ankara-Turkey

<sup>3</sup>Department of Pulmonology, University of Health Sciences, Gülhane Training and Research Hospital, Ankara-Turkey

## ABSTRACT

**BACKGROUND:** The COVID-19 pandemic has caused over 1.75 million deaths in the world to date. Although the leading cause of mortality is respiratory disorders and thromboembolic pathologies, other rare pathologies may also increase mortality and morbidity. In our study, we aimed to examine life-threatening hematomas, risk factors, and management during COVID-19.

**METHODS:** Institutional center (a third level pandemic center) database was searched for patients hospitalized for COVID-19 during 10 months period between March 11, 2020, and December 17, 2020, retrospectively. Patients with bleeding symptoms/signs were detected. Patients with gastrointestinal system bleeding were excluded from the study. Patients with hematomas were included in the study.

**RESULTS:** Eleven of a total 5484 patients had hematomas (0.2%). Median age was 76 (min–max: 56–90). Seven (63.6%) patients were male and 4 (36.4%) were female. All patients had at least one comorbidities, been under treatment dose of low-molecular-weight heparin (LMWH) and severe or critical COVID-19 disease. Seven retroperitoneal hematomas, two rectus sheath hematomas, one breast hematoma, and in one patient both retroperitoneal and breast hematomas were diagnosed. Angiographic arterial embolization was applied to 5 (45.5%) patients. Overall mortality rate in patients with bleeding complications was 54.5% (n=6), and the male-to-female ratio was 66.7% (n=4) versus 33.3% (n=2).

**CONCLUSION:** Hematomas are rare, but mortality increasing phenomena in COVID-19 patients. Age, male gender, severe or critical COVID-19 disease, comorbidities, and treatment dose of LMWH may be risk factors. New onset of abdominal/back pain and ecchymotic skin lesions may be signs of bleeding in this patient group. Mortality can be reduced by early diagnosis of hematoma and interventional methods.

**Keywords:** Bleeding; COVID-19; hematoma.

## INTRODUCTION

Fever and respiratory symptoms are prominent in COVID-19 disease. It has also effects on many systems such as gastrointestinal, neurological, genitourinary, and hematological systems. While the majority of critically ill patients with COVID-19 have isolated respiratory failure, often acute respiratory distress syndrome (ARDS) and multiple organ dysfunctions occur in 20–30% of patients with critical illness and more often in fatal cases.<sup>[1]</sup> Although there are only a few published pathologic reports of patients with COVID-19, histopathology of lung specimens from patients with early disease shows char-

acteristic findings of ARDS and evidence of small-vessel occlusion.<sup>[2,3]</sup> Laboratory and imaging studies found an increased risk of thrombotic complications in patients with COVID infection. Xu et al.<sup>[4]</sup> identified a total of 16.67% of mostly critically ill patients with a high risk for thrombotic events, of which 17.3% were diagnosed with deep vein thrombosis. Patients with COVID-19 pneumonia also have a high risk of PE in small branches of pulmonary arteries and arterial thrombosis.<sup>[5,6]</sup> As thrombotic events have been shown in many studies, low-molecular-weight heparin (LMWH) prophylaxis and its early initiation have been recommended and accepted.<sup>[7]</sup> The recommended dose of LMWH is still controversial, but it has

Cite this article as: Alakuş Ü, Kara U, Çimen Ş, Taşçı C, Eryılmaz M. Life-threatening hematomas in COVID-19 patients. *Ulus Travma Acil Cerrahi Derg* 2022;28:477-482.

Address for correspondence: Ümit Alakuş, M.D.

Sağlık Bilimleri Üniversitesi, Gülhane Eğitim ve Araştırma Hastanesi, Genel Cerrahi Kliniği, Ankara, Turkey

Tel: +90 312 - 304 51 19 E-mail: umitalakus@yahoo.com

*Ulus Travma Acil Cerrahi Derg* 2022;28(4):477-482 DOI: 10.14744/tjtes.2021.92335 Submitted: 02.01.2021 Accepted: 04.03.2021

Copyright 2022 Turkish Association of Trauma and Emergency Surgery



become a standard in COVID-19 treatment. However, during the COVID-19 treatment process, various life-threatening bleeding is also observed. Although the majority of bleeding in COVID-19 patients is seen in the gastrointestinal system, body compartments bleeding with less frequent has also started to be included in the literature as case reports. Scialpi et al.<sup>[8]</sup> had reported the first retroperitoneal hematoma during COVID-19 treatment. Guo et al.<sup>[9]</sup> had reported giant retroperitoneal hematoma during extracorporeal membrane oxygenation (ECMO) in a patient with COVID-19 pneumonia. Bakirov et al.<sup>[10]</sup> described left inferior epigastric artery injury in a COVID-19 patient. Patel et al.<sup>[11]</sup> reported a life-threatening psoas hematoma due to retroperitoneal hemorrhage in a COVID-19 patient on LMWH treated with arterial embolization. Dou and Patel<sup>[12]</sup> found a new palpable breast mass without skin changes in a COVID-19 patient, they performed an aspiration from the mass and reported the case as a hematoma. We have also seen hematomas during COVID-19 treatment in our center. We aimed to evaluate the risk factors, key points to diagnose earlier, and management of less frequent seen bleedings in this study.

## MATERIALS AND METHODS

This retrospective study was conducted at Gülhane Training and Research Hospital after obtaining approval from the Ministry of Health of Turkey (December 15, 2020/13\_18\_18) and Institutional Review Board (2020/Number). Verbal and written consent for the use of the data was obtained from all patients. Patient consent was also obtained for the photograph used.

Institutional database was searched for patients hospitalized for COVID-19 during 10 months period between the day of first COVID-19 case on March 11, 2020, and December 17, 2020, retrospectively. Patients with bleeding symptoms/signs were detected and who had gastrointestinal bleeding were excluded from the study. Patients with hematomas were included in the study.

Demographic and clinical data along with the laboratory parameters of the study subjects were retracted from institutional database. From data, age, gender, comorbidities, coagulation parameters, d-dimer levels, bleeding site, LMWH or other antiagregant-anticoagulant medication, day of treatment before bleeding, transfusion amounts, diagnostic radiological technique and arterial embolization treatment, and length of hospital stay were used in the statistical analysis.

The study was carried out in accordance with the Code of Ethic of the World Medical Association (Declaration of Helsinki) and followed the strengthening the reporting of observational studies in epidemiology (STROBE) guidelines.

## Interventional Technique

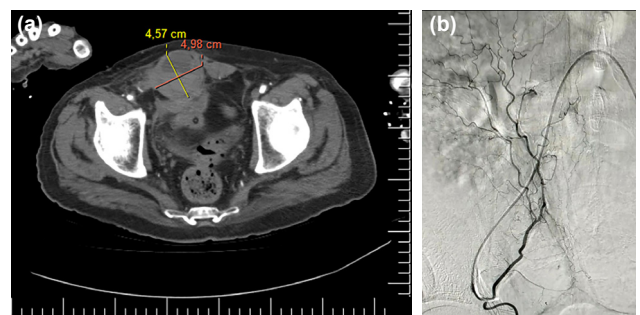
Angiographic arterial embolization was used as an invasive

method in bleeding. Femoral artery was used for catheterization. For rectus sheath hematomas (Fig. 1), the epigastric artery was selectively catheterized and embolization was applied to the inferior epigastric artery. For retroperitoneal hematoma (Fig. 2), lumbar arteries were selectively catheterized and embolization was applied to bleeding branches.

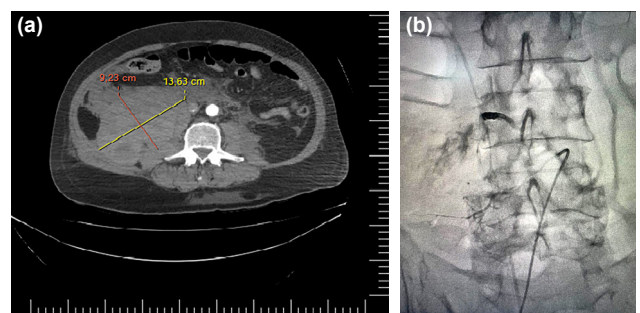
Categorical data were expressed as number (percentage) and continuous data as median (minimum–maximum).

## RESULTS

A total of 5484 patients had hospitalized because of COVID-19 disease. Gastrointestinal system bleeding or hematomas were observed in 56 (1%) of them during hospitalization. Hematoma rate was 19% (11 of 56 patients) of all bleeding and these patients were included in the study. Seven (63.6%) of these patients were male and 4 (36.4%) were female. Median age and body mass index were 76 (min–max: 56–90) and 27.5 kg/m<sup>2</sup> (min–max: 21.60–32.70), respectively. Patients demographic and clinical features are given in Table 1. All of patients had severe (n=3, 27.2%) or critical (n=8; 72.3%) disease according to the World Health Organization COVID-19 disease severity classification.<sup>[13]</sup> and were having treatment dose of LMWH<sup>[14]</sup> and four of them were in intensive care unit (ICU) at the time of bleeding (two patients transferred to ICU after bleeding). LMWH doses were planned according to the Turkish Health Ministry COVID-19 Treatment Guide.<sup>[15]</sup> All of the patients



**Figure 1.** (a) Computed tomography angiography of the right rectus sheath hematoma. (b) Extra illumination seen in angiography, before embolization, same case.



**Figure 2.** (a) Computed tomography angiography of the right retroperitoneal hematoma. (b) Extra illumination from lumbar arteries before embolization, same case.

were required treatment dose of LMWH according to the guide, considering their disease severity and D-dimer levels. LMWH was started to be used with the hospitalization of the patients. It was stopped to be used with bleeding until the bleeding has stopped and the patient was hemodynamically stabilized. All of patients had at least one comorbidity such as diabetes mellitus (DM), coronary artery disease (CAD), chronic obstructive pulmonary disease, chronic renal failure, chronic heart failure, lung cancer, renal cell cancer, chronic myeloid leukemia, and previous cerebrovascular event. Five patients were already using antiaggregant before COVID-19.

Table 2 demonstrates laboratory results of cases at administration time and minimum or maximum levels during bleeding. PTZ/INR, aPTT, and platelet counting were in the normal range for all patients at the admission (Table 2). PTZ, INR, and aPTT levels increased with bleeding, their maximum median levels were 18.3 s (min-max: 11.60–41.50), 1.61 (min-max: 1.11–3.78), and 41.3 s (min-max: 24.90–49.20), respectively. Platelet median level decreased to  $138,000 \times 10^3$  cells/UI (min-max: 35.00–176.00) during bleeding. Admission median hemoglobin and hematocrit levels were 12.7 g/dL (min-max: 7.60–17.40) and 36.2% (min-max: 23.50–52.50), and decreased to 6.5 g/dL (min-max: 1.70–12.50), respectively. Median d-dimer and fibrinogen levels were 1.42 mg/dL (min-max: 0.28–91.00) and 600 mg/dL (min-max: 169.00–900.00) and increased to 12.64 mg/dL (min-max: 0.95–80.00) and 654 mg/dL (min-max: 312.00–900.00), respectively.

Median length of stay before bleeding was 8 days (min-max: 4–26). Median systolic blood pressure at the time of bleeding mean was 94 mmHg (min-max: 74–120).

Back pain, ecchymosis, hypotension, and abdominal pain were the prior symptom and sign during bleeding (Table 1). Asymptomatic one patient was suspected of bleeding because of decreasing hemoglobin, and retroperitoneal hematoma diagnosed. Differential diagnosis of patients revealed seven retroperitoneal hematomas, two rectus sheath hematomas, one breast hematoma, and in one patient both retroperitoneal and breast hematomas. Mobile ultrasound was used for diagnose in five patients and computed tomography angiography for the other six patients. Median number of erythrocyte suspension replacement and fresh frozen plasma was 5 units (min-max: 0.00–17.00) and 2 units (min-max: 0.00–10.00), respectively. Interventional radiological treatment (angi-embolization) was applied to 5 (45.5%) of 11 patients with bleeding complications (three retroperitoneal hematomas and two rectus sheath hematomas).

Median length of hospital stay was 16 days (min-max: 8.00–31.00). Overall mortality rate in patients with bleeding complications was 54.5% (n=6 patients), and the male-to-female ratio was 66.7% (n=4) versus 33.3% (n=2). Mortality rate was 40% (n=2) in patients who received interventional

**Table 1.** Case series of 11 patients with COVID-19 and non-gastrointestinal bleeding

Patients	Age	Gender	BMI	Chronic anticoagulant	Oxygen therapy treatment	Day of LMWH	Bleeding symptom/sign	Bleeding site	Unit of ES	Arterial embolization	Mortality
1	85	Male	24.2	Non	Reservoir mask	9	Hypotension	Retroperitoneum	11	No	Ex
2	66	Female	27.5	ASA	Nasal cannula	8	Abdominal pain	Rectus sheath hematoma	2	Yes	Alive
3	79	Female	31.2	Non	Nasal cannula	5	Ecchymosis	Breast	0	No	Alive
4	77	Male	29.4	Non	Reservoir mask	19	Back pain	Retroperitoneum	9	Yes	Ex
5	75	Male	27.7	ASA	HFNO	28	Hypotension	Retroperitoneum	3	No	Ex
6	56	Male	24.2	Non	HFNO	15	Decreased hemoglobin	Retroperitoneum	2	No	Alive
7	76	Male	24.2	Non	Nasal cannula	13	Abdominal pain	Retroperitoneum	17	Yes	Ex
8	90	Female	32.7	Non	Reservoir mask	9	Ecchymosis	Breast + Retroperitoneum	5	No	Ex
9	88	Female	30.1	Clopidogrel	HFNO	12	Ecchymosis	Retroperitoneum	5	No	Ex
10	72	Male	21.6	ASA	HFNO	24	Back pain	Retroperitoneum	6	Yes	Alive
11	69	Male	24.2	ASA + Clopidogrel	HFNO	27	Ecchymosis	Rectus sheath hematoma	0	Yes	Alive

LMWH: Low molecular weight heparin; ASA: Acetylsalicylic acid; HFNO: High frequency nasal oxygen; ES: Erythrocyte suspension.

**Table 2.** Laboratory results of cases

Patients	Admission Hgb/Min Hgb g/dL	Admission Hct/Min Hct %	Admission Plt/Min Plt x10 <sup>3</sup> cells/uL	Admission Ptz/Max Ptz second	Admission INR/Max INR	Admission APTT/Max APTT second	Admission D-Dimer/Max D-Dimer mg/L	Admission Fibrinogen/Max Fibrinogen mg/dL
1	9.3/5.3	29.3/17.9	110/35	18.8/41.5	1.65/3.78	18.8/47.4	4.25 /6.9	627 /627
2	9.3/5	27.7/15	162/152	12/13.7	1.05/1.20	35/41.3	10.88 /51.93	652/652
3	17.4/12.5	52.5/37.2	403/176	12/14.1	1.01/1.20	22.5/24.9	0.48/ 0.95	169/312
4	12.9/6.5	37.4/19.5	78/51	12.2/41	1.03/3.66	20.3/44.3	1.58/12.64	487/802
5	14.4/6.6	39.9/19.4	165/140	13.7/24.2	1.17/2.17	32.5/37.8	0.28/80	479/479
6	12.7/8.4	36.2/23.6	129/129	13.3/13.8	1.16/1.20	29.5/35.5	1.31/2.89	900/900
7	7.6/1.7	23.5/4.8	167/53	17.5/19.6	1.53/1.72	46.1/46.1	25.78/80	314/314
8	13.2/5.3	37.9/15.4	240/140	11.6/11.6	0.97/1.28	25.4/29.2	1.42 /1.42	654/654
9	12.2/6.6	35.2/19.4	205/146	18.3/18.3	1.61/1.61	43.6/43.6	0.99/ 9.41	434/893
10	14.8/4.1	44.6/12.5	198/71	16.3/25.6	1.43/2.26	28.3/49.2	1.41/30.47	900/900
11	10.2/8.5	31.1/26.1	188/138	11.5/12.7	1/1.11	28.8/28.8	0.91/ 33.75	600/678

Hgb: Hemoglobin; Hct: Hematocrit; Plt: Platelet; Ptz: Prothrombin time; INR: International normalization rate.

**Table 3.** Laboratory and clinical futures of patients according to mortality

	Mortality	Median	Min	Max
Age	No	69	56	79
	Ex	81	75	90
BMI	No	24.2	21.6	31.2
	Ex	28.55	24.2	32.7
Admission D-Dimer mg/dL	No	1.41	0.48	10.88
	Ex	1.5	0.28	25.78
Maximum PTZ	No	13.8	12.7	25.6
	Ex	21.9	11.6	41.5
Maximum INR	No	1.2	1.11	2.26
	Ex	1.28	1.94	3.78
Length of hospital stay to the bleeding day	No	6	4	20
	Ex	8.5	6	26
Replaced ES units	No	2	0	6
	Ex	7	3	17
Replaced FFP units	No	0	0	4
	Ex	4.5	0	10

FFP: Fresh frozen plasma; BMI: Body mass index; ES: Erythrocyte suspension; Min: Minimum; Max: Maximum.

treatment and 66.7% (n=4) in those who did not. Mortality rate was 75% (six of eight) in patients with retroperitoneal bleeding. No mortality was observed in isolated breast and rectus sheath bleeding. Median d-dimer level was 1.5 mg/dL (min-max: 0.28–25.78) in patients with mortality and 1.31 (min-max: 0.48–10.88) in patients without mortality (Table 3).

## DISCUSSION

The COVID-19 pandemic has caused over 1.75 million deaths in the world to date. Although the leading cause of mortality is respiratory disorders and thromboembolic pathologies, other rare pathologies may also increase mortality and morbidity. Spontaneous bleeding to potential gaps is one of these phenomena. The disease and the anticoagulant treatment may induce the bleeding.

The most common cause of retroperitoneal hematomas are trauma- and anticoagulant-induced hematomas. It is classified according to the retroperitoneal zones it develops, and its management is accepted by conservative or surgical methods if required.<sup>[16]</sup> In addition, with the widespread use of interventional radiology, angioembolization has increasingly replaced surgery.<sup>[17]</sup> Despite this development, it should always be kept in mind that the surgical option can provide not only the prevention of bleeding but also the treatment of an abdominal compartment syndrome that may develop due to a retroperitoneal hematoma. In our study, none of the patients had abdominal compartment syndrome.<sup>[18]</sup> Scialpi et al.<sup>[8]</sup> described the first retroperitoneal hematoma related COVID-19, in a 57-year-old man with a history of non-Hodgkin lymphoma, treated with autologous cell transplantation 1 year ago and later diagnosed with COVID-19 infection at nasopharyngeal swab sample. The patient was having therapeutic dose of LMWH. Guo et al.<sup>[9]</sup> reported a giant retroperitoneal hematoma in a 71-year-old man who was admitted to the ICU because of severe bilateral pneumonia. The patient was heparinized and had ECMO treatment. Patel et al.<sup>[11]</sup> reported a 69-year-old man with a medical history of CAD on aspirin daily, hypertension, and type 2 DM. The patient was having prophylactic dose of LMWH. Scialpi, Guo,

and Patel used CT for diagnose and arterial embolization for treatment. In our study, the patients were at an elderly age and had at least one comorbidity. The male-to-female ratio was high. They were all severe or critical COVID-19 patients, all of whom received oxygen therapy and they were using therapeutic doses of LMWH and five patients were also using ASA or clopidogrel daily. The earliest bleeding occurred on the 4th day of treatment in our study. Eight patients had retroperitoneal hematoma, bedside ultrasound was used for diagnose because of patients were unstable to transport. Other four were diagnosed with CT. Bedside ultrasound may be used hemodynamically unstable patients for diagnose. Arterial embolization was used in three patients in our study.

Rupture of the epigastric vessels was reported to be associated with abdominal wall hematomas. In a study of spontaneous hematomas of the rectus abdominis muscle, the mean patient age was 59 years; the most common symptom was abdominal pain (100%); 93% had an abdominal mass, and 38% had peritoneal irritation findings. Moreover, the most common precipitating factor was found to be cough in 56%.<sup>[19]</sup> As the patient's bruising and pain were followed by a cough episode, it appeared that abdominal wall hematoma was caused by vigorous contraction of the rectus muscle. Management of abdominal wall hemorrhages may be conservative<sup>[20]</sup> or interventional radiological angioembolization may be an effective option, if required.<sup>[17]</sup> Bakirov et al. reported a 75-year-old male COVID-19 patient having therapeutic dose of LMWH with inferior epigastric arteria bleeding. The patient undergone arterial embolization. In our study, two rectus sheath hematoma, both treated by arterial embolization.

Duo et al. reported a breast hematoma in a 67-year-old woman with new palpable breast mass in a COVID-19 patient. She was hemodynamically unstable. The patient recovered with conservative treatment. In our study, two breast hematomas observed, one also had retroperitoneal large hematoma and mortality occurred. Other hematoma resolved by conservative treatment. Breast hematomas may not require invasive treatment, but another accompanying focus, such as retroperitoneal bleeding, may be the cause of mortality.

In our study, mortality developed in patients with retroperitoneal hemorrhage requiring relatively more transfusion. It can be thought that this may be due to transfusion reactions added to pulmonary dysfunction due to COVID-19 or even that develop secondary to massive transfusion reactions in some patients.<sup>[21]</sup> Unfortunately, there is not enough number of patients to reveal this clearly due to limiting factors of the study. The relative rarity of hematomas was the most important limiting factor of our study. The retrospective nature of the study was considered as another important limiting factor.

## Conclusion

With utilization of anticoagulation regimens to treat the associated COVID-19 hypercoagulable state, hematomas are important and life-threatening diagnostic considerations when evaluating patients with COVID-19. Age, male gender, severe or higher level COVID-19 disease, elevated d-dimer at hospital admission, comorbidities and antiagregant daily usage, and therapeutic dose of LMWH should be risk factors. New-onset abdominal/back pain and ecchymotic skin lesions may be signs of bleeding in this group of patients. Mortality can be reduced with early diagnosis and interventional methods. We think that higher case numbers can be reached and risk factors can be analyzed better with multicenter studies.

**Ethics Committee Approval:** This study was approved by the Gülhane Scientific Research Ethics Committee (Date: 15.11.2020, Decision No: 13\_18\_18).

**Peer-review:** Internally peer-reviewed.

**Authorship Contributions:** Concept: Ü.A., U.K., Ş.Ç., C.T., M.E.; Design: Ü.A., U.K., Ş.Ç., C.T., M.E.; Supervision: C.T., M.E.; Resource: Ü.A., U.K., Ş.Ç., C.T., M.E.; Materials: Ü.A., U.K., Ş.Ç., C.T., M.E.; Data: Ü.A., U.K., Ş.Ç., C.T., M.E.; Analysis: Ü.A., U.K., Ş.Ç.; Literature search: Ü.A., U.K., C.T., M.E.; Writing: Ü.A., U.K., Ş.Ç., C.T., M.E.; Critical revision: Ü.A., U.K., Ş.Ç., C.T., M.E.

**Conflict of Interest:** None declared.

**Financial Disclosure:** The authors declared that this study has received no financial support.

## REFERENCES

1. Yang X, Yu Y, Xu J, Shu H, Xia J, Liu H, et al. Clinical course and outcomes of critically ill patients with SARS-CoV-2 pneumonia in Wuhan, China: A single-centered, retrospective, observational study. *Lancet Respir Med* 2020;8:475–81. [CrossRef]
2. Tian S, Hu W, Niu L, Liu H, Xu H, Xiao SY. Pulmonary Pathology of early-phase 2019 novel coronavirus (COVID-19) pneumonia in two patients with lung cancer. *J Thorac Oncol*. 2020;15:700–4. [CrossRef]
3. Xu Z, Shi L, Wang Y, Zhang J, Huang L, Zhang C, et al. Pathological findings of COVID-19 associated with acute respiratory distress syndrome. *Lancet Respir Med* 2020;8:420–2. [CrossRef]
4. Xu JF, Wang L, Zhao L, Li F, Liu J, Zhang L, et al. Risk Assessment of Venous Thromboembolism and Bleeding in COVID-19 Patients; 2020.
5. Chen J, Wang X, Zhang S, Liu B, Wu X, Wang Y, et al. Findings of acute pulmonary embolism in COVID-19 patients. *SSRN Electron J* 2020.
6. Zhang Y, Xiao M, Zhang S, Xia P, Cao W, Jiang W et al. Coagulopathy and antiphospholipid antibodies in patients with Covid-19. *N Engl J Med* 2020;382:e38. [CrossRef]
7. Miesbach W, Makris M. COVID-19: Coagulopathy, risk of thrombosis, and the rationale for anticoagulation. *Clin Appl Thromb Hemost* 2020;26:1076029620938149. [CrossRef]
8. Scialpi M, Russo P, Piane E, Gallo E, Scalera GB. First case of retroperitoneal hematoma in COVID-19. *Turk J Urol* 2020;46:407–9. [CrossRef]
9. Guo SH, Zhu SM, Yao YX. Giant retroperitoneal hematoma during extracorporeal membrane oxygenation in a patient with coronavirus disease-2019 pneumonia. *J Cardiothorac Vasc Anesth* 2020;34:2839–40.

10. Bakirov I, Bakirova G, Albalawi Y, Asiri AY, Faqih F, Bakirli I, et al. Left inferior epigastric artery injury in COVID-19 patient. Case report and literature review. *Int J Surg Case Rep* 2020;76:415–20. [CrossRef]
11. Patel I, Akoluk A, Douedi S, Upadhyaya V, Mazahir U, Costanzo E, et al. Life-threatening psoas hematoma due to retroperitoneal hemorrhage in a COVID-19 patient on enoxaparin treated with arterial embolization: A case report. *J Clin Med Res* 2020;12:458–61. [CrossRef]
12. Dou E, Patel H. New palpable breast mass in a COVID-19 patient. *J Breast Imaging* 2020;2:513–4. [CrossRef]
13. World Health Organization. Clinical Management of COVID-19: Interim Guidance, 27 May 2020. Geneva: World Health Organization; 2020.
14. Bakanlıđı TS. COVID-19 (Sars-CoV2 Enfeksiyonu) Rehberi; 2020.
15. Müdürlüğü TCSBHSG. COVID-19 (SARS-CoV-2 Enfeksiyonu) An-tisitokin-Antiinflamatuvar Tedaviler, Koagülopati Yönetimi; 2020. Available from: <https://covid19.saglik.gov.tr/Eklenti/39296/0/covid-19rehberiantisitokin-antiinflamatuvar tedavilerkoagulopatiyonetimipdf.pdf>
16. Altun H, Sarı S, Aydın İ, Karahan İ, Akdağ M, Alimođlu O. Retroperitoneal hematomas. *Ulus Travma Acil Cerrahi Derg* 1996;2:173–9.
17. Çolakođlu MK, Özdemir A, Kalcan S, Demir A, Demiral G, Pergel A. Spontaneous abdomen and abdominal wall hematomas due to anticoagulant/antiplatelet use: Surgeons' perspective in a single center. *Ulus Travma Acil Cerrahi Derg* 2020;26:50–4. [CrossRef]
18. Abu-zidan FM, Jawas A, Boraie M, Ahmed MU. Delayed retroperitoneal bleeding causing acute abdominal compartment syndrome: Case report. *Ulus Travma Acil Cerrahi Derg* 2011;17:183–5. [CrossRef]
19. Stanton PE, Jr., Wilson JP, Lamis PA, Letton AH. Acute abdominal conditions induced by anticoagulant therapy. *Am Surg* 1974;40:1–14.
20. Ergün N, Çevik AA, Holliman CJ, Manısalı M, İnan F, Sarısoy T. Conservative treatment of giant abdominal wall hematoma. *Ulus Travma Acil Cerrahi Derg* 2004;10:141–4.
21. Sihler KC, Napolitano LM. Complications of massive transfusion. *Chest* 2010;137:209–20. [CrossRef]

## ORİJİNAL ÇALIŞMA - ÖZ

### Covid-19 hastalarında hayatı tehdit eden hematomlar

Dr. Ümit Alakuş,<sup>1</sup> Dr. Umut Kara,<sup>2</sup> Dr. Şebnem Çimen,<sup>1</sup> Dr. Cantürk Taşçı,<sup>3</sup> Dr. Mehmet Eryılmaz<sup>1</sup>

<sup>1</sup>Sağlık Bilimleri Üniversitesi, Gülhane Eğitim ve Araştırma Hastanesi, Genel Cerrahi Kliniđi, Ankara

<sup>2</sup>Sağlık Bilimleri Üniversitesi, Gülhane Eğitim ve Araştırma Hastanesi, Anesteziyoloji ve Reanimasyon Kliniđi, Ankara

<sup>3</sup>Sağlık Bilimleri Üniversitesi, Gülhane Eğitim ve Araştırma Hastanesi, Göğüs Hastalıkları Kliniđi, Ankara

**AMAÇ:** Covid-19 salgını bugüne kadar dünyada 1.75 milyondan fazla ölüme neden oldu. Mortalitenin önde gelen nedenleri solunum bozuklukları ve tromboembolik patolojiler olmakla birlikte, diđer nadir patolojiler de mortalite ve morbiditeyi artırabilir. Çalışmamızda Covid-19 hastalarında hayatı tehdit eden hematomları, risk faktörlerini ve yönetimini incelemeyi amaçladık.

**GEREÇ VE YÖNTEM:** Kurumsal merkez (üçüncü düzey pandemi merkezi) veri tabanında, 11 Mart 2020 ve 17 Aralık 2020 tarihleri arasındaki 10 aylık dönemde Covid-19 nedeniyle hastaneye yatırılan hastaların verileri geriye dönük olarak tarandı. Kanama semptomları/bulguları olan hastalar tespit edildi. Gastrointestinal sistem kanaması olan hastalar çalışma dışı bırakıldı. Hematom tespit edilen hastalar dahil edildi.

**BULGULAR:** Toplam 5484 hastanın 11'inde hematom vardı (%0.2). Medyan yaş 76 idi (min-maks: 56–90). Hastaların yedisi (%63.6) erkek, dördü (%36.4) kadındı. Tüm hastaların en az bir komorbiditesi vardı, tüm hastaların ciddi veya kritik Covid-19 hastalığı vardı ve tamamı tedavi dozunda düşük moleküler ağırlıklı heparin kullanıyordu. Yedi retroperitoneal hematoma, iki rektus kılıf hematomu, bir meme hematomu ve bir hastada meme ve retroperitoneal hematoma birlikte saptandı. Beş (%45.5) hastaya anjiyografik arteriyel embolizasyon uygulandı. Kanama komplikasyonları olan hastalarda genel mortalite oranı %54.5 (n=6) ve erkek/kadın oranı %66.7 (n=4) ve %33.3 (n=2) idi.

**TARTIŞMA:** Hematomlar nadir, ancak Covid-19 hastalarında mortaliteyi artıran fenomenlerdir. Yaş, erkek cinsiyet, şiddetli veya kritik düzeyde Covid-19 hastalığı, komorbiditeler, tedavi dozu düşük moleküler ağırlıklı heparin risk faktörleri olabilir. Yeni başlayan karın/sırt ağrısı ve ekimotik deri lezyonları bu hasta grubunda kanama belirtileri olabilir. Hematomun erken teşhisi ve girişimsel yöntemlerin kullanılması ile mortalite azaltılabilir.

**Anahtar sözcükler:** Covid-19; hematoma; kanama.

*Ulus Travma Acil Cerrahi Derg* 2022;28(4):477-482 doi: 10.14744/ıttes.2021.92335