

# Renal autotransplantation due to iatrogenic ureter injury: A case report

Şahin Kaymak, M.D.,<sup>1</sup> Mustafa Tahir Özer, M.D.,<sup>1\*</sup> Sezai Demirbas, M.D.,<sup>2</sup>  
Engin Kaya, M.D.,<sup>3</sup> Orhan Kozak, M.D.<sup>1</sup>

<sup>1</sup>Department of General Surgery, Health Sciences University, Gülhane Faculty of Medicine, Ankara-Turkey

<sup>2</sup>Department of General Surgery, TOBB ETÜ Faculty of Medicine Hospital, Ankara-Turkey

<sup>3</sup>Department of Urology, Health Sciences University, Gülhane Faculty of Medicine, Ankara-Turkey

## ABSTRACT

Hardy and colleagues carried out “Renal autotransplantation” for the first time in 1963 to treat severe ureter injury and it has evolved as a method used for complex treatment of trauma, renal artery diseases or ureteral stenosis. In case of proximal ureter injury, approximately 2/3 of which is iatrogenic, if the end-to-end anastomosis is not possible, renal autotransplantation, ileal ureter interposition or nephrectomy are alternative treatments. As technology advances, the use of ureterorenoscopy (URS) increases and in parallel with this iatrogenic injuries that occur during the process have increased as well. These types of injuries are generally in form of simple perforations (2–6%), but from time to time ureter avulsions are also observed (0.3%). In this article, a case is presented where renal autotransplantation is made following development of ureter avulsion during ureterorenoscopy process carried out due to right ureteral calculi and treatment options are discussed in the light of literatures.

**Keywords:** Iatrogenic; renal autotransplantation; ureter injury.

## INTRODUCTION

Hardy et al.<sup>[1]</sup> performed “Renal autotransplantation” for the first time in 1963 to treat severe ureter injury and it has evolved as a method used for complex treatment of trauma, renal artery diseases or ureteral stenosis. In case of proximal ureter injury, approximately 2/3 of which is iatrogenic, if end-to-end anastomosis is not possible, renal autotransplantation, ileal ureter interposition or nephrectomy are alternative treatments.<sup>[2]</sup>

As technology advances, use of ureterorenoscopy (URS) increases and in parallel with this iatrogenic injuries that occur during the process have increased as well. These types of injuries are generally in form of simple perforations (2–6%). However, from time to time, ureter avulsions are also ob-

served (0.3%). Avulsions generally occur in the ureteropelvic (UP) junction where muscle and mucosa structure is thinner. In case of split, generally primary repair is not performed and one of the surgeries like kidney mobilization and ipsilateral reanostomosis, nephrectomy, ureter mobilization and contralateral ureteroureterostomy, ileal interposition or renal autotransplantation is performed based on age of the patient, level of injury, status of the other kidney and experience of the surgeon.<sup>[1–4]</sup>

In this study, a case is presented where renal autotransplantation is performed following development of ureter avulsion during ureterorenoscopy process performed due to right ureteral calculi and treatment options are discussed in the light of literatures. (A written informed consent was obtained from the patient for publication of this case report.)

Cite this article as: Kaymak Ş, Özer MT, Demirbas S, Kaya E, Kozak O. Renal autotransplantation due to iatrogenic ureter injury: A case report. *Ulus Travma Acil Cerrahi Derg* 2021;27:260-264.

\*Author's new institution: Department of General Surgery, Hitit University Faculty of Medicine, Çorum-Turkey

Address for correspondence: Şahin Kaymak, M.D.

Sağlık Bilimleri Üniversitesi, Gülhane Tıp Fakültesi, Genel Cerrahi Anabilim Dalı, Ankara, Turkey

Tel: +90 312 - 304 61 60 E-mail: sahin Kaymak@hotmail.com

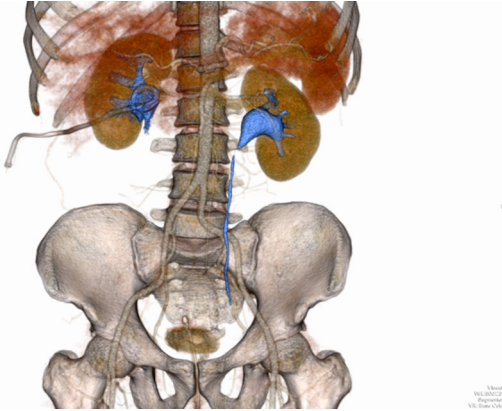
*Ulus Travma Acil Cerrahi Derg* 2021;27(2):260-264 DOI: 10.14744/tjtes.2020.80606 Submitted: 01.03.2020 Accepted: 08.03.2020 Online: 22.02.2021

Copyright 2021 Turkish Association of Trauma and Emergency Surgery



## CASE REPORT

Ureterorenoscopy is performed due to 7 mm calculi in the right ureteropelvic junction, causing acute pain as passing of the calculi was not possible medical treatment carried out. It is understood from the story of the patient that as ureter is observed on ureterorenoscope ureter avulsion is determined and patient was transferred to a larger facility in the city during the same day and percutaneous nephrostomy catheter is placed. Two days later, patient with nephrostomy was transferred to our hospital and as the result of tomography made, it was seen that left kidney was normal and right kidney was Grade 2 hy-

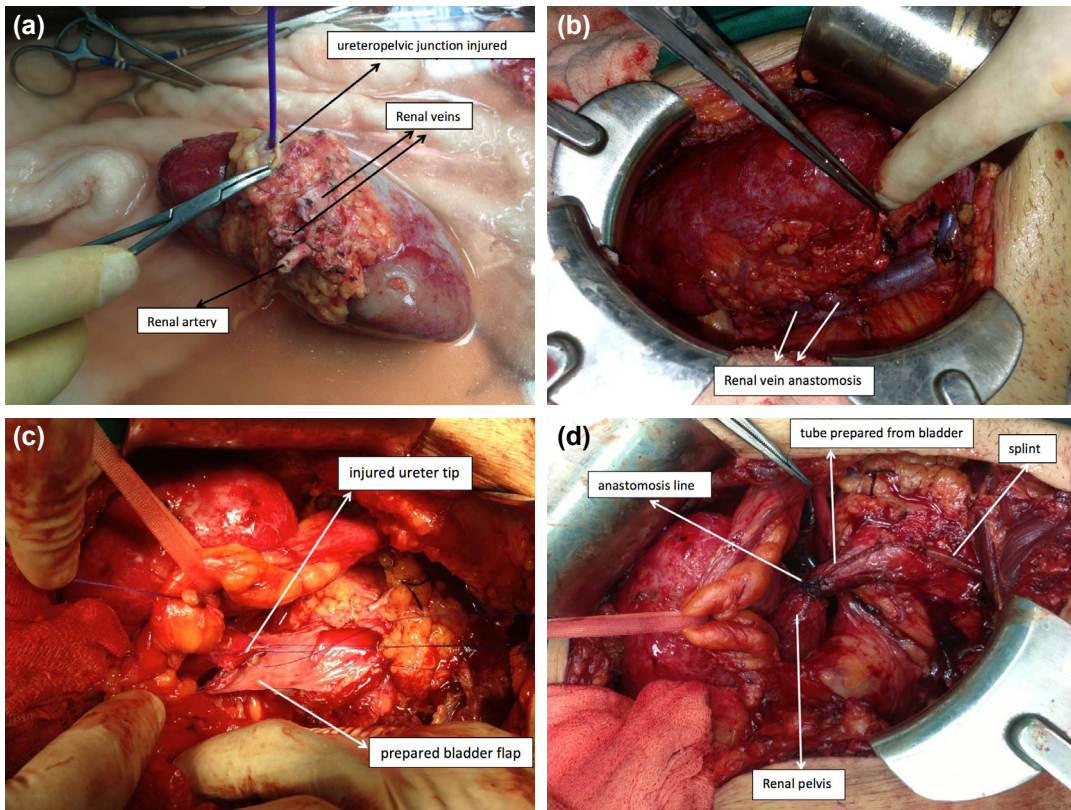


**Figure 1.** The right ureter is not observed immediately after the renal pelvis.

dronephrosis, nephrostomy catheter was seen in consolidated renal pelvis and right ureter was not observed after uretero-pelvic junction. Also, in the right renal pelvis and perirenal fatty tissue, impurity and heterogeneity was observed. Secondary to perirenal fascia infection and inflammation, thickened abscess formation was observed with a size of 5x4 cm, with air densities and contrast enhanced image adjacent to the entry-way of the nephrostomy catheter (Fig. 1). In the kidney to be transplanted, there were double renal artery and vein. Patient's internal and external iliac artery and veins on both sides were normal. As the result of Doppler examination, renal artery and veins and iliac artery and veins were evaluated as normal.

Patient's temperature was 38 C° and antibiotherapy was initiated given that urosepsis was present due to leucocytosis level of 19000/mm<sup>3</sup>, perinephritic infection and inflammation symptoms detected by tomography. Patient responded well to the treatment and infection symptoms regressed and it was decided to perform renal autotransplantation. To perform nephrectomy easily and without damaging the kidney, patients were allowed one month rest together with nephrostomy to allow regression of perirenal inflammation and at the end of the rest period, patient was taken into renal autotransplantation operation.

With the operation, right flank incision was performed and gerota fascia was opened carefully and hilus was reached. It



**Figure 2.** (a) Backtable image of the kidney to be autotransplanted. (b) Renal vein anastomoses. (c) Injured ureter tip and prepared bladder flap. (d) The anastomosis of the tube prepared with the renal pelvis.

was observed that ureter did not develop following renal pelvis and that the end of the renal pelvis is covered with fibrosis inflamed tissue. Renal artery and veins were dissected carefully up to origins. After administering furosemid and mannitol, veins were punctured with satinski forceps and fixations and nephrectomy was performed. While closing the flank incision, the team that will perform the kidney transplantation, perfused and irrigated the kidney with ringer lactate at +4 degrees at "Back Table". Afterwards, artery and veins were prepared for anastomosis. Renal pelvis was explored and it was seen that no ureter was present (Fig. 2a).

Patient, whose flank incision was closed, was turned and left Israel-Bergman incision was made to enter retroperitoneum and patient was prepared for external iliac vein and internal iliac artery anastomosis. Anostomosis is completed with renal veins are end-side and renal artery is end-to-end and when clamps are loosened, circulation and urination started immediately (Fig. 2b). Total cold ischemia period lasted 55 minutes. Since renal pelvis and bladder were away from each other for anastomosis, it was decided to perform anastomosis to the bladder with the help of Boari flap. In an area close to dome of the bladder, a flap of 2x4 cm was lifted from left anterolateral wall (Fig. 2c). Flap was sutured on both sides with the mucosa to be left inside and turned into a tube form and this way a tube of approximately 4 cm was obtained. Anastomosis of this tube was performed together with renal pelvis over 12 F stent and continuity was achieved. Anterior wall bladder where flap was lifted was sutured primarily and bladder was closed (Figs. 2d and 3). Drainage tube was placed and abdomen layers were closed and the operation ended accordingly. In the renal scintigraphy taken on PO day 1, parenchymal distribution of radiopharmaceutical in both kidneys was considered as normal and the findings showed that contribution of left kidney for the total kidney function was 60% and contribution of the transplanted kidney was 40%. No problem was detected in the follow-up of the patient and loj drainage was

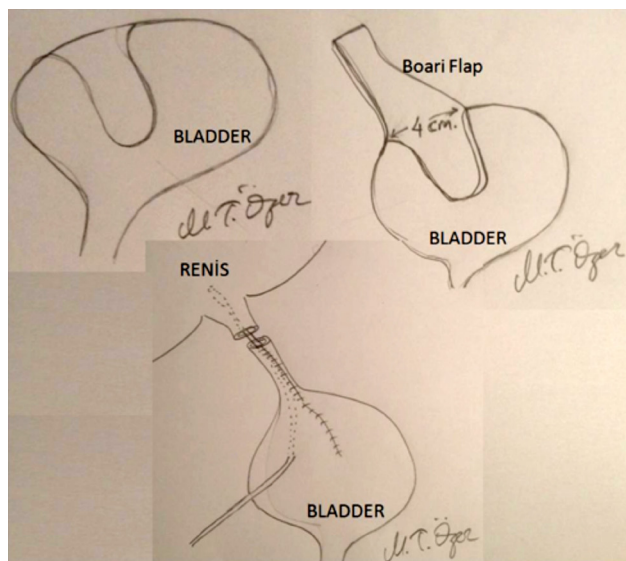


Figure 3. Schematic picture of the Boari flap.

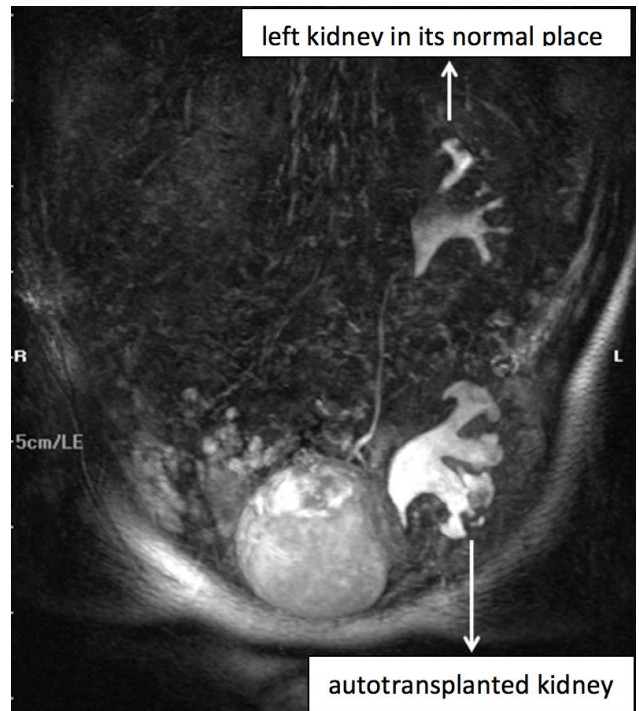


Figure 4. IVP image taken at the 2<sup>nd</sup> postoperative month.

removed on PO day 4 and foley catheter was removed on day 7 and antibiotic administration was stopped on PO day 5. Patient was hospitalized for 11 days in total, with one day in the intensive care unit and then the patient was discharged, with a visit scheduled in two months. In the follow-up at two months, MR urography was performed and filtration function of the transplanted kidney and pelvicalyceal structures were evaluated as normal. In the IVP, both kidneys function in the first five minutes, and it was reported that the transplanted kidney pelvis opens to the bladder with a very short ureter (Boari Flap) (Fig. 4). Patient, whose five years follow-up has ended, has no problems and routine blood tests are within normal limits.

## DISCUSSION

With the advance of minimal invasive techniques, there was an increase in interventions like ureterorenoscopy, and in connection with this, especially proximal ureteral wounds and avulsions started to be seen more frequently. Ureter avulsions are wounds hard to treat even for well-experienced surgeons and they cannot be repaired with ureteroureterostomy. However, they can be treated with complex surgical interventions. In general ileal interposition or autotransplantation methods are used and in some cases, it can go up to nephrectomy.<sup>[1-4]</sup> In fact, it is a very hard decision to lose an organ that fulfills its functions, where only the drainage path is damaged. Thus, methods that protect the kidney are preferred. If tissue loss is not at very proximal and the ureter is present until the center of the bladder on the distance between the bladder and the pelvis, the first transureteroureterostomy is applied. However, these types of injuries arise in

this area as ureteropelvic ureteropelvic junction contains less muscle fiber and mucosa is thinner and this prevents trans-ureteroureterostomy. In such a case, the only options aimed to protect the liver will be nephrostomy, ileal ureter interposition and renal autotransplantation.<sup>[1,3,5]</sup>

Given that a person continues his/her life with nephrostomy will be an extreme loss of comfort and it is extremely difficult since the risk of infection will increase. Like in our case, nephrostomy can be used as a bridge while shifting to other treatment options. In our case, the patient has a nephrostomy, and it allowed us the time to start treatment by way of regression of perirenal infection and inflammation. Afterwards, permanent treatment of the patient was administered.

Ileal interposition is considered as one option and it brings with it risks like urinary tract infections, lithiasis, electrolyte imbalance that causes renewal of interposition surgery.<sup>[6,7]</sup> In this case, the best option is renal autotransplantation, which allows anastomosis between the pelvis and bladder by approaching the kidney to the bladder. This is transplantation, but since the tissue of the patient is used, no immune suppression is required. This way, it is possible to maintain renal functions of the patient without any deterioration. Thus, when compared with other alternatives, this method with less complication is a good treatment option as it will not lead to loss of organ.<sup>[6]</sup> However, from time to time, complications may also arise in this surgery as well. These are complications like urinary incontinence, anastomosis stenosis between pelvis and bladder, hemorrhage and emboli. The most important complication is the risk of vascular thrombosis. Patients who are not chronic renal patients and who are in this status because of trauma since there is no negative impact of uremia caused by chronic renal impairment on thrombocyte functions, more vascular thrombosis is seen in renal autotransplantation patients compared to the ones who were subjected to allotransplantation.<sup>[8]</sup> Thus, our patient was administered low molecule weight heparin in the first week and acetylsalicylic acid in the following eight weeks.

Another problem is since injury damages all ureter starting from the ureteropelvic joint, although we carried the kidney to the iliac fossa, bladder and renal pelvis did not approach enough to perform anastomosis without tension. Literature defines "Psoas Hitch" or "Boari Flap" methods for solving this problem.<sup>[9]</sup> In our case, no ureter is present and it is understood that connecting the bladder with the psoas muscle for anastomosis without tension will not be enough. Thus, Boari Flap method has been preferred to obtain more distance. Tube prepared from the bladder gave us extra 4–5 cms and anastomosis without tension is obtained. For this, anastomotic leakage and decomposition created by anastomosis with tension and complications like stenosis are avoided. Another disadvantage of zero ureter is that anastomosis

of the renal pelvis in the tube is possible only end-to-end. Normally a submucosal tunnel is created in the tube and ureter is passed from there and anastomosis is performed, and accordingly, the objective is to prevent vesicoureteral reflux. However, since there is no ureter in our case, we did not use this method and did only end-to-end anastomosis. Although we were anxious that this will cause infection risk by leading to vesicoureteral reflux, in the two-year follow-up till now, we have not seen any symptoms in this regard.

Another disadvantage of this method is the need for two separate and large incisions for transplant nephrectomy and autotransplantation. However, in parallel with the development of the minimal invasive methods, it is now possible to perform transplant nephrectomy by laparoscopy.<sup>[10]</sup> In this way, it is possible to prevent discomfort and complications caused by at least one of the incisions. However, since our patient has a urepsis history and as perianal abscess and inflammation are observed in tomography, it was considered that laparoscopic approach would be difficult and nephrectomy was performed using the open method.

As a result of solving ureteral complications and especially proximal ureter injuries that increase with the more widespread use of endoscopic urological interventions, renal autotransplantation that allows protecting renal functions for a longer term is a suitable treatment method. However, in deciding the treatment method, we believe that the status of the injury, length of the remaining ureter, possibilities of the facility and experience of the surgeon are very important.

**Informed Consent:** Written informed consent was obtained from the patient for the publication of the case report and the accompanying images.

**Peer-review:** Internally peer-reviewed.

**Authorship Contributions:** Concept: Ş.K., M.T.Ö.; Design: M.T.Ö., Ş.K.; Supervision: M.T.Ö., O.K.; Resource: S.D., Ş.K.; Materials: M.T.Ö., Ş.K.; Data: M.T.Ö., E.K.; Analysis: Ş.K., S.D.; Literature search: Ş.K., E.K.; Writing: Ş.K., M.T.Ö.; Critical revision: S.D., O.K.

**Conflict of Interest:** None declared.

**Financial Disclosure:** The authors declared that this study has received no financial support.

## REFERENCES

1. Hardy JD. High ureteral injuries. Management by autotransplantation of the kidney. *JAMA* 1963;184:97–101. [CrossRef]
2. Kocak B, Ozturk U, Kar A, Ascı R, Sarıkaya S, Buyukapelli R. Auto-transplantation for the treatment of proximal ureteral avulsion secondary to ureteroscopic intervention. *Türk Üroloji Dergisi* 2007;33:235–7.
3. Huelsman SP. Renal autotransplantation- Past, present and future. Available from: <https://www.ast.org/articles/2007/2007-01-277.pdf>. Accessed May 2, 2014.
4. Teo KJ, Heng CT, Consigliere D, Tiong HY. Renal autotransplantation following long segment iatrogenic ureteric injury. *Can J Urol*

- 2011;18:6060–3.
5. Neo EN, Zulkifli Z, Sritharan S, Lee BC, Nazri J. Renal autotransplantation after an iatrogenic left ureteric injury. *Med J Malaysia* 2007;62:164–5.
  6. Workowicz C, Libertino JA. Renal autotransplantation. *BJU Int* 2004;93:253–7. [CrossRef]
  7. Lytton B, Schiff M. Interposition of an ileal segment for repair of ureteral injuries. *J Urol* 1981;125:739–41. [CrossRef]
  8. Aki FT, Koni A, Bilen CY, Inci K, Ergen A, Ozen H, et al. Renal autotransplantation for managing severe proximal ureteric injury. *Turkish J Nephrol* 2010;19:143–6. [CrossRef]
  9. Stein R, Rubenwolf P, Ziesel C, Kamal MM, Thüroff JW. Psoas hitch and Boari flap ureteroneocystostomy. *BJU Int* 2013;112:137–55. [CrossRef]
  10. Eisenberg ML, Lee KL, Zumrutbas AE, Meng MV, Freise CE, Stoller ML. Long-term outcomes and late complications of laparoscopic nephrectomy with renal autotransplantation. *J Urol* 2008;179:240–3. [CrossRef]

## OLGU SUNUMU - ÖZET

### İyatrojenik üreter yaralanmasına bağlı böbrek ototransplantasyonu: Olgu sunumu

Dr. Şahin Kaymak,<sup>1</sup> Dr. Mustafa Tahir Özer,<sup>1</sup> Dr. Sezai Demirbas,<sup>2</sup> Dr. Engin Kaya,<sup>3</sup> Dr. Orhan Kozak<sup>1</sup>

<sup>1</sup>Sağlık Bilimleri Üniversitesi, Gülhane Tıp Fakültesi, Genel Cerrahi Anabilim Dalı, Ankara

<sup>2</sup>TOBB ETÜ Tıp Fakültesi Hastanesi, Genel Cerrahi Anabilim Dalı, Ankara

<sup>3</sup>Sağlık Bilimleri Üniversitesi, Gülhane Tıp Fakültesi, Üroloji Anabilim Dalı, Ankara

Ciddi üreter yaralanmalarını tedavi etmek için renal ototransplantasyon ilk kez 1963'te Hardy ve arkadaşları tarafından yapıldı. Bu yöntem travma, renal arter hastalıkları veya üreteral darlığın karmaşık tedavisinde kullanılan bir yöntem olmuştur. Proksimal üreterin yaklaşık 2/3'ünün iyatrojenik yaralanması durumunda, uç uca anastomoz mümkün değilse, renal ototransplantasyon, ileal üreter interpozisyonu veya nefrektomi alternatif tedavilerdir. Teknoloji ilerledikçe üreterorenoskopi (URS) kullanımı artmakta ve bu paralel olarak bu işlem esnasında meydana gelen iyatrojenik yaralanmalarda artmaktadır. Bu tür yaralanmalar genellikle basit delikler şeklindedir (%2–6), ancak zaman zaman üreter avülsiyonları da gözlenir (%0.3). Bu makalede sağ üreter taşı nedeniyle yapılan üreterorenoskopi işlemi sırasında üreter avülsiyonunun gelişmesini takiben renal ototransplantasyonun yapıldığı bir olgu sunuldu ve tedavi seçenekleri literatür ışığında tartışıldı.

**Anahtar sözcükler:** İyatrojenik, renal ototransplantasyon; üreter yaralanması.

*Ulus Travma Acil Cerrahi Derg* 2021;27(2):260-264 doi: 10.14744/tjtes.2020.80606