




Comparison of erector spinae plane block and rectus sheath block for postoperative analgesia in patients undergoing laparoscopic cholecystectomy: A retrospective non-inferiority study

 Mete Manıcı,¹  İlayda Kalyoncu,¹  Merve Ümran Yılmaz,¹  Ergün Mendes,¹  Derya Salim Uymaz,²
 Emre Balık,²  Yavuz Gürkan¹

¹Department of Anesthesiology and Reanimation, Koç University Faculty of Medicine Hospital, İstanbul-Türkiye

²Department of General Surgery, Koç University Faculty of Medicine Hospital, İstanbul-Türkiye

ABSTRACT

BACKGROUND: Effective management of postoperative analgesia following laparoscopic cholecystectomy (LC) is critical to ensure optimal patient comfort and recovery. This study evaluates the effects of erector spinae plane block (ESPB) and rectus sheath block (RSB) on opioid consumption to determine non-inferiority.

METHODS: This retrospective study analyzed 44 patients aged 18 to 75 years who underwent LC at our hospital between December 2022 and March 2023, with American Society of Anesthesiologists (ASA) scores of I-II. Patients were divided into two groups: ESPB (n=24) and RSB (n=20). The ESPB group received a preoperative bilateral injection of 20 mL of 0.25% bupivacaine, while the RSB group received a postoperative bilateral injection of 20 mL of 0.25% bupivacaine. The primary outcome measure was opioid consumption within the first 24 hours postoperatively.

RESULTS: The demographic characteristics of the RSB and ESPB groups were similar. Opioid consumption during the first 24 hours was 6.29±1.73 mg in the ESPB group and 6.60±3.41 mg in the RSB group, with no statistically significant difference between the two groups (95% confidence interval [CI]: -1.64 to 1.02; p=0.717). When the equivalence margin was set at -2 mg, opioid consumption in the RSB group was found to be similar to that in the ESPB group. Fentanyl rescue analgesia in the postoperative care unit was required by three patients in the ESPB group and five patients in the RSB group (p=0.400). Visual Analog Scale (VAS) pain scores and the number of patients who developed nausea and vomiting in the first 24 hours postoperatively were similar between the groups (p>0.05).

CONCLUSION: The erector spinae plane block and RSB demonstrated comparable analgesic efficacy. Rectus sheath block was found to be non-inferior to ESPB in LC surgery with respect to 24-hour opioid consumption. The groups were also similar regarding rescue analgesia, VAS scores, shoulder pain, and the frequency of nausea and vomiting.

Keywords: Laparoscopic cholecystectomy; erector spinae plane block; rectus sheath block; postoperative analgesia; opioid consumption.

Cite this article as: Manıcı M, Kalyoncu İ, Yılmaz MÜ, Mendes E, Uymaz DS, Balık E, et al. Comparison of erector spinae plane block and rectus sheath block for postoperative analgesia in patients undergoing laparoscopic cholecystectomy: A retrospective non-inferiority study. *Ulus Travma Acil Cerrahi Derg* 2025;31:242-248.

Address for correspondence: Ergün Mendes

Department of Anesthesiology and Reanimation, Koç University Faculty of Medicine Hospital, İstanbul, Türkiye

E-mail: erg.mendes@gmail.com

Ulus Travma Acil Cerrahi Derg 2025;31(3):242-248 DOI: 10.14744/tjtes.2024.77756

Submitted: 19.07.2024 Revised: 003.10.2024 Accepted: 16.11.2024 Published: 03.03.2025

OPEN ACCESS This is an open access article under the CC BY-NC license (<http://creativecommons.org/licenses/by-nc/4.0/>).



INTRODUCTION

Laparoscopic cholecystectomy (LC) is a minimally invasive procedure that is considered the gold standard for treating benign gallbladder disease. It offers several advantages over open surgery, including reduced postoperative pain, shorter hospital stays, and faster recovery times.^[1] Despite these benefits, postoperative pain management continues to be a challenge, significantly affecting patient satisfaction and recovery time. Effective pain control is essential for optimizing recovery and minimizing the length of hospital stay.^[2]

Three distinct pathways contribute to pain after LC: (1) somatic pain caused by skin incision, (2) intra-abdominal visceral pain resulting from trauma during gallbladder resection and the pressure exerted by carbon dioxide pneumoperitoneum, and (3) referred shoulder pain caused by diaphragm irritation.^[1] The intensity of postoperative pain reported by patients varies widely, but incisional pain should be the primary focus of postoperative pain management.

The erector spinae plane block (ESPB), first defined by Forero et al.^[2] in 2016, has been extensively studied for its efficacy in managing postoperative pain across various surgical indications.^[3-5] The erector spinae plane block functions as a paraspinal block, alleviating both visceral and somatic pain by spreading anteriorly into the paravertebral area. This spread affects the ventral, dorsal, and communicating spinal branches, with craniocaudal distribution across multiple vertebral levels.^[6] Rectus sheath block (RSB), a fascial plane block, is known to enhance pain control and reduce opioid consumption in laparoscopic surgeries for up to 12 hours postoperatively.^[7] This study compared RSB and ESPB to evaluate their efficacy in postoperative analgesia for LC patients and to test the hypothesis that RSB is non-inferior to ESPB. Total 24-hour opioid consumption, rescue analgesic requirements, Visual Analog Scale (VAS) pain scores, and the presence of shoulder pain were compared between the groups.

MATERIALS AND METHODS

After obtaining approval from the Koç University Ethics Committee (Decision No: 2024.264.IRB2.114, Date: 02.05.2024) for this retrospective non-inferiority study, patients who underwent LC at our hospital between December 2022 and March 2023 were reviewed. The study included patients aged 18 to 75 years with an American Society of Anesthesiologists (ASA) score of I-II. Patients with a history of chronic pain, opioid use, or contraindications to regional anesthesia were excluded. Participants were divided into two groups based on the type of block administered: the ESPB group and the RSB group. The following data were collected and analyzed: demographic information, operative time, VAS pain scores at 1, 6, 12, and 24 hours postoperatively, and the presence of postoperative shoulder pain. Additionally, requirements for rescue analgesia in the postoperative care unit (PACU), 24-hour morphine consumption, and the frequency of postoperative nausea and vomiting were assessed.

The routine anesthesia protocol for LC at our hospital was followed in this study. Preoperative monitoring included electrocardiogram (ECG), non-invasive blood pressure (NIBP), heart rate, and peripheral oxygen saturation, with these parameters recorded as baseline values. General anesthesia was induced using 2-3 mg/kg propofol, 1-2 mcg/kg fentanyl, and 0.6 mg/kg rocuronium. Anesthesia was maintained with an intravenous (IV) remifentanyl infusion at 0.1-0.15 mcg/kg/h, targeting 1 minimum alveolar concentration (MAC) using 6% desflurane as the inhalation agent.

The erector spinae plane block was performed preoperatively before the induction of general anesthesia. Twenty mL of 0.25% bupivacaine were injected bilaterally, anterior to the erector spinae muscle, between the T7 and T8 transverse processes under ultrasound (USG) guidance, with the patient in the sitting position. The rectus sheath block was performed at the end of the surgery, prior to extubation. Twenty mL of 0.25% bupivacaine were injected bilaterally under USG guidance with the patient in the supine position, in the plane between the posterior part of the rectus abdominis muscle and the posterior sheath, approximately 2 cm lateral and above the umbilicus. Both blocks were conducted using an in-plane approach with a 22-gauge, 8-cm B Braun block needle (B. Braun Melsungen AG, Germany).

Paracetamol at a dose of 10 mg/kg and tramadol hydrochloride (HCl) at 1 mg/kg were routinely administered for postoperative analgesia 15 minutes before extubation. For patient-controlled analgesia (PCA), a bolus dose of 1 mg/mL morphine was used without an infusion dose, with an 8-minute lock period. Pain levels were measured using the VAS, where patients rated their pain on a scale from 0 (no pain) to 10 (excruciating pain). Patients with VAS scores between 0 and 3 continued with the routine PCA protocol in the postoperative period. Fentanyl at a dose of 0.5 mcg/kg was administered as rescue analgesia for patients with VAS scores greater than 3. Pain levels were reassessed every 10 minutes, and additional fentanyl doses were provided as needed in the PACU. The use of fentanyl, in addition to morphine, was expressed as total morphine equivalent doses for the 24-hour postoperative follow-up period. Paracetamol was administered regularly three times daily after surgery. The Visual Analog Scale scores and the presence of postoperative shoulder pain were assessed at 1, 6, 12, and 24 hours postoperatively. Side effects and complications were also evaluated.

The primary outcome was defined as the patients' opioid consumption during the first 24 hours after surgery, recorded as the total morphine equivalent dose. Secondary outcomes included the requirement for fentanyl rescue analgesia in the PACU, VAS pain scores, and the presence of shoulder pain at the 24-hour postoperative follow-up.

Statistical Analysis

The Statistical Package for the Social Sciences (SPSS) version 27.0 (IBM SPSS Statistics, IBM Corporation, Chicago, Illinois, USA) was used for all statistical analyses. Non-inferiority was defined as 2 mg per 24-hour morphine consumption based on our clinical practice and opioid consumption literature.^[8] To achieve an 80% probability of demonstrating non-inferiority, the minimum required sample size was calculated as 17 cases per group, assuming a type I error rate of 0.05 and 90% power, with an equal group ratio as reported in previous studies.^[9] The sample size for group was set at 20 to account for potential missing data.

Descriptive statistics are presented as mean ± standard deviation (SD) or median (min-max). Correlations between categorical variables were tested using chi-squared tests, with categorical variables presented as the number of cases n (%). The Kolmogorov-Smirnov test was used to assess whether the quantitative data followed a normal distribution. Student's t-tests were applied to compare variables with normal distributions in both groups, while Mann-Whitney U tests were used for variables with non-normal distributions. The confidence interval was set at 95%, and a p-value of <0.05 was considered statistically significant.

RESULTS

The demographic characteristics of the patients are summarized Table 1. A total of 24 patients were included in the ESPB group and 20 patients in the RSB group. Morphine consumption via PCA at 24 hours was 6.29±1.73 mg in the ESPB group and 6.60±3.41 mg in the RSB group (p=0.717) (Fig. 1). There was no statistically significant difference in opioid consumption between the two groups during the first 24 hours after surgery (95% confidence interval [CI]: -1.64 to 1.02; p=0.717). Using a non-inferiority margin of -2 mg based on our clinical practice, the RSB group was demonstrated to be non-inferior to the ESPB group in opioid consumption with a 95% confidence interval (Fig. 2).

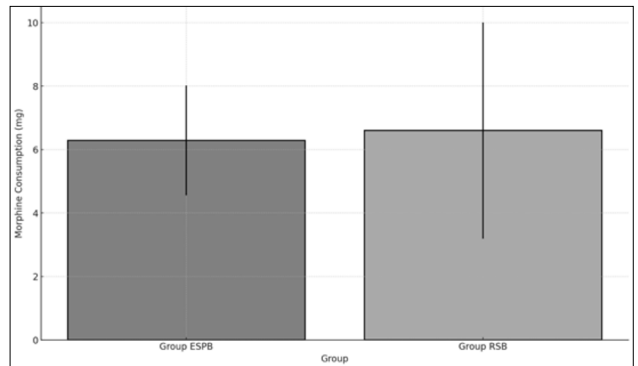


Figure 1. Average morphine consumption by group with standard deviation.

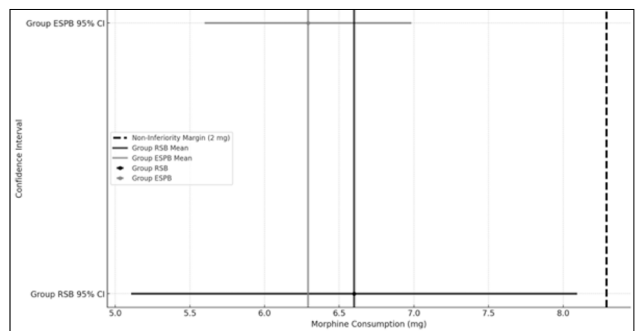


Figure 2. Morphine consumption by group with 95% confidence interval.

Comparing the ESPB and RSB groups, the number of patients requiring rescue analgesics was 3 (12.50%) in the ESPB group and 5 (25.00%) in the RSB group (p=0.400), indicating similarity between the groups. The Visual Analog Scale scores and the incidence of shoulder pain at 1, 6, 12, and 24 hours postoperatively were also similar between the two groups (Table 2).

For VAS pain scores:

- At 1 hour, the median scores were 1.00 (range: 0-3) in the

Table 1. Demographic data

	ESPB Group (n=24)	RSB Group (n=20)	p-value
Age	52.67±13.83	58.60±13.31	0.150
Gender (F/M)	12/8	15/9	0.865
Height (cm)	171.37±14.77	169.39±12.31	0.635
Weight (kg)	76.90±13.82	79.08±14.15	0.609
Body Mass Index (BMI)	27.01±7.64	27.82±5.85	0.700
American Society of Anesthesiologists (ASA) Classification (I/II)	6/18	5/15	1.000

Table 2. Comparison of operative time, shoulder pain, Visual Analog Scale (VAS) scores at 1, 6, 12, and 24 hours, pain relief requirements, opioid consumption, and nausea/vomiting frequency between groups

	ESPB Group (n=24)	RSB Group (n=20)	p-value
Operative Time (minutes)	99.67±19.63	106.25±24.77	0.401
VAS Scores (hour)			
1	1.00 (0-3)	1.00 (0-8)	0.554
6	1.50 (0-4)	1.50 (0-4)	0.923
12	2.50 (0-4)	1.50 (0-7)	0.457
24	0.00 (0-1)	0.00 (0-4)	0.882
Shoulder Pain (hour)			
1	2 (8.33%)	5 (25.00%)	0.142
6	2 (8.33%)	5 (25.00%)	0.142
12	2 (8.33%)	1 (5.00%)	0.686
24	2 (8.33%)	1 (5.00%)	0.686
Shoulder Pain n (%)	3 (12.50%)	5 (25.00%)	0.400
Rescue Analgesia Requirement n (%)	3 (12.50%)	5 (25.00%)	0.400
PCA Use (24th hour)	6.29±1.73	6.60±3.41	0.717
POVN (Nausea/Vomiting) n (%)	3 (12.50%)	2 (10.00%)	1.000

VAS: Visual Analog Scale; PCA: Patient-Controlled Analgesia; POVN: Postoperative Nausea or Vomiting.

ESPB group and 1.00 (range: 0-8) in the RSB group ($p=0.554$).

- At 6 hours, the median scores were 1.50 (range: 0-4) in the ESPB group and 1.50 (range: 0-3) in the RSB group ($p=0.923$).
- At 12 hours, the median scores were 2.50 (range: 0-4) in the ESPB group and 1.50 (range: 0-7) in the RSB group ($p=0.457$).
- At 24 hours, the median scores were 0.00 (range: 0-1) in the ESPB group and 0.00 (range: 0-4) in the RSB group ($p=0.882$).

When comparing the ESPB group to the RSB group, 2 (8.33%) patients in the ESPB group and 5 (25.00%) patients in the RSB group reported shoulder pain at hour 1 and hour 6 ($p=0.142$). At hour 12 and hour 24, 2 (8.33%) patients in the ESPB group and 1 (5.00%) patient in the RSB group reported shoulder pain ($p=0.686$). Overall, shoulder pain developed in 3 (12.50%) patients in the ESPB group and 5 (25.00%) patients in the RSB group ($p=0.400$).

The incidence of nausea or vomiting (VN) was 3 (12.50%) in the ESPB group and 2 (10.00%) in the RSB group, with no significant difference ($p=1.000$). No additional side effects or complications were observed.

DISCUSSION

The findings of this retrospective non-inferiority study indicate that RSB offers a similar level of analgesia to ESPB and is non-inferior in managing postoperative pain for LC. Post-

operative rescue analgesic use and total 24-hour opioid consumption did not differ between the two groups.

Additionally, VAS pain scores and the incidence of postoperative shoulder pain were similar between the two groups. These results suggest that RSB may be an alternative for postoperative pain management in LC surgery, offering an analgesic effect comparable to ESPB.

Abdominal wall blocks are recommended as part of multimodal postoperative analgesia in laparoscopic abdominal surgery, in line with Enhanced Recovery After Surgery (ERAS) protocols.^[10] Similar previous studies on LC surgery have used RSB for midline incisions at abdominal wall port placement sites, as well as alternative abdominal wall block combinations.^[1,10,11] Almost all abdominal wall block combinations incorporate RSB as the gold standard for midline surgery. Blocks that may serve as alternatives to RSB for umbilical anesthesia could also replicate the analgesic effects resulting from the ventral spread of paraspinal blocks. In a comparison between thoracic epidural block and RSB in previous studies on laparoscopic gastric or colorectal surgery, our literature review found RSB to be inferior.^[12] This study is the first report of a non-inferiority comparison between ESPB and RSB in LC, based on our review of the literature.

The RSB achieves analgesia by blocking somatic nerve endings originating at the T7-T11 levels and terminating in the anterior abdominal wall. The clinical value of RSB in alleviat-

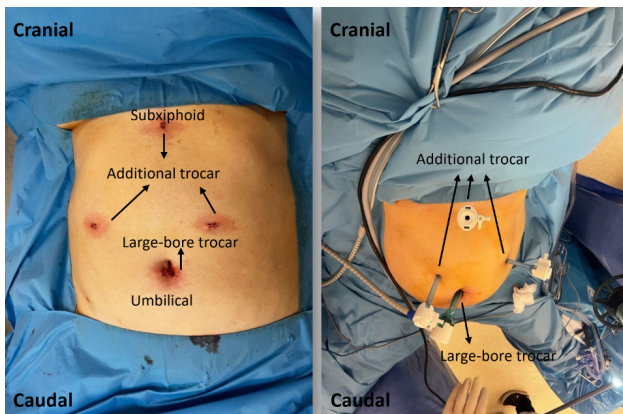


Figure 3. Trocar entry sites in laparoscopic cholecystectomy.

ing pain associated with midline abdominal incisions and laparoscopic surgery has recently been increasingly emphasized.^[13,14] The ESPB, preferred for its paraspinal block-like effects, is administered at the T7-T9 level of the thoracic transverse process during LC surgery. However, some studies suggest that ESPB provides limited visceral analgesia, making RSB a potentially effective alternative in this context.^[6] Given the limited visceral effects of ESPB, the primary focus shifts to addressing somatic pain in the abdominal wall. Comparative studies on the analgesic efficacy of RSB and ESPB have been relatively limited.

Previous studies have demonstrated that ESPB provides effective analgesia in the thoracoabdominal region and is safe, with a minimal side effect profile.^[15] Similarly, RSB is a widely used technique in abdominal surgery, offering effective pain management.^[14] Both RSB and ESPB are safe, with low risk of complications when performed under USG guidance. However, RSB may have an advantage as it is performed in the supine position and does not require additional patient positioning. USG-guided RSB is a safe and recommended method in a cohort of 4,033 cases (56.3% LC).^[16] Additional benefits of RSB include its relative ease of use, lack of associated hypotension or motor block, minimal invasiveness, and its ability to be easily applied after the patient is asleep.^[17] In our study, no additional side effects or complications were observed for either block, apart from nausea and vomiting.

Although the single-port method has gained prominence in LC surgery in recent years, the multi-port method, which offers greater ease of movement, is the more widely used approach. In the multi-port technique, a large-bore trocar is inserted into the anterior abdominal wall through the umbilical region, and an additional trocar is placed through the subxiphoid region. Two small incisions are made in both subcostal areas on the lateral abdominal wall, guided by a trocar tip. Umbilical or periumbilical incisions require peritoneal and fascial closure due to the use of a large-bore trocar, whereas other incisions can be closed with a primary skin closure. Therefore, incisions in the umbilical area are more painful than those involving only skin sutures.^[18,19] Given the size of

the midline skin incision, most of the pain is attributed to this area. In this context, the primary focus of the combined blocks, which complement RSB, is on the two small incisions on the lateral abdominal wall. These incisions could be managed by the surgeon with local anesthetic (LA) infiltration for pain relief.^[20] However, in our routine practice, these two incisions were not treated, and the surgeon did not apply LA infiltration (Fig. 3).

It was observed that there was no difference in perioperative sufentanil levels among the control group, isolated lateral transversus abdominis plane (TAP), and combined RSB + lateral TAP applications in multi-port laparoscopic upper abdominal surgery. While isolated lateral TAP showed no difference compared to the control group in rest and cough-induced pain, the combination of lateral TAP + RSB demonstrated improvement during the first 24 hours. Additionally, this combination reduced postoperative opioid consumption and PCA requirements, with further benefits extending up to two days.^[21] After laparoscopic radical rectal cancer resection, the combination of posterior TAP + RSB proved superior to posterior TAP alone and the control group in terms of rescue analgesic use and cumulative sufentanil dose. However, no difference was found between posterior TAP alone and the control group.^[22] In a study comparing multi-port and single-port methods, it was observed that the type of port method did affect postoperative pain scores. However, the addition of RSB to the single-port method provided noticeable improvement within the first 6 hours.^[23] The importance of midline analgesia has also been highlighted in reports comparing USG-guided RSB with alternative methods, such as LA infiltration, laparoscopic RSB, or incisional RSB.^[14] In a similar framework, we would like to emphasize that targeting areas other than the large-bore trocar is unlikely to result in significant differences and may require additional procedures and implementations.

De Cassai et al.,^[8] in their meta-analysis evaluating the use of peripheral blocks in laparoscopic abdominal surgery, found that peripheral blocks other than RSB demonstrated efficacy. For postoperative morphine milligram equivalents (MME) over 24 hours, the results were as follows: ESPB; -4.96 [-6.82, -3.11], and RSB, -2.17 [-5.75, 1.40] (mean difference, MD (95% CI)). The study notes that the limited number of RSB studies results in limited parameters. In particular, the analytical studies presented here make comparisons with alternative application methods, such as LA combinations in control groups: MME-24h (mg) for wound and port infiltration was -2.37 [-3.56, -1.18] and for intraperitoneal instillation, it was -2.23 [-3.39, -1.06] (MD (95% CI)).^[14,23,24] In one of these studies, Kitamura et al.^[24] reported that, contrary to expectations, bilateral 10 mL of 0.375% ropivacaine RSB did not show a significant difference compared to the control group in LC surgery. Similarly, the subcutaneous and fascial application of 10 mL of 0.75% ropivacaine through the umbilical incision also did not result in a difference in VAS scores for

pain. In another study, Hamid et al.,^[14] in their meta-analysis of nine studies (698 patients) comparing the use of RSB to no regional anesthesia technique in abdominal laparoscopic surgery, found significant improvement in resting and active pain scores at 2 hours postoperatively. Additionally, RSB significantly reduced postoperative 24-hour opioid consumption (MME-24h (mg): RSB, -1.34 [-2.20, -0.49] (MD (95% CI))).

Jeffries et al.^[25] found RSB to be safe and effective for pain relief in abdominal surgery. It was associated with decreased opioid consumption, equivalent to intravenous morphine, within the first 24 hours, with greater efficacy observed in the first 2 hours postoperatively (MME-24h (mg): RSB, -1.55 [-2.35, -0.74] (MD (95% CI))). They noted that this modest reduction may be attributed to the moderate-to-low quality of evidence in the 20 studies included in the review, significant statistical heterogeneity, the inclusion of control groups utilizing infiltration and intra-abdominal instillation practices, and the inclusion of emergency case groups in laparotomy studies alongside laparoscopic surgeries.

Daghmouri et al.,^[26] in their meta-analysis of five studies (250 patients) evaluating T7-T9 bilateral ESPB in laparoscopic abdominal surgery, found a significant reduction in opioid consumption (MME-24h (mg): ESPB, -4.46 [-5.50, -3.42] (MD (95% CI))). The mean time to the first postoperative analgesic requirement was 73 minutes (73.27 minutes [50.39, 96.15] (MD (95% CI))). Kwon et al.^[6] observed that the routine use of RSB in LC surgery reduced fentanyl consumption by 41.9 mcg within the first 6 hours and by 77.2 mcg within 24 hours when ESPB was applied at the T7 level. While this reduction was statistically significant, it was noted that it may not be clinically meaningful.^[27] In our study, the groups were comparable in terms of rescue analgesia requirements.

The visceral analgesic effect of ESPB occurs due to possible paravertebral spread during its application. Bilateral ESPB (6.08±3.66 mg) and unilateral ESPB (8.28±5.79 mg) applied at the T8 level reduced 24-hour total morphine consumption and shoulder pain (+/-): 3/42 and 12/33 patients, respectively. Although the number of patients in their study was not small, the high standard deviation observed in the ESPB application provides additional evidence supporting our findings.^[28] In our study, similar results were observed regarding total 24-hour morphine consumption via PCA, consistent with bilateral ESPB, and the groups were similar. However, shoulder pain was twice as common in the RSB group compared to the ESPB group.

Limitations

The first limitation of our study is its retrospective design. The absence of a control group constitutes the second limitation. The timing differences between ESPB and RSB, depending on their application in the preoperative and postoperative periods, represent another limitation. Future prospective randomized controlled trials (RCT) are necessary.

CONCLUSION

In terms of 24-hour postoperative opioid consumption, the RSB technique was found to be as effective as ESPB. Both blocks demonstrated similar efficacy in postoperative analgesia, making them safe and effective options for pain management after LC.

Ethics Committee Approval: This study was approved by the Koç University Ethics Committee (Date: 02.05.2024, Decision No: 2024.264.IRB2.114).

Peer-review: Externally peer-reviewed.

Authorship Contributions: Concept: M.M., I.K., M.U.Y., E.M., D.S.U., E.B., Y.G.; Design: M.M., I.K., M.U.Y., E.M., D.S.U., E.B., Y.G.; Supervision: M.M., I.K., M.U.Y., E.M., D.S.U., E.B., Y.G.; Resource: M.M., I.K., M.U.Y., D.S.U., E.B.; Materials: M.M., I.K., M.U.Y., E.M., D.S.U., E.B., Y.G.; Data Collection and/or Processing: M.M., I.K., M.U.Y., E.M., D.S.U.; Analysis and/or Interpretation: M.M., E.M., D.S.U., E.B., Y.G.; Literature Review: M.M., M.U.Y., E.M., D.S.U., E.B., Y.G.; Writing: E.M., E.B., Y.G.; Critical Review: M.M., E.M., D.S.U., E.B., Y.G.

Conflict of Interest: None declared.

Financial Disclosure: The author declared that this study has received no financial support.

REFERENCES

- Haitov Ben Zikri Z, Volis M, Mazur A, Orlova T, Alon H, Bar Yehuda S, et al. The effect of various combinations of peripheral nerve blocks on postoperative pain in laparoscopic cholecystectomy: A comparative prospective study. *Int J Clin Pract* 2023;2023:8864012. [\[CrossRef\]](#)
- Forero M, Adhikary SD, Lopez H, Tsui C, Chin KJ. The erector spinae plane block: A novel analgesic technique in thoracic neuropathic pain. *Reg Anesth Pain Med* 2016;41:621–7. [\[CrossRef\]](#)
- Tulgar S, Kapakli MS, Senturk O, Selvi O, Serifsoy TE, Ozer Z. Evaluation of ultrasound-guided erector spinae plane block for postoperative analgesia in laparoscopic cholecystectomy: A prospective, randomized, controlled clinical trial. *J Clin Anesth* 2018;49:101–6. [\[CrossRef\]](#)
- Camtez A, Kozanhan B, Aksoy N, Yildiz M, Tutar MS. Effect of erector spinae plane block on the postoperative quality of recovery after laparoscopic cholecystectomy: A prospective double-blind study. *Br J Anaesth* 2021;127:629–35. [\[CrossRef\]](#)
- Lu H, Xie Q, Ye W, Zhou Z, Lei Z. Ultrasound-guided erector spinae plane block for postoperative analgesia in Chinese patients undergoing laparoscopic cholecystectomy: A double-blind randomized controlled trial. *Langenbecks Arch Surg* 2023;408:111. [\[CrossRef\]](#)
- Kwon HM, Kim DH, Jeong SM, Choi KT, Park S, Kwon HJ, et al. Does erector spinae plane block have a visceral analgesic effect?: A randomized controlled trial. *Sci Rep* 2020;10:8389. [\[CrossRef\]](#)
- Jeong HW, Kim CS, Choi KT, Jeong SM, Kim DH, Lee JH. Preoperative versus postoperative rectus sheath block for acute postoperative pain relief after laparoscopic cholecystectomy: A randomized controlled study. *J Clin Med* 2019;8:1018. [\[CrossRef\]](#)
- De Cassai A, Sella N, Geraldini F, Tulgar S, Ahiskalioglu A, Dost B, et al. Single-shot regional anesthesia for laparoscopic cholecystectomies: A systematic review and network meta-analysis. *Korean J Anesthesiol* 2023;76:34–46. [\[CrossRef\]](#)
- Park JS, Choi GS, Kwak KH, Jung H, Jeon Y, Park S, et al. Effect of local wound infiltration and transversus abdominis plane block on morphine use after laparoscopic colectomy: A nonrandomized, single-blind prospective study. *J Surg Res* 2015;195:61–6. [\[CrossRef\]](#)

10. Marti K, Rochon C, O'Sullivan DM, Ye X, Ebcioglu Z, Kainkaryam PP, et al. Evaluation of a multimodal analgesic regimen on outcomes following laparoscopic living donor nephrectomy. *Clin Transplant* 2021;35:e14311. [CrossRef]
11. Selvi O, Tulgar S, Senturk O, Serifsoy TE, Thomas DT, Devci U, et al. Is a combination of the serratus intercostal plane block and rectus sheath block superior to the bilateral oblique subcostal transversus abdominis plane block in laparoscopic cholecystectomy? *Eurasian J Med* 2020;52:34-7. [CrossRef]
12. Owada Y, Murata Y, Hamaguchi Y, Yamada K, Inomata S, Ogawa K, et al. Comparison of postoperative analgesic effects of thoracic epidural analgesia and rectus sheath block in laparoscopic abdominal surgery: A randomized controlled noninferiority trial. *Asian J Endosc Surg* 2023;16:423-31. [CrossRef]
13. Fu H, Zhong C, Fu Y, Gao Y, Xu X. Perioperative analgesic effects of preemptive ultrasound-guided rectus sheath block combined with butorphanol or sufentanil for single-incision laparoscopic cholecystectomy: A prospective, randomized, clinical trial. *J Pain Res* 2020;13:1193-200. [CrossRef]
14. Hamid HKS, Ahmed AY, Alhamo MA, Davis GN. Efficacy and safety profile of rectus sheath block in adult laparoscopic surgery: A meta-analysis. *J Surg Res* 2021;261:10-7. [CrossRef]
15. Gürkan Y, Aksu C, Kuş A, Yörükoğlu UH. Erector spinae plane block and thoracic paravertebral block for breast surgery compared to IV-morphine: A randomized controlled trial. *J Clin Anesth* 2020;59:84-8. [CrossRef]
16. Kwon HJ, Kim YJ, Kim Y, Kim S, Cho H, Lee JH, et al. Complications and technical consideration of ultrasound-guided rectus sheath blocks: A retrospective analysis of 4033 patients. *Anesth Analg* 2023;136:365-72. [CrossRef]
17. Hausken J, Rydenfelt K, Horneland R, Ullensvang K, Kjøsen G, Tønnesen TI, et al. First experience with rectus sheath block for postoperative analgesia after pancreas transplant: A retrospective observational study. *Transplant Proc* 2019;51:479-84. [CrossRef]
18. Nakazawa M, Fukushima T, Shoji K, Momosaki R, Mio Y. Preoperative versus postoperative ultrasound-guided rectus sheath block for acute postoperative pain relief after laparoscopy: A retrospective cohort study. *Medicine (Baltimore)* 2024;103:e37597. [CrossRef]
19. Cho S, Kim YJ, Jeong K, Moon HS. Ultrasound-guided bilateral rectus sheath block reduces early postoperative pain after laparoscopic gynecologic surgery: A randomized study. *J Anesth* 2018;32:189-97. [CrossRef]
20. Beaussier M, Parc Y, Guechot J, Cachanado M, Rousseau A, Lescot T; CATCH Study Investigators. Ropivacaine preperitoneal wound infusion for pain relief and prevention of incisional hyperalgesia after laparoscopic colorectal surgery: A randomized, triple-arm, double-blind controlled evaluation vs intravenous lidocaine infusion, the CATCH study. *Colorectal Dis* 2018;20:509-19. [CrossRef]
21. Yu S, Wen Y, Lin J, Yang J, He Y, Zuo Y. Combined rectus sheath block with transverse abdominis plane block by one puncture for analgesia after laparoscopic upper abdominal surgery: A randomized controlled prospective study. *BMC Anesthesiol* 2024;24:58. [CrossRef]
22. Liang M, Xv X, Ren C, Yao Y, Gao X. Effect of ultrasound-guided transversus abdominis plane block with rectus sheath block on patients undergoing laparoscopy-assisted radical resection of rectal cancer: A randomized, double-blind, placebo-controlled trial. *BMC Anesthesiol* 2021;21:89. [CrossRef]
23. Kamei H, Ishibashi N, Nakayama G, Hamada N, Ogata Y, Akagi Y. Ultrasound-guided rectus sheath block for single-incision laparoscopic cholecystectomy. *Asian J Endosc Surg* 2015;8:148-52. [CrossRef]
24. Kitamura N, Iida H, Maehira H, Mori H, Sada Y, Shimizu T, et al. Postoperative analgesic effect of ultrasound-guided rectus sheath block and local anesthetic infiltration after laparoscopic cholecystectomy: Results of a prospective randomized controlled trial. *Asian J Endosc Surg* 2022;15:29-35. [CrossRef]
25. Jeffries SD, Harutyunyan R, Morse J, Hemmerling TM. Investigation into the clinical performance of rectus sheath block in reducing postoperative pain following surgical intervention: A systematic review and meta-analysis of randomized controlled trials. *Indian J Anaesth* 2024;68:142-52. [CrossRef]
26. Daghmouri MA, Akremi S, Chaouch MA, Mesbahi M, Amouri N, Jaoua H, et al. Bilateral erector spinae plane block for postoperative analgesia in laparoscopic cholecystectomy: A systematic review and meta-analysis of randomized controlled trials. *Pain Pract* 2021;21:357-65. [CrossRef]
27. Ardon A, Hernandez N. The use of peripheral nerve blockade in laparoscopic and robotic surgery: Is there a benefit? *Curr Pain Headache Rep* 2022;26:25-31. [CrossRef]
28. Cesur S, YR Ko Lu HU, Aksu C, Ku A. Bilateral versus unilateral erector spinae plane block for postoperative analgesia in laparoscopic cholecystectomy: A randomized controlled study. *Braz J Anesthesiol* 2023;73:72-7. [CrossRef]

ORJİNAL ÇALIŞMA - ÖZ

Laparoskopik kolesistektomi uygulanan hastalarda postoperatif analjezi için erektör spina düzlem bloğu ve rektus kılıf bloğunun karşılaştırılması: Retrospektif eşdeğerlik çalışması

AMAÇ: Laparoskopik kolesistektomi (LK) sonrası analjezi yönetimi, optimal konfor ve iyileşmeyi sağlamak için kritik öneme sahiptir. Bu çalışmada, erektör spina düzlem bloğu (ESPB) ve rektus kılıf bloğunun (RSB) opioid tüketimi üzerindeki etkileri eşdeğerlik açısından değerlendirildi.

GEREÇ VE YÖNTEM: Bu retrospektif çalışmada, Aralık 2022 ile Mart 2023 tarihleri arasında hastanemizde LK operasyonu geçiren, Amerikan Anesteziyoloji Derneği (ASA) skoru I-II olan, 18-75 yaş aralığındaki 44 hasta değerlendirildi. Hastalar ESPB (n=24) ve RSB (n=20) olmak üzere iki gruba ayrıldı. ESPB grubuna preoperatif bilateral 20 mL %0.25 bupivakain, RSB grubuna postoperatif bilateral 20 mL %0.25 bupivakain uygulandı. Birincil sonuç ölçütü ameliyattan sonraki ilk 24 saat içindeki opioid tüketimiydi.

BULGULAR: RSB ve ESPB grupları demografik olarak benzerdi. İlk 24 saatteki opioid tüketimi ESPB grubunda 6.29 ± 1.73 mg, RSB grubunda ise 6.60 ± 3.41 mg olmuş ve iki grup arasında anlamlı fark görülmedi (%95 GA -1.64 ila 1.02; $p=0.717$). Eşdeğerlik marjini sınırı -2 mg olarak alındığında, RSB grubundaki opioid tüketiminin ESPB grubuna benzer olduğu görüldü. ESPB grubunda üç hasta ve RSB grubunda beş hastaya ameliyat sonrası bakım ünitesinde fentanil kurtarma analjezisi gerektirdi ($p=0.400$). Gruplar VAS ağrı skorları ve ameliyat sonrası ilk 24 saatte bulantı/kusma gelişen hasta sayısı açısından benzerdi ($p>0.05$).

SONUÇ: ESPB ve RSB'nin karşılaştırılabilir analjezik etkinlik gösterdiği ve RSB'nin 24 saatlik opioid tüketimi açısından LK cerrahisinde ESPB'den daha düşük olmadığı bulundu. Grupların kurtarma analjezisi, VAS skorları, omuz ağrısı, bulantı-kusma sıklığı açısından benzer olduğu görüldü.

Anahtar sözcükler: Laparoskopik kolesistektomi; erektör spina düzlem bloğu; rektus kılıf bloğu; postoperatif analjezi; opioid tüketimi.