

Acute abdomen caused by greater omentum torsion: A case report and review of the literature

Camilla Cremonini, M.D., Andrea Bertolucci, M.D., Dario Tartaglia, M.D.,
Francesca Menonna, M.D., Christian Galatioto, M.D., Massimo Chiarugi, M.D.

Department of Emergency Surgery Unit, Università Di Pisa, Pisa-Italy

ABSTRACT

Torsion of the greater omentum is a rare cause of acute abdomen. Based on etiopathogenesis, it can be classified as primary or secondary. However, regardless of the cause, segmentary or diffuse omental necrosis will follow. Preoperative diagnosis is not easy, though abdominal ultrasound and computed tomography (CT) scans may show peculiar features suggestive of omental torsion. Laparoscopic resection of the affected omentum is the treatment of choice. Presently reported was a case of primary omental torsion, in addition to a comprehensive literature review.

Keywords: Acute abdomen; greater omentum; laparoscopy; omental infarction; torsion.

INTRODUCTION

Omental infarction is a rare cause of acute abdomen. The infarction is primarily caused by torsion of the greater omentum, and can be classified as primary, first described by Eitel in 1899, or as secondary to other diseases.^[1] It mainly affects adults, occurring in men twice as frequently as in women, with the majority of those affected being overweight.^[2] Preoperative diagnosis is difficult, as symptoms are unspecific and may easily be mistaken for those of other diseases, such as acute appendicitis, acute cholecystitis, or right-sided diverticulitis.^[3,4] However, the increasing spread of high-quality imaging, particularly computed tomography (CT), has allowed for preoperative diagnosis to be performed much more often.^[5] Presently described was a case of omental infarction caused by primary torsion. A review of the literature concerning this unusual cause of acute abdomen was also included.

CASE REPORT

A 28-year-old male presented to the emergency department

with a 4-day history of abdominal pain, mainly localized in the right quadrants, associated with anorexia. No nausea nor vomiting were present. The patient had no previous abdominal surgery in his medical history, but reported mild symptoms consistent with gastritis that had begun 4 months prior. The patient was hemodynamically stable and afebrile. The abdomen was soft, not distended, showing tenderness in the right iliac fossa and the right upper quadrant, with physical signs of peritoneal irritation.

Laboratory investigation was normal, revealing no other abnormalities. Abdominal ultrasound showed a roundish hyperechoic lesion in correspondence with the right colon, in the absence of fluid effusion. Abdominal CT scan confirmed the presence of an oval thickening of fat tissue containing convoluted and twisted blood vessels in the right abdomen. These CT features raised suspicion of an area of omental infarction (Figure 1).

Laparoscopy confirmed hemorrhagic infarction with necrosis of the section of the greater omentum attached to the proximal transverse colon; the remainder of the omentum appeared normal. A torsion point with occlusion of blood vessels tributary to the infarcted omentum was identified, and necrotic tissue was resected (Figure 2). No other concomitant intraperitoneal disease was identified. Course of treatment was unremarkable, and the patient was discharged on day 2 in healthy condition.

Address for correspondence: Camilla Cremonini, M.D.

Via Vanni 4 56126 Pisa, Italy

Tel: +39 340 86 50 416 E-mail: camilla.cremonini@outlook.com

Qucik Response Code



Ulus Travma Acil Cerrahi Derg
2016;22(4):391–394
doi: 10.5505/tjtes.2015.74944

Copyright 2016
TJTES

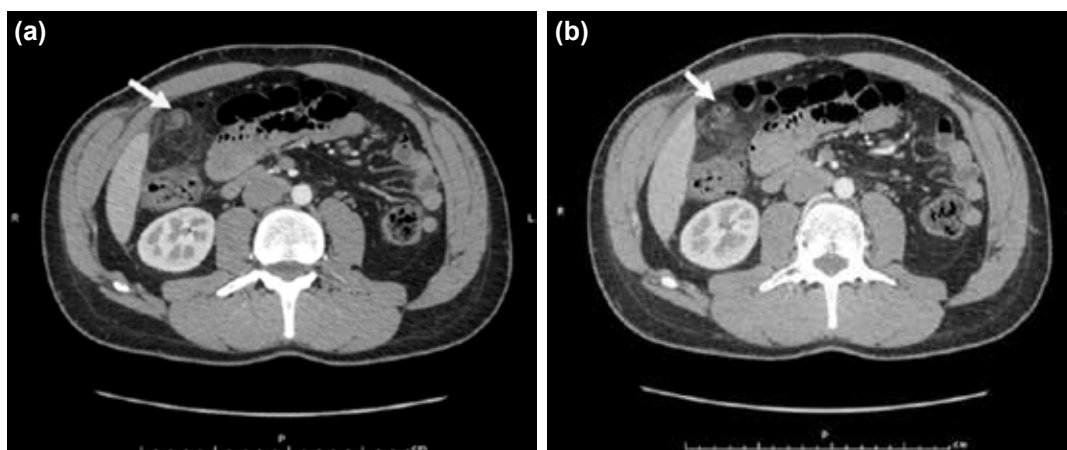


Figure 1. Contrast-enhanced abdominal CT. (a, b) Local mass of fat density in a whirling pattern at the twisted point of the omentum (arrows).

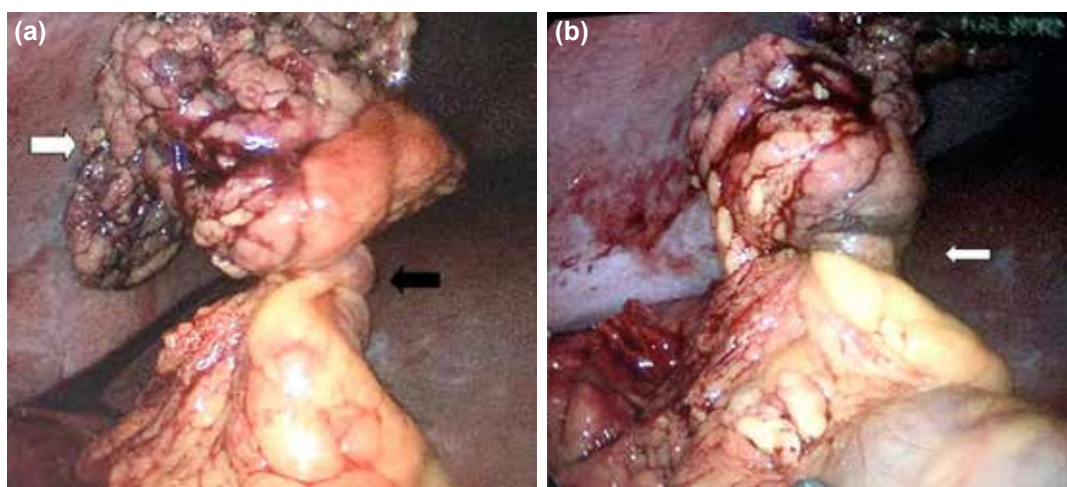


Figure 2. Intraoperative findings. (a) The right section of the greater omentum twisted twice in a clockwise direction (black arrow), and the infarcted distal part of the omentum (white arrow). (b) Omental vessels twisted by torsion (arrow).

DISCUSSION

Torsion of the greater omentum is an uncommon cause of acute abdomen, accounting for 1.1% of all cases of acute abdominal pain.^[6] Omental torsion is difficult to diagnose preoperatively, and accurate preoperative diagnosis is reported in only 0.6–4.8% of cases.^[7] When compared with appendicitis, this pathology has an incidence of 0.0016–0.37%, a ratio of less than 4 cases per 1000 cases of acute appendicitis.^[8] Omental torsion is primarily seen in the 30–50-year age group, with male predominance.^[1,9] However, a few cases have been reported in children.^[10] Estimated incidence of primary omental torsion in children undergoing surgery for suspected appendicitis ranges between 0.024–0.1%.^[9,11]

Omental torsion is classified as primary or secondary, the latter being far more common.^[8] Primary or idiopathic torsion is a rare condition, occurring in the absence of associated or secondary intraabdominal pathology.^[1] Eitel first described

it, in 1899, as a rare surgical cause of acute abdomen. Thus far, approximately 300 cases have been reported. Pathogenesis of primary omental torsion is considered to be wide-ranging. Adams classified the pathogenesis of primary torsion into “predisposing factors” and “precipitating factors.”^[12] Predisposing factors include obesity and anatomic variations in the arrangement of omental blood vessels. Obesity is a well-documented risk linked to primary torsion, with 1 study reporting that almost 70% of patients with omental infarction were obese.^[13] Precipitating factors include trauma and acute changes in body position.

Secondary torsion is more common and is associated with abdominal pathology, including inguinal hernia (the pathology most commonly associated), tumors in the omentum, cysts, intraabdominal inflammation, and post-surgical wound or scarring.^[14] Adams,^[12] and Barcia and Nelson^[15] emphasized the association between right inguinal hernia and secondary omental torsion.

No anatomic cause or pathology, such as obesity, adhesion, or hernia, could be determined in the present patient. A precipitating factor could be identified; the patient had sustained blunt abdominal trauma (multiple falls while skiing) only 24 hours prior to onset of symptoms. For these reasons, diagnosis of primary omental torsion was made.

Pathophysiology of omental torsion involves rotation around the long axis, resulting in vascular compromise and impaired blood supply.^[16] As the torsion progresses, arterial occlusion leads to acute hemorrhagic infarction, and eventually to necrosis of the omentum.^[14] Spontaneous reduction of omental torsion has sporadically been reported.^[17] In a large majority of reported cases, omental torsion with infarction was segmental, involving the right side of the omentum, as it is longer, heavier, and more mobile than the left side.^[18-20]

Clinical picture of primary and secondary omental torsion is similar. The earliest symptom associated with omental torsion is constant nonradiating pain of increasing severity, mostly localized in the right lower quadrant.^[21] The majority of cases present with a single episode of abdominal pain, and recurrent pain may suggest intermittent torsions.^[22] In addition, 50% of patients present with low-grade fever and moderate leukocytosis.^[4] Gastrointestinal symptoms, such as nausea, anorexia, and vomiting, are uncommon.^[5] Physical examination reveals signs of peritoneal irritation with guarding of rebound abdominal tenderness. If a large section of the omentum is involved, a mass may be palpable.^[3]

Omental torsion can mimic a variety of other acute abdominal conditions. Differential diagnosis should include acute appendicitis, cholecystitis, cecal diverticulitis, perforated duodenal ulcer, abdominal wall hematoma, and intestinal obstruction.^[9,23] In women of reproductive age, salpingitis, ovarian cyst torsion, and ectopic pregnancy should also be considered. In children, differential diagnosis should also include inflammation of the Meckel's diverticulum, as well as mesenteric adenitis.^[9] Finally, torsion of accessory spleen is another diagnostic possibility, as an accessory spleen, when present, usually resides inside the omentum.

Abdominal ultrasound is important in the exclusion of other acute conditions, and usually shows an ovoid or cake-like hyperechoic mass adherent to the peritoneum. CT scan can easily differentiate omental torsion from acute cholecystitis, appendicitis, and cecum diverticulitis. Classic signs of omental torsion on CT scan are hazy, but may include the whirl sign of a fatty mass with concentric linear strands in the greater omentum. Balthazar et al. showed that magnetic resonance imaging (MRI) was effective, even when omental torsion was complicated by bleeding or development of abscess.^[24] However, because CT scan is the gold standard diagnostic modality in patients presenting with acute abdomen,^[23] the need for MRI to establish a diagnosis of omental torsion is rare.

Once diagnosed, omental torsion should be surgically managed. Surgical resection of the affected omentum, possibly achieved via laparoscopy, is the treatment of choice.^[25,26] Surgery may also offer definitive diagnosis, if not established preoperatively. Advantages of laparoscopy include complete examination of the abdominal cavity to confirm diagnosis, in addition to the benefits of minimal-access surgery, which include decreased postoperative pain and wound-related complications.^[27,28] Laparoscopy was presently successfully performed, without the need for open conversion.

Alternative to surgery, conservative management of omental torsion has been proposed for patients who are hemodynamically stable.^[5] In this event, oral analgesics, anti-inflammatory drugs, and prophylactic antibiotics are administered, though patient selection should include a careful imaging workup to exclude other acute abdominal pathologies.^[29] Patients conservatively treated may require extended use of analgesia, and may suffer from other complications, such as abscess formation and adhesions induced by the persistence of necrotic tissue in the abdomen.^[28,30,31] Regardless of these drawbacks, conservative management may succeed, particularly in patients with no associated complication.^[32-34]

Conclusion

Primary torsion of the omentum is a rare pathology, presenting as acute abdomen and mimicking acute appendicitis in a majority of cases. Preoperative diagnosis may be difficult, but can be achieved using diagnostic imaging, particularly CT scan. Laparoscopy could be considered as the first-hand surgical option, both for differential diagnosis and treatment. Conservative treatment may be offered as an option, though only after careful selection of patients.

Conflict of interest: None declared.

REFERENCES

1. Y G, R A. Omental torsion. *J Clin Diagn Res* 2014;8:NE01-2.
2. Mavridis G, Livaditi E, Baltogiannis N, Vasiliadou E, Christopoulos-Geroulanos G. Primary omental torsion in children: ten-year experience. *Pediatr Surg Int* 2007;23:879-82. [Crossref](#)
3. Scabini S, Rimini E, Massobrio A, Romairone E, Linari C, Scordamaglia R, et al. Primary omental torsion: A case report. *World J Gastrointest Surg* 2011;3:153-5. [Crossref](#)
4. Breunung N, Strauss P. A diagnostic challenge: primary omental torsion and literature review - a case report. *World J Emerg Surg* 2009;4:40.
5. Kerem M, Bedirli A, Menten BB, Sakrak O, Pala I, Oguz M. Torsion of the greater omentum: preoperative computed tomographic diagnosis and therapeutic laparoscopy. *JLS* 2005;9:494-6.
6. Aronsky D, Z'graggen K, Banz M, Klaiber C. Abdominal fat tissue necrosis as a cause of acute abdominal pain. Laparoscopic diagnosis and therapy. *Surg Endosc* 1997;11:737-40. [Crossref](#)
7. Poujade O, Ghiles E, Senasli A. Primary torsion of the greater omentum: case report-review of literature: diagnosis cannot always be performed before surgery. *Surg Laparosc Endosc Percutan Tech* 2007;17:54-5.
8. Pinedo-Onofre JA, Guevara-Torres L. Omental torsion. An acute abdomen etiology. [Article in Spanish] *Gac Med Mex* 2007;143:17-20. [Abstract]

9. Tsironis A, Zikos N, Bali C, Pappas-Gogos G, Koulas S, Katsamakias N. Acute abdomen due to primary omental torsion: case report. *J Emerg Med* 2013;44:45–8. [Crossref](#)
10. Ozbey H, Salman T, Celik A. Primary torsion of the omentum in a 6-year-old boy: report of a case. *Surg Today* 1999;29:568–9. [Crossref](#)
11. Valioulis I, Tzallas D, Kallintzis N. Primary torsion of the greater omentum in children - a neglected cause of acute abdomen? *Eur J Pediatr Surg* 2003;13:341–3. [Crossref](#)
12. Adams JT. Primary torsion of the omentum. *Am J Surg* 1973;126:102–5. [Crossref](#)
13. van Breda Vriesman AC, Lohle PN, Coerkamp EG, Puylaert JB. Infarction of omentum and epiploic appendage: diagnosis, epidemiology and natural history. *Eur Radiol* 1999;9:1886–92. [Crossref](#)
14. Borgaonkar V, Deshpande S, Rathod M, Khan I. Primary Omental Torsion Is a Diagnostic Challenge in Acute Abdomen-a Case Report and Literature Review. *Indian J Surg* 2013;75:255–7. [Crossref](#)
15. Barcia PJ, Nelson TG. Primary segmental infarction of the omentum with and without torsion. *Am J Surg* 1973;126:328–31. [Crossref](#)
16. Theriot JA, Sayat J, Franco S, Buchino JJ. Childhood obesity: a risk factor for omental torsion. *Pediatrics* 2003;112(6 Pt 1):460. [Crossref](#)
17. Saraç AM, Yeğen C, Aktan AO, Yalin R. Primary torsion of the omentum mimicking acute appendicitis: report of a case. *Surg Today* 1997;27:251–3. [Crossref](#)
18. Puylaert JB. Right-sided segmental infarction of the omentum: clinical, US, and CT findings. *Radiology* 1992;185:169–72. [Crossref](#)
19. Ceuterick L, Baert AL, Marchal G, Kerremans R, Geboes K. CT diagnosis of primary torsion of greater omentum. *J Comput Assist Tomogr* 1987;11:1083–4. [Crossref](#)
20. Hirano Y, Oyama K, Nozawa H, Hara T, Nakada K, Hada M, et al. Left-sided omental torsion with inguinal hernia. *World J Gastroenterol* 2006;12:662–4. [Crossref](#)
21. López-Colombo A, Montiel-Jarquín A, García-Carrasco M, Nava A, Arcega-Domínguez A, Martínez-Fernández R, et al. Torsion of the omentum. A rare cause of acute abdomen. *Rev Med Inst Mex Seguro Soc* 2010;48:549–52.
22. Parr NJ, Crosbie RB. Intermittent omental torsion--an unusual cause of recurrent abdominal pain? *Postgrad Med J* 1989;65:114–5. [Crossref](#)
23. Naffaa LN, Shabb NS, Haddad MC. CT findings of omental torsion and infarction: case report and review of the literature. *Clin Imaging* 2003;27:116–8. [Crossref](#)
24. Balthazar EJ, Lefkowitz RA. Left-sided omental infarction with associated omental abscess: CT diagnosis. *J Comput Assist Tomogr* 1993;17:379–81. [Crossref](#)
25. Sánchez J, Rosado R, Ramírez D, Medina P, Mezquita S, Gallardo A. Torsion of the greater omentum: treatment by laparoscopy. *Surg Laparosc Endosc Percutan Tech* 2002;12:443–5. [Crossref](#)
26. Costi R, Cecchini S, Randone B, Viola V, Roncoroni L, Sarli L. Laparoscopic diagnosis and treatment of primary torsion of the greater omentum. *Surg Laparosc Endosc Percutan Tech* 2008;18:102–5. [Crossref](#)
27. Chung SC, Ng KW, Li AK. Laparoscopic resection for primary omental torsion. *Aust N Z J Surg* 1992;62:400–1. [Crossref](#)
28. Gassner PE, Cox MR, Cregan PC. Torsion of the omentum: diagnosis and resection at laparoscopy. *Aust N Z J Surg* 1999;69:466–7. [Crossref](#)
29. Coulier B. Segmental omental infarction in childhood: a typical case diagnosed by CT allowing successful conservative treatment. *Pediatr Radiol* 2006;36:141–3. [Crossref](#)
30. Itenberg E, Mariadason J, Khersonsky J, Wallack M. Modern management of omental torsion and omental infarction: a surgeon's perspective. *J Surg Educ* 2010;67:44–7. [Crossref](#)
31. Frago AC, Pereira JM, Estevão-Costa J. Nonoperative management of omental infarction: a case report in a child. *J Pediatr Surg* 2006;41:1777–9.
32. Kepertis C, Koutsoumis G. Primary torsion of the greater omentum. *Indian Pediatr* 2005;42:613–4.
33. Rimon A, Daneman A, Gerstle JT, Ratnapalan S. Omental infarction in children. *J Pediatr* 2009;155:427–31. [Crossref](#)
34. Soobrah R, Badran M, Smith SG. Conservative management of segmental infarction of the greater omentum: a case report and review of literature. *Case Rep Med* 2010. [Crossref](#)

OLGU SUNUMU - ÖZET

Omentum majus torsiyonunun neden olduğu akut batın: Olgu raporu ve literatürün gözden geçirilmesi

Dr. Camilla Cremonini, Dr. Andrea Bertolucci, Dr. Dario Tartaglia, Dr. Francesca Menonna, Dr. Christian Galatioto, Dr. Massimo Chiarugi

Di Pisa Üniversitesi, Acil Cerrahi Bölümü, Pisa-İtalya

Omentum majusun torsiyonu akut karının nadir bir nedenidir. Etiyopatogenezine dayanarak primer ve sekonder olarak sınıflandırılabilir. Ancak, sonuçta nedene bağlı olmaksızın segmenter veya yaygın omentum nekrozu oluşacaktır. Ameliyat öncesi tanı kolay olmamasına rağmen karının ultrason ve bilgisayarlı tomografi (BT) taramaları omentum torsiyonunu düşündürülen özgün özellikleri gösterebilir. Seçilecek tedavi etkilenmiş omentumun laparoskopik rezeksiyonudur. Bu olgu sunumunda, kapsamlı literatür derlemesine ilaveten primer omentum torsiyonu bildirilmiştir.

Anahtar sözcükler: Akut batın; laparoskopi; omentum enfarkti; omentum majus; torsiyon.

Ulus Travma Acil Cerrahi Derg 2016;22(4):391–394 doi: 10.5505/tjtes.2015.74944