

Abdominal solid organ injury in trauma patients with pelvic bone fractures

Hyo-Min Kwon, M.D., Sun-Hyu Kim, M.D., Jung-Seok Hong, M.D.,
Wook-Jin Choi, M.D., Ryeok Ahn, M.D., Eun-Seog Hong, M.D.

Department of Emergency Medicine, University of Ulsan College of Medicine, Ulsan University Hospital, Ulsan, South Korea

ABSTRACT

BACKGROUND: We analyzed the clinical progression of trauma patients with pelvic bone fractures so to determine the risk factors associated with sustaining concurrent abdominal solid organ injuries.

METHODS: This study was a retrospective chart review. Subjects were categorized based on injury type: solid organ versus non-solid organ injury groups. These study groups were compared based on demographics, treatments, and clinical outcomes. Potential risk factors that may contribute to the occurrence of abdominal solid organ injury in trauma patients with pelvic bone fractures were evaluated.

RESULTS: The solid organ injury group included 17.4% of all the patients in the study (n=69). Fall from height occurred at greater distances in patients that sustained solid organ injuries as opposed to patients with non-solid organ injuries. Initial blood pressure and Revised Trauma Scores were lower in the solid organ injury group. Shock diagnosed immediately upon emergency department arrival was a risk factor for intra-abdominal solid organ injuries in trauma patients with pelvic bone fractures. Clinical prognosis for patients in the solid organ injury group was poorer and more invasive treatments were performed for patients in this group.

CONCLUSION: Traumatic pelvic fracture patient prognosis needs to be improved through early diagnosis and prompt delivery of aggressive treatments based on rapid identification of abdominal solid organ injuries.

Key words: Abdominal injuries; fractures; pelvic bones.

INTRODUCTION

Pelvic bone fractures are commonly caused by high energy external forces such as those sustained in traffic accidents or falls, and these patients are at a high risk for associated injuries.^[1-3] Pelvic bone fractures with abdominal solid organ injuries have a poorer prognosis.^[4,5] In patients with pelvic bone fractures, it is possible to overlook concurrent solid organ injury, especially if the abdominal symptoms are not severe. Diagnosing abdominal solid organ injury in the context of pelvic bone fractures is critical, as the clinical management and patient prognosis changes. Computed tomography (CT)

rather than plain X-ray or ultrasonography is the preferred method in evaluating patients with complicated injuries, especially if the injury affected the abdominal viscera.^[6-10] If CT scan can be utilized to predict the probability of having an intra-abdominal solid organ injury in patients with pelvic bone fractures, then prognosis may improve.^[11]

Previous studies have investigated the clinical progression of patients with pelvic fractures with various associated injuries.^[4,12,13] However, no studies have investigated the risks of incurring intra-abdominal solid organ injuries when pelvic bone fractures are sustained. We evaluated the clinical progression of patients that had pelvic fractures and received abdominal CT scans to determine if concurrent abdominal solid organ injury occurred. By gathering these data, we investigated the early risk factors that indicate the presence of solid organ injuries within minutes of arrival to the emergency department (ED) before obtaining precise radiologic images like CT scan.

MATERIALS AND METHODS

This is a retrospective chart review of 386 patients that presented with pelvic bone fractures from January 2000 to December 2011 to the Emergency Department at the Ulsan

Address for correspondence: Sun-hyu Kim, M.D.
290-3 Jeonha-dong Dong-gu 682-71 Ulsan, South Korea
Tel: +82-52-250-8405 E-mail: stachyl@paran.com

Qucik Response Code



Ulus Travma Acil Cerr Derg
2014;20(2):113-119
doi: 10.5505/tjtes.2014.72698

Copyright 2014
TJTES

University Hospital in Korea (Figure 1). Only patients that received CT imaging that clearly indicated the presence or absence of abdominal solid organ injuries were included in the study. Exclusion criteria were if the patient did not receive an abdominal CT scan, if the presence or absence of abdominal solid organ injury could not be determined from CT imaging, and if the CT imaging reports could not be procured.

Study subjects were categorized depending on CT findings: solid organ injury group who had abdominal solid organ injury and non-solid organ injury group who had not abdominal solid organ injury. Pelvic bone fractures were classified into lateral compression (LC) type I, II or III; antero-posterior compression (APC) type I, II or III; vertical shear (VS) type, and combined type according to the Young-Burgess pelvic bone fractures classification scheme. To differentiate pelvic bone fractures based on stability, LC I and APC I were defined as stable pelvic fractures while the other classifications were unstable.^[14,15] A licensed radiologist determined abdominal solid organ injury severity based on CT scan results for the liver, spleen, kidneys, pancreas, and adrenal glands in accordance with the American Association for the Surgery of Trauma (AAST) organ injury scales.

Demographic and clinical data included age, sex, mechanism of injury, pelvic bone fracture stability (stable or unstable), initial blood pressure taken at the ED, and the Revised Trauma Score (RTS) to determine the physiologic severity grade. The Abbreviated Injury Scale (AIS) and the Injury Severity Score (ISS) were determined for all injuries and were utilized to assess the injury severity shortly following ED treatment. Complete blood count and arterial blood gas samples that were taken immediately after ED presentation were evaluated. Transfusion within 24 hours of ED presentation, shock occurrence at the time of ED presentation and shock within 24 hours after ED arrival were also evaluated. Shock was

Table 1. Abdominal solid organ injuries in patients with pelvic bone fractures

Solid organ injury type	n	%*
Single organ injury	48	69.6
Liver	21	30.4
Spleen	10	14.5
Kidney	12	17.4
Pancreas	2	2.9
Adrenal gland	3	4.3
Multiple organ injury	21	30.4
Liver + spleen	3	4.3
Liver + kidney	5	7.2
Liver + pancreas	3	4.3
Liver + adrenal gland	2	2.9
Spleen + kidney	5	7.2
Spleen + adrenal gland	1	1.4
Kidney + pancreas	1	1.4
Liver + spleen + kidney	1	1.4

*: Percentages were calculated from a total of 69 patients that had solid viscera injuries.

defined as a systolic blood pressure below or equal to 90 mmHg. Clinical management, subsequent admission to the intensive care unit (ICU) or to the general medicine ward, and mortality were evaluated for all patients. This study was reviewed and approved by the Institutional Review Board.

Clinical progression and outcomes were compared between the solid organ injury and non-solid organ injury groups via the chi-squared test and Student's t-test. Upon arriving to the ED and before CT scanning, certain clinical findings were

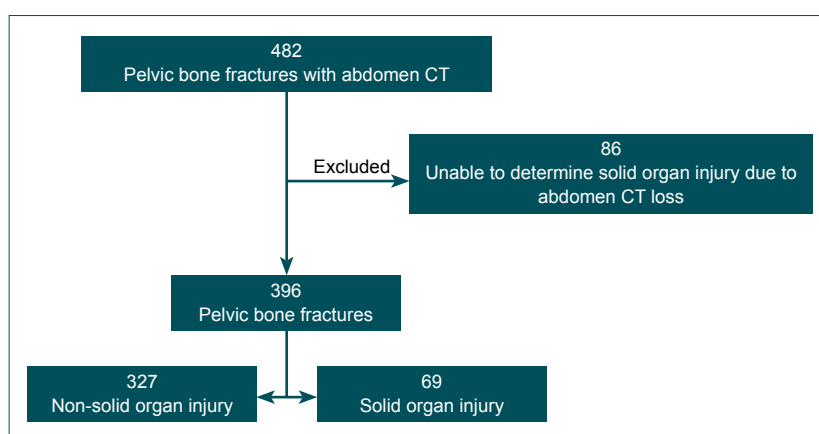


Figure 1. Study subject selection. Of all 482 patients that presented to the ED with pelvic bone fractures and had received an abdominal CT scan, 396 patients were included in the study. A total of 86 patients were excluded from the study because the nature of their abdominal organ injury could not be determined due to a loss of CT scan.

identified as statistically significant via univariate analysis. Then a bivariate logistic regression was performed to evaluate early risk factors associated with abdominal solid organ injury in patients with pelvic bone fractures. All statistical analyses were performed using SPSS version 19.0 software (SPSS, Chicago, IL, USA), and a p-value less than 0.05 was statistically significant.

RESULTS

On average the study subjects were 43.2 ± 18.9 (mean \pm standard deviation) years-old, and the majority of the patients were male at 58.6%. The solid organ injury group comprised 17.4% of all patients. For patients that sustained a solid organ injury, 49.3% suffered a liver injury (n=34), 34.8% had an injury to the kidney (n=24), 29.0% experienced a spleen injury (n=20), 8.7% sustained an injury to the pancreas (n=6), and 8.7% had an adrenal gland injury (n=6). If only one internal organ was injured, the liver, kidney and spleen were the most commonly harmed in isolation at 30.4% (n=12), 17.4% (n=12), and 14.5% (n=10), respectively. If multiple abdominal viscera sustained injuries, then the liver, spleen and kidney were also the most commonly involved at 7.2% (n=5) (Table 1). Subjects in the solid organ injury group were younger in

comparison to the other groups. The distribution of males and females did not differ significantly between the groups.

Patients in the non-solid organ injury group mainly experienced trauma due to traffic accidents at 57.5% (n=188) and were more often pedestrians (n=106) as opposed to drivers (n=25) or passengers (n=15). In the solid organ injury group, injuries due to traffic accidents occurred in 69.6% patients (n=48). Injuries sustained from falling from height comprised 20.3% of patients in the solid organ injury group (n=14) versus 20.5% of patients in the non-solid organ injury group (n=65). On average, patients fell greater distances in the solid organ injury group at 7.3 m as opposed to the non-solid organ injury group that fell an average of 4.4 m. Unstable pelvic bone fractures were evident in more than 60% of patients in both solid and non-solid organ injury groups.

Initial blood pressure and RTS were decreased, and the presence of shock upon presenting to the ED was more prevalent in the solid organ injury group (Table 2). Shock upon ED presentation was identified as an early risk factor for abdominal solid organ injury in trauma patients with pelvic bone fractures (Table 3). On average, ISS was higher in the solid organ injury group, but initial hemoglobin levels did not differ

Table 2. Patient demographics and clinical characteristics

	Non-solid organ injury (n=327)			Solid organ injury (n=69)			p
	n	%	Mean \pm SD	n	%	Mean \pm SD	
Age, years			44.2 \pm 18.9			38.4 \pm 18.0	0.022
Sex							0.134
Male	186	56.9		46	66.7		
Female	141	43.1		18	33.3		
Injury mechanism							0.075
Traffic accident	188	57.5		48	69.6		
Pedestrian	106	32.4		26	37.7		
Driver	25	7.6		7	10.1		
Fellow passenger	15	4.6		8	11.6		
Motorcycle	42	12.8		7	10.1		
Fall from height	67	20.5		14	20.3		
Other	72	22.0		7	10.1		
Height from fall (m)			4.4 \pm 3.5			7.3 \pm 4.1	0.008
Pelvic bone fracture type							0.618
Stable	129	39.4		25	36.2		
Unstable	198	60.6		44	63.8		
Systolic blood pressure (mmHg)			119.1 \pm 26.1			104.6 \pm 27.1	<0.001
Diastolic blood pressure (mmHg)			76.8 \pm 43.6			64.0 \pm 20.7	0.018
Revised trauma score			11.7 \pm 1.2			11.0 \pm 1.9	0.006
Shock at ED presentation	35	10.7		23	33.3		<0.001

ED: Emergency department; SD: Standard deviation.

Table 3. Early clinical findings associated with abdominal solid organ injuries

	Odds Ratio	95% Confidence Interval	p
Systolic blood pressure	0.994	0.979 - 1.009	0.406
Revised trauma score	0.955	0.773 - 1.181	0.673
Shock at emergency department presentation	3.049	1.245 - 7.463	0.015

*p-values were computed by multiple logistic regression analysis controlling for age and gender.

Table 4. Outcomes for pelvic fracture patients with either solid or non-solid organ injuries

	Non-solid organ injury (n=327)			Solid organ injury (n=69)			p
	n	%	Mean±SD	n	%	Mean±SD	
Injury Severity Score			15.8±8.8			27.9±9.9	<0.001
Initial arterial blood pH			7.39±0.09			7.30±0.10	<0.001
Initial hemoglobin (g/dL)			12.4±2.1			12.1±2.4	0.276
Initial prothrombin time INR			1.08±0.16			1.23±0.29	<0.001
24-hour packed red blood cells			1.24±3.29			6.41±11.90	0.001
Transfusion packed red blood cells within 24 hours	78	23.9		39	56.5		<0.001
Treatment							<0.001
Conservative	312	95.4		51	73.9		
Invasive	15	4.6		18	26.1		
Operative	6	1.9		2	3.3		
Embolization	6	1.9		11	15.9		
Operative + embolization	3	0.9		5	7.2		
Intensive care unit stay, days			1.8±4.6			7.4±10.0	<0.001
Mortality	10	3.1		8	11.6		0.006
Hypovolemic shock	3	0.9		3	4.3		
Septic shock	3	0.9		2	2.9		
Brain lesion	4	1.3		1	1.4		
Respiratory failure	0	0.0		1	1.4		
Multi-organ failure	0	0.0		1	1.4		

INR: International normalized ratio.

between solid and non-solid organ injury groups. Initial arterial blood gas pH was decreased and prothrombin time was prolonged in the solid organ injury group. Packed red blood cell transfusions were performed more often in patients with solid organ injuries within 24 hours of arriving to the ED as compared to the non-solid organ injury group (6.4 vs. 1.2, respectively; $p < 0.001$).

Invasive treatments including surgery and arterial embolization were more commonly performed, ICU stays were longer and mortality was higher in the solid organ injury group (Table 4). Surgical operations such as bowel or mesentery

repairs were often performed in the non-solid organ injury group, but splenectomies or nephrectomies occurred more commonly in the solid organ injury group. The internal iliac and renal arteries were the most frequently injured vessels in the solid organ injury group. Surgery following arterial embolization was performed in 2 patients in the non-solid organ group and in 4 patients in the solid organ injury group (Table 5).

DISCUSSION

The extent to which pelvic bone fractures contribute to poorer prognosis in trauma patients remains unclear.^[1-5]

Table 5. Invasive treatments for pelvic bone fractures with either solid or non-solid organ injuries

	Non-solid organ injury (n=15/327)	Solid organ injury (n=18/69)
Operation (n)	6 Gastric perforation repair, 1 Colon perforation repair, 1 Small bowel resection, 3 Mesentery repair, 1	2 Splenoectomy, 1 Splenoectomy + nephrectomy, 1
Arterial embolization (n)	6 Internal iliac artery, 1 hepatic artery, 1 Cystic artery, 1 Gluteal artery, 1 Internal pudendal artery, 1 Gluteal + femoral artery, 1	11 Internal iliac artery, 4 Renal artery, 3 Hepatic artery, 1 Splenic artery, 1 Internal iliac + lumbar artery, 1 Renal + hepatic artery, 1
Arterial embolization + operation (n)	3 Internal pudendal artery + bladder, diaphragm repair 1 Internal iliac artery + bladder repair, 1 Bladder repair + internal iliac artery, 1	5 Internal iliac artery + bladder repair, 1 Internal iliac artery + bowel repair, colostomy, 1 Gluteal artery + exploratory laparotomy, 1 Hepatic artery + small bowel resection, 1 Small bowel repair + internal iliac artery, 1

However, patients with pelvic bone fractures with concurrent internal organ injuries, hypotension, head injuries, and lower hemoglobin levels have worse outcomes.^[4,13,16] Elevated ISS in patients with pelvic bone fractures and internal organ injuries rather than stability type of pelvic bone fractures, is associated with a higher risk for mortality.^[13] A previous study reported that pelvic bone fracture instability does not increase the likelihood of abdominal solid organ injury. Age, mechanism of injury, hypotension, and injury to the chest are all prognostic factors of mortality.^[17] Therefore, patients with abdominal solid organ injuries may have less favorable prognoses as compared to patients without such injuries. We found that patients with internal organ injuries had worse prognoses and higher mortality rates, longer ICU stays, elevated ISS, relatively more transfusions, and a greater likelihood of receiving surgery and/or arterial embolization. It is imperative to rapidly diagnose injury to the abdominal solid organ in the setting of pelvic bone fractures so to deliver appropriate treatment, and our data suggest that patients presenting with shock are at even higher risk of having abdominal solid organ injuries.

Patient prognosis after sustaining a fall from height depends on the distance of the fall.^[18-20] The greater the distance that the patient falls, the more likely the patient sustains solid organ injuries based on univariate analysis in our study (odds ratio 1.188, 95% confidence interval (CI) 1.032-1.368, $p=0.016$). Yet, fall injuries only constituted 20% of all injury mechanisms in this study, and so estimating the risk of experiencing concurrent solid organ injuries via multivariate regression was limited.

There is controversy regarding the clinical utility of obtaining abdominal CT scans selectively only for patients that complain of abdominal tenderness, cases of suspected hemo-peritoneum, abdominal ultrasonography revealing suspected injury to the viscera, hematuria, or routinely for all trauma patients that were exposed to great external forces so to determine whether the patient experienced concurrent abdominal organ injuries with pelvic bone fractures.^[11,21-24] Selective utilization of CT scanning has been advocated for due to radiation exposure and cost.^[22-24] However, it has been reported that the treatment plan was changed in 6.4% of cases

due to diagnoses determined from CT imaging.^[11] It is difficult to conclusively state whether CT scans should be performed selectively or routinely so to better diagnose abdominal solid viscera injury in patients with pelvic bone fractures because of the limitations of our study. Although, routine abdominal CT scans are preferred when working up patients with pelvic bone fractures at Ulsan University Hospital. In this study 17% (n=69) of the patients with pelvic bone fractures were diagnosed with internal solid organ injury on abdominal CT imaging. It may be useful to perform abdominal CT scans routinely in patients with pelvic bone fractures, so to identify the presence of organ injuries. Since this study only included subjects that received abdominal CT scans to determine the presence of pelvic bone fractures, this study has limited power in estimating the prevalence of abdominal solid organ injury. Further studies are needed to determine whether abdominal CT scans should be utilized in diagnosing abdominal solid organ injuries in patients with pelvic bone fractures.

Injury to abdomen in the pelvic area is associated with pelvic fractures, and the viscera that are most frequently injured are the liver, kidney and spleen, in order of decreasing prevalence of injury.^[4] These organs were also commonly injured in our study. It is very important when treating trauma patients to determine early on whether further diagnostic methods and treatments are necessary in the ED based on clinical findings such as patient history, initial physical examination, and vital signs. Severe pelvic bone fractures may be easily detected on physical examination. Yet, it is difficult to discern abdominal solid organ injury because the viscera, unlike bone, are not as easily palpated in physical examination. Especially for trauma patients that present with shock to the ED, it is imperative to diagnose abdominal solid organ injury quickly so to expedite the delivery of appropriate treatment interventions. Pelvic packing as well as arterial embolization are effective interventions that control bleeding for hemodynamically unstable patients with pelvic fractures.^[25,26] However, pelvic packing was not performed in this study, so we did not evaluate the efficacy of pelvic packing in patients with unstable pelvic fractures.

Limitations of this study are that it is a retrospective chart review and that it was conducted with data from one university hospital. Also, the patient charts did not reveal the exact indications for taking the abdominal CT scans for patients with pelvic bone fractures during the study period. Since abdominal solid organ injury may not have been confirmed if CT scanning was not performed, in spite of the presence of traumatic pelvic bone fractures, there may have cases in which injury to the viscera was missed. Although, abdominal CT scans were conducted in the majority of the patients with suspected abdominal injuries upon presenting to the ED, making it less likely that such a diagnosis was overlooked. Also, the average age of patients with solid organ injuries was generally younger in our study. This may be due to the fact that the study population, which was comprised of physically active and young individuals, was more likely to engage in high

risk activities that predispose them to severe traumatic insults. Therefore, the overrepresentation of this age group in our study makes it more difficult to estimate the relationship of age with the occurrence of solid organ injuries in pelvic fracture patients. These limitations may be overcome with further prospective, multicenter studies.

Conclusion

There is a need to improve prognosis by diagnosing abdominal solid viscera injury early such that the appropriate aggressive treatments may be rapidly administered to trauma patients with shock and pelvic bone fractures in the ED.

Conflict of interest: None declared.

REFERENCES

1. Manson TT, Nascone JW, Sciadini MF, O'Toole RV. Does fracture pattern predict death with lateral compression type 1 pelvic fractures? *J Trauma* 2010;69:876-9.
2. Abrassart S, Stern R, Peter R. Morbidity associated with isolated iliac wing fractures. *J Trauma* 2009;66:200-3.
3. Schulman JE, O'Toole RV, Castillo RC, Manson T, Sciadini MF, Whitney A, et al. Pelvic ring fractures are an independent risk factor for death after blunt trauma. *J Trauma* 2010;68:930-4.
4. Gustavo Parreira J, Coimbra R, Rasslan S, Oliveira A, Fregoneze M, Mercadante M. The role of associated injuries on outcome of blunt trauma patients sustaining pelvic fractures. *Injury* 2000;31:677-82.
5. Giannoudis PV, Grotz MR, Tzioupis C, Dinopoulos H, Wells GE, Bouamra O, et al. Prevalence of pelvic fractures, associated injuries, and mortality: the United Kingdom perspective. *J Trauma* 2007;63:875-83.
6. Miller MT, Pasquale MD, Bromberg WJ, Wasser TE, Cox J. Not so FAST. *J Trauma* 2003;54:52-60.
7. Poletti PA, Wintermark M, Schnyder P, Becker CD. Traumatic injuries: role of imaging in the management of the polytrauma victim (conservative expectation). *Eur Radiol* 2002;12:969-78.
8. Self ML, Blake AM, Whitley M, Nadalo L, Dunn E. The benefit of routine thoracic, abdominal, and pelvic computed tomography to evaluate trauma patients with closed head injuries. *Am J Surg* 2003;186:609-14.
9. Shanmuganathan K, Mirvis SE, Sherbourne CD, Chiu WC, Rodriguez A. Hemoperitoneum as the sole indicator of abdominal visceral injuries: a potential limitation of screening abdominal US for trauma. *Radiology* 1999;212:423-30.
10. Exadaktylos AK, Sclabas G, Schmid SW, Schaller B, Zimmermann H. Do we really need routine computed tomographic scanning in the primary evaluation of blunt chest trauma in patients with "normal" chest radiograph? *J Trauma* 2001;51:1173-6.
11. Deunk J, Brink M, Dekker HM, Kool DR, van Kuijk C, Blickman JG, et al. Routine versus selective computed tomography of the abdomen, pelvis, and lumbar spine in blunt trauma: a prospective evaluation. *J Trauma* 2009;66:1108-17.
12. Ali J, Ahmadi KA, Williams JI. Predictors of laparotomy and mortality in polytrauma patients with pelvic fractures. *Can J Surg* 2009;52:271-6.
13. Lunsjo K, Tadros A, Hauggaard A, Blomgren R, Kopke J, Abu-Zidan FM. Associated injuries and not fracture instability predict mortality in pelvic fractures: a prospective study of 100 patients. *J Trauma* 2007;62:687-91.
14. Manson T, O'Toole RV, Whitney A, Duggan B, Sciadini M, Nascone J.

- Young-Burgess classification of pelvic ring fractures: does it predict mortality, transfusion requirements, and non-orthopaedic injuries? *J Orthop Trauma* 2010;24:603-9.
15. Lefavre KA, Padalecki JR, Starr AJ. What constitutes a Young and Burgess lateral compression-I (OTA 61-B2) pelvic ring disruption? A description of computed tomography-based fracture anatomy and associated injuries. *J Orthop Trauma* 2009;23:16-21.
 16. Young JW, Burgess AR, Brumback RJ, Poka A. Pelvic fractures: value of plain radiography in early assessment and management. *Radiology* 1986;160:445-51.
 17. Gabbe BJ, de Steiger R, Esser M, Bucknill A, Russ MK, Cameron PA. Predictors of mortality following severe pelvic ring fracture: results of a population-based study. *Injury* 2011;42:985-91.
 18. Velmahos GC, Demetriades D, Theodorou D, Cornwell EE 3rd, Belzberg H, Asensio J, et al. Patterns of injury in victims of urban free-falls. *World J Surg* 1997;21:816-21.
 19. Ong A, Iau PT, Yeo AW, Koh MP, Lau G. Victims of falls from a height surviving to hospital admission in two Singapore hospitals. *Med Sci Law* 2004;44:201-6.
 20. Hingson R, Howland J. Alcohol as a risk factor for injury or death resulting from accidental falls: a review of the literature. *J Stud Alcohol* 1987;48:212-9.
 21. Salim A, Sangthong B, Martin M, Brown C, Plurad D, Demetriades D. Whole body imaging in blunt multisystem trauma patients without obvious signs of injury: results of a prospective study. *Arch Surg* 2006;141:468-75.
 22. Grieshop NA, Jacobson LE, Gomez GA, Thompson CT, Solotkin KC. Selective use of computed tomography and diagnostic peritoneal lavage in blunt abdominal trauma. *J Trauma* 1995;38:727-31.
 23. Garber BG, Bigelow E, Yelle JD, Pagliarello G. Use of abdominal computed tomography in blunt trauma: do we scan too much? *Can J Surg* 2000;43:16-21.
 24. Richards JR, Derlet RW. Computed tomography and blunt abdominal injury: patient selection based on examination, haematocrit and haematuria. *Injury* 1997;28:181-5.
 25. Osborn PM, Smith WR, Moore EE, Cothren CC, Morgan SJ, Williams AE, et al. Direct retroperitoneal pelvic packing versus pelvic angiography: A comparison of two management protocols for haemodynamically unstable pelvic fractures. *Injury* 2009;40:54-60.
 26. Tosounidis TI, Giannoudis PV. Pelvic fractures presenting with haemodynamic instability: treatment options and outcomes. *Surgeon* 2013;11:344-51.

KLİNİK ÇALIŞMA - ÖZET

Karında solid organ yaralanmasıyla ilişkili pelvis kemiği kırıkları

Dr. Hyo-Min Kwon, Dr. Sun-Hyu Kim, Dr. Jung-Seok Hong, Dr. Wook-Jin Choi, Dr. Ryeok Ahn, Dr. Eun-Seog Hong

Ulsan Üniversitesi Tıp Fakültesi, Ulsan Üniversite Hastanesi, Acil Tıp Kliniği, Ulsan, Güney Kore

AMAÇ: Bu çalışmada, pelvis kemiği kırıklarının klinik özellikleri ve prognozu ile eşlik eden karında solid organ yaralanmasının oluşu ve risk faktörleri incelendi.

GEREÇ VE YÖNTEM: Geriye dönük olarak tıbbi kayıtlar toplandı. Denekler, demografik özellikler, sonuçlar ve prognozu karşılaştırma amacıyla karında solid organ travması açısından solid organ yaralanması olan ve olmayan gruplara ayrıldı. Pelvis kemiği kırıkları olan hastalarda karında solid organ yaralanmasının oluşu açısından risk faktörleri değerlendirildi.

BULGULAR: Solid organ yaralanması olan grupta 69 (%17.4) hasta vardı. Solid organ yaralanması olmayan gruba göre solid organ yaralanması olan grupta yüksekten düşüşler daha fazlaydı. Solid organ travması grubunda başlangıçtaki kan basıncı ölçümleri ve gözden geçirildi, travma skorları daha düşük bulundu. Acil servise gelişin hemen sonrası şok, pelvis kemiği kırıkları olan travma hastalarında karında solid organ yaralanması için bir risk faktörüydü. Solid organ yaralanması grubu kötü bir prognoza sahip olup bu grupta daha invaziv tedavi uygulandı.

TARTIŞMA: Şok ve pelvis kemiği kırıkları kuşkusuz ile acil servise gelen travma hastalarında prognozun karında solid organ yaralanmasının erkenden öngörüsüne göre erken tanı ve agresif tedavi ile iyileştirilmesi gerekir.

Anahtar sözcükler: Abdominal yaralanmalar; kırıklar; pelvis kemikleri.

Ulus Travma Acil Cerr Derg 2014;20(2):113-119 doi: 10.5505/tjtes.2014.72698