

Common carotid artery injury caused by a camel bite: case report and systematic review of the literature

Fikri M Abu-Zidan, M.D.,¹ Saleh Abdel-Kader, M.D.,² Radwan El Hussein, M.D.²

¹Trauma Group, Faculty of Medicine and Health Sciences, UAE University, Al-ain, UAE

²Department of Surgery, Vascular Surgery Unit, Al-ain Hospital, Al-ain, UAE

ABSTRACT

A 25-year-old man was bitten in the neck by an aggressive camel, causing three small puncture wounds. The left carotid pulse of the patient was weakly palpated. Angiography showed irregular dissection of the distal part of the left common carotid artery. Neck exploration confirmed the findings. An interposition autogenous saphenous vein graft was performed successfully. The patient was discharged home in good condition. We have systematically reviewed the literature on this topic, and only four other similar cases were reported previously. Although camel bite wounds are small, they may penetrate deeply, causing serious injuries to the neck structures including the major vessels. Care should be taken when approaching male camels during the rutting season.

Key words: Camel; carotid artery; injury; neck bite; trauma.

INTRODUCTION

Animal bites are an underestimated public health problem worldwide. In Australia, nearly 2% of the population is bitten by animals every year; more than 80% by dogs.^[1] Biting of the neck, which is crowded with vital structures, may lead to major vascular and neurological injuries. We have previously reported the devastating injuries caused by camel bites to the neck.^[2] Major vascular injuries of the neck caused by camel bites are extremely rare. Herein, we report a patient who sustained a common carotid artery (CCA) injury caused by a camel bite, and we systematically review the literature on this topic.

CASE REPORT

A 23-year-old Pakistani camel caregiver presented to the Emergency Department of Al-Ain Hospital two hours after being bitten in the neck by an aggressive camel. On examination, the patient was fully conscious and talking. His blood

pressure was 140/80 mmHg, pulse rate 78 bpm, and body temperature 37.8 °C. Three small puncture wounds to the left side of the neck were seen. Surgical emphysema of the neck and upper chest were felt on palpation. The left carotid artery pulse was weak. Carotid bruit could not be heard. The patient could not abduct his left arm. He received tetanus toxoid intramuscularly and was admitted to the hospital.

Computerized tomography (CT) scan of the neck with intravenous and oral contrast showed non-visualization of the left CCA and surgical emphysema of the neck. There was no leakage of the oral contrast. CT angiography showed that the left CCA was non-contrasted from its origin up to the bifurcation (Figure 1a). Contrast magnetic resonance (MR) angiogram showed intimal tear of the left CCA 2-3 cm below the bifurcation (Figure 1b). Carotid angiogram confirmed the findings. The left CCA was partially patent. Fibro-optic laryngoscopy was normal.

Exploration of the neck showed a thrombus and dissection in the distal part of the left CCA 2 cm below the bifurcation. The stump pressure of the left internal carotid artery was 70/40 mmHg. The artery was opened at the site of the hematoma, and a circumferential intimal tear and overlying thrombus were found (Figure 1c). The section of the left CCA containing the intimal tear was excised, and an interposition autogenous saphenous vein graft was performed. A suction drain was inserted, and the wound was primarily closed in layers. The patient was given intravenous ceftriaxone sodium (1 g 12-hourly) and metronidazole (500 mg 8-hourly) for one week.

Address for correspondence: Fikri M Abu-Zidan, M.D.

PO Box 17666 Al-ain, United Arab Emirates

Tel: 009713 7137579 E-mail: fabuzidan@uaeu.ac.ae

Qucik Response Code



Ulus Travma Acil Cerr Derg
2014;20(1):59-62
doi: 10.5505/tjtes.2014.69822

Copyright 2014
TJTES

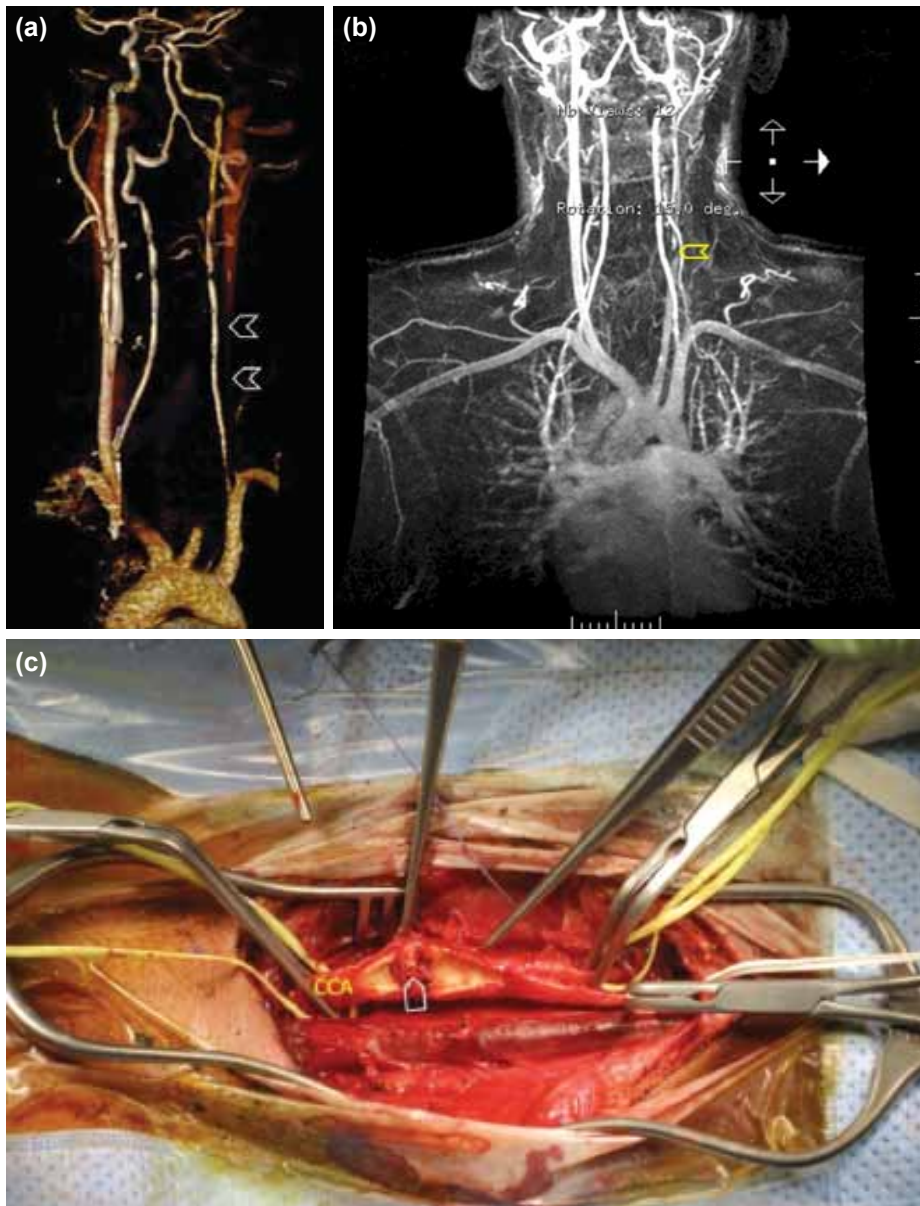


Figure 1. (a) CT angiography showing that the left CCA was non-contrasted from its origin up to the carotid bifurcation (arrow heads) and a good back flow in the circle of Willis. (b) MR angiogram with contrast showing intimal tear in the left CCA 2-3 cm below the bifurcation (arrow head). (c) Arteriotomy showing dissection of the distal part of the left CCA, about 2 cm below the bifurcation.

Follow-up Doppler ultrasound study showed good flow in the left common, internal, and external carotid arteries. Nerve conduction velocity and electromyography showed neurapraxia of the left brachial plexus including the left axillary, musculocutaneous and supra-scapular nerves. The patient received physiotherapy for the brachial plexus injury. The patient had a smooth postoperative recovery, and was scheduled to be discharged on the 10th postoperative day. Nevertheless, he was kept in the hospital for social reasons and was discharged home on day 20 on aspirin tablets, 100 mg daily. A follow-up at one month showed improvement in the left arm abduction.

DISCUSSION

Although the principles of surgical management of carotid artery injuries are well-known, camel bites as a cause of these injuries are extremely rare and unique. A search of Medline revealed only five cases of major vascular injuries of the neck caused by camel bites, including the present case (Table 1).^[2-5] Three of these were reported from our hospital. This indicates that these injuries are under-reported because the majority occur in developing countries with a lack of training in research and medical writing. The estimated incidence of camel bite injuries requiring hospitalization in our city is 1.5 per 100,000 inhabitants per year.^[6]

Table I. Summary of reported cases in the literature of major vascular injuries of the neck caused by camel bites

Author	Age (yrs)	Sex	Mechanism of injury	Clinical presentation	Wound	Injuries	Management	Outcome
Janjua KJ ^[3] (1993)	52	Male	Bitten by a camel, lifted up and thrown aside	Swollen left shoulder; absent left radial pulse	Bite mark on the left shoulder without penetration	Left subclavian artery occlusion, fractured clavicle, fractured ribs (1-3) left side	Gortex graft bridging a 5 cm loss of the subclavian artery	Complete recovery
Nawaz et al. ^[4] (2005)	11	Male	Camel bite	Neck wound	Four puncture wounds on left side of the neck, ear and cheek	Intimal tear of the left internal carotid artery without occlusion, fractured mandible	Interposition venous graft bridging a 2 cm defect ORIF of mandible	Complete recovery
Shehu et al. ^[5] (2007)	30	Male	Camel bite	Loss of consciousness, right hemiparesis	Four puncture wounds on the left side of the neck	Left carotid artery occlusion, left brain infarction	Conservative	Right hemiparesis
Abu-Zidan et al. ^[2] (2007)	45	Male	Bitten by a camel, lifted up and thrown to the ground	Unconscious, dyspnea, shock, right hemiparesis	Lacerated wounds of <2 cm on the left side of the neck	Left carotid artery injury without occlusion, massive left brain infarction, fractured cervical spine, massive left hemothorax, fractured clavicle and ribs (1-2) on left side	Conservative	Exitus
Present case	23	Male	Camel bite	Neck wound, inability to abduct the left arm	Puncture wounds on left side of the neck	Intimal tear of the left common carotid artery, left brachial plexus injury	Interposition venous graft bridging a 3 cm defect	Mild paresis of left brachial plexus

ORIF: Open reduction/internal fixation.

The mechanism of camel bite injury is complex, including penetrating and crushing injuries by the camel teeth, and blunt injuries when patients are lifted and thrown to the ground.^[2] More than 20% of the patients who had camel bites were lifted by the camel's teeth and thrown aside.^[6] Two of the five patients in Table I were lifted and thrown to the ground after being bitten. The increased complexity of the mechanism of injury will increase its severity.^[7]

All patients in Table I were males, with a median age (range) of 30 (11-54) years. Similarly, in a prospective study of 212 camel-related injuries from the United Arab Emirates, all the patients were male.^[8]

The presented patient was injured in January. More than 70% of camel bites occur during the rutting season, which is between November and March, during which the male camels become irritable and difficult to handle.^[6,9] An air-filled pink

diverticulum called the "dulla", reaching up to 25 cm in length, protrudes from the mouth of a sexually active camel.^[6]

The camel bites thin areas of the body, including the upper limbs and neck. About 8% of camel bites involve the neck.^[8] Despite the small size of the puncture wounds of these bites, they penetrate deeply, causing serious injuries to deeper structures, as shown in Table I. Of these five patients, one patient died, one had right-sided hemiparesis, and another had left brachial plexus paresis. Three patients underwent successful interposition grafting of major vascular injuries of the neck. Interestingly, all wounds were on the left side of the neck, which may be related to the behavior of the camel when it attacks the neck of humans.

Selective surgery for penetrating injury of the neck is accepted in civilian trauma centers with proper diagnostic facilities.^[10,11] Hard signs serving as reliable indicators for carotid

artery injury include an expanding or pulsatile hematoma, absence of pulse, presence of bruit, and an active external bleeding. Patients who are hemodynamically stable can be observed clinically and evaluated using radiological investigations.^[11] The carotid pulse in our patient was weak and not completely absent. Since he was hemodynamically stable, we decided to do a workup before surgery. The best option for surgical repair of the carotid artery injury, if there is any possibility of tension, is an autogenous saphenous vein graft.^[11]

We treated our patient with tetanus toxoid and antibiotics, similar to Saxena et al.,^[12] who reported the management of the largest series of camel bites in the literature and did not report any case of rabies in their study. Nevertheless, we think that anti-rabies prophylaxis for camel bites should be given in the future because of the risk of rabies.^[13]

In conclusion, although camel bite wounds are small, they may penetrate deeply, causing serious injuries to neck structures, including the major vessels. Care should be taken when approaching male camels during the rutting season. Rutting camels are recognized by the pink "dulla" protruding from their mouths.

Conflict of interest: None declared.

REFERENCES

- MacBean CE, Taylor DM, Ashby K. Animal and human bite injuries in Victoria, 1998-2004. *Med J Aust* 2007;186:38-40.
- Abu-Zidan FM, Ramdan K, Czechowski J. A camel bite breaking the neck and causing brain infarction. *J Trauma* 2007;63:1423. [CrossRef](#)
- Janjua KJ. Camel bite injury: an unusual report of left shoulder mutilation with major vascular and bony injuries. *Injury* 1993;24:686-8. [CrossRef](#)
- Nawaz A, Matta H, Hamchou M, Jacobsz A, Al Salem AH. Camel-related injuries in the pediatric age group. *J Pediatr Surg* 2005;40:1248-51.
- Shehu BB, Nasiru JI, Mahmud MR, Laseini A, Saidu SA. Carotid occlusion and cerebral infarction from camel bite: case report. *East Afr Med J* 2007;84:550-2.
- Abu-Zidan FM, Eid HO, Hefny AF, Bashir MO, Branicki F. Camel bite injuries in United Arab Emirates: a 6 year prospective study. *Injury* 2012;43:1617-20. [CrossRef](#)
- Abu-Zidan FM, Rao S. Factors affecting the severity of horse-related injuries. *Injury* 2003;34:897-900. [CrossRef](#)
- Abu-Zidan FM, Hefny AF, Eid HO, Bashir MO, Branicki FJ. Camel-related injuries: prospective study of 212 patients. *World J Surg* 2012;36:2384-9. [CrossRef](#)
- Food and agriculture organization of the United Nations. A manual for the primary animal health care worker: chapter 7: camels, llamas and alpacas. http://www.fao.org/docrep/T0690E/t0690e09.htm#chapter_7. Accessed 1st August 2012.
- Ordog GJ, Albin D, Wasserberger J, Schlater TL, Balasubramaniam S. 110 bullet wounds to the neck. *J Trauma* 1985;25:238-46. [CrossRef](#)
- Asensio JA, Vu T, Mazzini FN, Herrerias F, Pust GD, Sciarretta J, et al. Penetrating carotid artery: uncommon complex and lethal injuries. *Eur J Trauma Emerg Surg* 2011;37:429-37. [CrossRef](#)
- Saxena PS, Sharma SM, Singh M, Saxena M. Camel bite injuries. *J Indian Med Assoc* 1982;79:65-8.
- Bloch N, Diallo I. A probable outbreak of rabies in a group of camels in Niger. *Vet Microbiol* 1995;46:281-3. [CrossRef](#)

OLGU SUNUMU - ÖZET

Deve ısırığının neden olduğu ana karotis arter yaralanması: Olgu sunumu ve literatürün sistematik biçimde gözden geçirilmesi

Dr. Fikri M Abu-Zidan,¹ Dr. Saleh Abdel-Kader,² Dr. Radwan El Hussein²

¹Birleşik Arap Emirlikleri Üniversitesi, Tıp ve Sağlık Bilimleri Fakültesi, Travma Grubu, Al-ain, BAE

²Al-ain Hastanesi, Cerrahi Bölümü, Vasküler Cerrahi Ünitesi, Al-ain, BAE

Yirmi beş yaşında bir erkek saldırgan bir deve tarafından boynundan ısırılmış ve boynunda üç küçük delici yara oluşmuştur. Sol karotis nabızı zayıf hissediliyordu. Anjiyografi sol ana karotis arterin distal segmentinde düzensiz kesiler olduğunu gösterdi. Boynun eksplorasyonu bu bulguları doğruladı. Otojen safen ven greft interpozisyonu başarıyla uygulandı. Hasta evine iyi durumda gönderildi. Bu konuya ilişkin literatürü sistematik biçimde gözden geçirdik ve yalnızca dört adet benzer olgu raporuna rastladık. Deve ısırığı yaraları küçük boyutlarda olmalarına rağmen derine penetre olabilecek ana damarlar dahil boyun oluşumlarında ciddi yaralanmalara neden olabilirler. Azgınlık dönemlerinde erkek develere yaklaşırken dikkatli olunmalıdır. Anahtar sözcükler: Boyun ısırığı; deve; karotis arter; travma; yaralanma.

Ulus Travma Acil Cerr Derg 2014;20(1):59-62 doi: 10.5505/tjtes.2014.69822