

# Comparison of cyanoacrylate-assisted arteriotomy closure with conventional closure technique

## Siyanoakrilat yardımcı arteriyotomi kapama tekniğinin konvansiyonel kapama tekniği ile karşılaştırılması

Ömer Faik ERSOY,<sup>1</sup> Hüseyin Ayhan KAYAOĞLU,<sup>1</sup> Alper ÇELİK,<sup>1</sup> Namık ÖZKAN,<sup>1</sup> Neşe LORTLAR,<sup>2</sup> Suna ÖMEROĞLU<sup>2</sup>

### BACKGROUND

We aimed to compare conventional suture closure of arteriotomy with N-butyl-cyanoacrylate-assisted suture closure.

### METHODS

Forty Wistar rats were randomly divided into two groups. Standard arteriotomy was performed to the abdominal aorta through a midline incision. In the first group, arteriotomy was closed by 3 stitches with 45° between each and in the second by two stitches with 0.1 ml (12-12.5 mg) cyanoacrylate. Amount of blood loss, operation time and severity of myointimal hyperplasia by immunohistochemistry on aorta segments were measured on postoperative days 7 and 30.

### RESULTS

Mean anastomotic time was 13.5±1.64 in the first and 13.0±1.75 min in the second group (p=0.356). Operation time was 23.45±3.63 in the control and 21.0±3.09 min in the second group (p=0.027). Mean amount of bleeding was 473.75±260.5 in the first and 327.5±155.36 µl in the second group (p=0.037). Intimal thickness on the 7th day was 80.62±7.92 in the first and 83.24±3.42 µm in the second group, and on the 30th day was 81.64±5.11 in the first and 88.77±11.03 µm in the second group. The early and late intimal thicknesses were similar (p=0.35 and 0.87, respectively).

### CONCLUSION

Reconstruction of arteriotomies with fewer sutures in combination with cyanoacrylate is a safe method associated with less blood loss and shorter operation time. It also does not lead to increased myointimal hyperplasia.

**Key Words:** Arteriotomy closure; N-butyl 2 cyanoacrylate; myointimal hyperplasia; operation time; vascular injury.

### AMAÇ

Arteriyotomi sonrası, konvansiyonel dikiş tekniği ile n-bütül-2-siyanoakrilat yardımcı kapama tekniği karşılaştırıldı.

### GEREÇ VE YÖNTEM

Kırk adet Wistar sıçan randomize olarak 2 gruba ayrıldı. Orta hat kesisiyle abdominal aortaya standart arteriyotomi uygulandı. Arteriyotomi, birinci grupta aralarında 45° açıyla 3 adet; ikinci grupta ise 60° açıyla 2 adet dikişle kapatıldı. İkinci gruba 0,1 ml (12-12,5 mg) siyanoakrilat uygulandı. Operasyon zamanı, kanama miktarı ve aortanın çıkarılan anastomotik segmentinde cerrahi sonrası 7. ve 30. günlerde immünohistokimyasal olarak miyointimal hiperplazinin şiddeti değerlendirildi.

### BULGULAR

Ortalama anastomoz zamanı 1. grupta 13,5±1,64 dk, 2. grupta 13,0±1,75 dk idi (p=0,356). Ameliyat süresi kontrol grubunda 23,45±3,63 dk, tedavi grubunda 21,0±3,09 dk olarak saptandı (p=0,027). Ortalama kanama miktarı 1. grupta 473,75±260,5 µl, 2. grupta 327,5±155,36 µl idi (p=0,037). Yedinci günde yapılan ölçümde intima kalınlığı 1. grupta 80,62±7,92 µm, 2. grupta 83,24±3,42 µm; 30. günde 1. grupta 81,64±5,11 µm, 2. grupta 88,77±11,03 µm olarak bulundu. Erken ve geç ölçümlerde intima kalınlıkları benzer düzeylerdeydi (sırasıyla p=0,35 ve p=0,87).

### SONUÇ

Arteriyotomilerin daha az dikişle, n-bütül-2-siyanoakrilat birleşimiyle rekonstrüksiyonu, daha az kanama ve daha kısa ameliyat süreleri ile seyreden güvenilir bir yöntemdir. Ayrıca, miyointimal hiperplazide artışa neden olmamıştır.

**Anahtar Sözcükler:** Arteriyotomi; n-bütül 2 siyanoakrilat; miyointimal hiperplazi; ameliyat süresi; kanama miktarı.

<sup>1</sup>Department of General Surgery, Gaziosmanpaşa University Faculty of Medicine, Tokat; <sup>2</sup>Department of Histology and Embryology, Gazi University Faculty of Medicine, Ankara, Turkey.

<sup>1</sup>Gaziosmanpaşa Üniversitesi Tıp Fakültesi, Genel Cerrahi Anabilim Dalı, Tokat; <sup>2</sup>Gazi Üniversitesi Tıp Fakültesi, Histoloji ve Embriyoloji Anabilim Dalı, Ankara.

Vascular injuries are life-threatening conditions caused mainly by penetrating injuries, traffic accidents and environmental causes.<sup>[1,2]</sup> Pure arterial injury is a rare cause of emergency applications, but may lead to functional deformities and even amputations.<sup>[3]</sup>

Injury to the composition of the vascular structures and manipulations in order to prevent bleeding lead to ischemia in the distal part of the affected area. Vascular damage leads to overexpression of tissue factor and activation of several adhesion molecules and cytokines, thus initiating a dense inflammatory reaction and increased adhesion formation that further exaggerates ischemia in the distal part.<sup>[4]</sup>

Despite the presence of reports favoring non-operative management of vascular injuries in selected cases,<sup>[5-7]</sup> especially in hemodynamically unstable patients, surgical exploration and repair is the traditional treatment for vascular injuries. However, different types of hemostatic agents like clamps, staples and biological adhesives have been used in vascular surgery in order to achieve appropriate hemostasis. A recent trend in surgical practice focuses on the utilization of biological materials such as fibrin collagen, thrombin, and synthetic agents (i.e. cyanoacrylate adhesives).

The clamping period during repair of an injured vessel is one of the most important issues, with ischemic effects observed at the end organ. With an increasing ischemia period, the severity of end organ injury is further aggravated by exaggerated ischemia-reperfusion injury.<sup>[8,9]</sup> Ischemia-reperfusion injury worsens the outcome with its local and systemic effects.<sup>[10,11]</sup> From this aspect, it is crucial to minimize the ischemic period in any type of vascular injury.

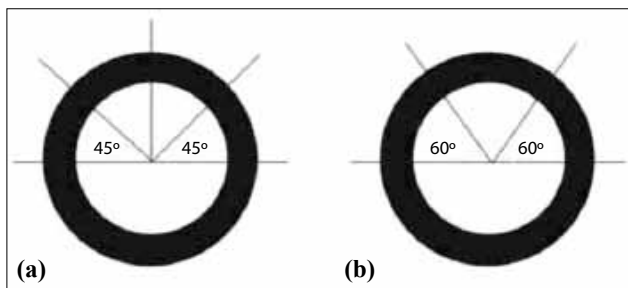
In light of these data, we hypothesized that local application of a suture line sealant may reinforce suture line tightness in arteriotomies. We further

thought that decrease in the number of sutures in vascular repair of arteriotomy might affect the operative period, amount of perioperative bleeding, and severity of myointimal hyperplasia (MIH). We tested our method by comparing a three-stitch closure with two-stitch closure and N-butyl cyanoacrylate (NBCA) in an animal model of aortic injury.

## MATERIALS AND METHODS

### Animals and Experimental Protocol

This study was approved by the local Ethical Committee. Forty Wistar-albino male rats weighing 300-350 g were randomly allocated into two groups (n=20 per group). All operative processes and follow-up were conducted at the local Animal Studies Research Center. Two to three rats were housed in separate wire cages with free access to food and water under standard laboratory conditions (room temperature 23°C, 12 h light-dark cycles). Rats were fasted 12 h before surgery, but had free access to water. Anesthesia was conducted by intraperitoneal injection of ketamine hydrochloride (Ketalar, Eczacibasi, Istanbul, Turkey) (75 mg/kg) and xylazine (Rompun, Bayer, Istanbul, Turkey) (10 mg/kg). The anterior abdominal skin was shaved, gently scrubbed with povidone iodine and a midline incision was performed, using No. 15 scalpel. The abdominal aorta was dissected from surrounding structures, and completely denuded from perivascular connective tissue. Proximal and distal ends of the abdominal aorta were clamped caudal to the renal arteries by microvascular clamps. Afterwards, arteriotomy was performed using a sterile no. 11 surgical blade, and an incision traversing the long axis and extending half the circumference of the abdominal aorta was done by a scissor. Arteriotomies were closed by 9/0 polypropylene (Prolene, Ethicon, Edinburgh, Scotland). In the first group, we placed three sutures, with an angle of approximately 45° between each, and in the second group by two sutures with an angle of approximately 60° between each, using a millimetric acetate diagram (Fig. 1). The second group received 0.1 ml (12-12.5 mg) NBCA (Glubran 2, General Enterprise Marketing, Viareggio, Italy) smeared on the arteriotomy site using a micropipette. After removal of the clamps, repair sites were observed for the presence of oozing. Abdominal wall layers were closed by continuous 2/0 polypropylene sutures, and fluid resuscitation was done by subcutaneous injection of 3 ml saline in the dorsum of each animal. In the second group, abdominal closure was performed after



**Fig. 1.** (a, b) Suture positions of the suture- and NBCA-treated groups, respectively.

NBCA entirely dried. All surgical procedures were performed by the same surgeon.

**Procedural Times**

In all animals, the time for anastomosis and total period of operation were evaluated separately. Anastomotic time was accepted as the period from the beginning of skin incision to the completion of anastomosis. Total time was accepted as the period from the beginning of skin incision to the completion of last skin suture. Both durations were measured in all models by chronometer.

**Amount of Bleeding**

Just after completion of anastomosis in both groups, the microvascular clamps were removed and all rats were observed for the amount of oozing. Blood loss was measured by capillary tubes each containing 50 µl capacity. Amount of bleeding was measured and recorded in all rats.

**Myointimal Hyperplasia**

Ten randomly selected rats from each group were sacrificed by high dose (200 mg/kg injection of thiopental sodium (Pental Sodyum, IE Ulugay Ilac San, Istanbul, Turkey) on postoperative days 7 and 30. The degree of MIH was assessed on postoperative day 7 (early) and 30 (late). The anastomotic segment of the aorta was resected under microscope for the evaluation of the severity of MIH, and assessment was performed by immunohistochemistry stains, as explained briefly hereunder:

Formalin-fixed paraffin-embedded sections were first deparaffinized, rehydrated and then boiled in high temperature microwave oven for retrieval stage. After 20 min at room temperature, tissues were circled with a pap-pen (hydrophobic pen) and washed

with distilled water and phosphate-buffered saline (PBS), and hydrogen peroxide was added drop-wise followed by application of ultra V block. After 1-h application of primary antibody (Elastin) diluted with antibody diluents, the samples were washed with PBS twice and the specimens were placed in 10 min AEC (3-amino-9-ethyl carbazole) chromogen. Finally, the counterstain with Mayer’s hematoxylin was performed for 5 min. All slides were evaluated with Leica DM 400 B light microscope (Leica, Wetzlar, Germany).

**Statistical Evaluation**

Statistical significance was assessed using independent samples t test and paired samples t test. P values below 0.05 were considered significant.

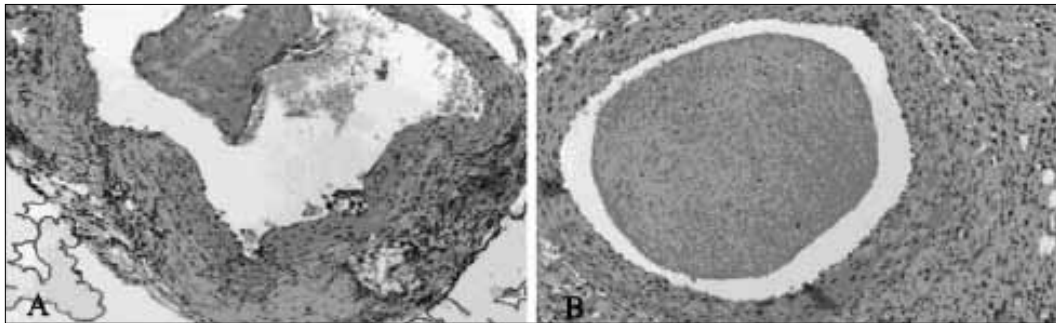
**RESULTS**

All rats completed the study. No anesthesia- or procedure-related morbidity like infection or thrombosis was observed. Mean time for anastomosis was 13.5±1.64 min in the first (control) group and 13±1.75 min in the second (treatment) group. Mean total operation time was 23.45±3.63 min in the control and 21.0±3.09 min in the treatment group. The difference in the anastomotic period between the two groups was not significant (p=0.356). However, in the treatment arm, a significant decrease in total operation time was detected (p=0.027).

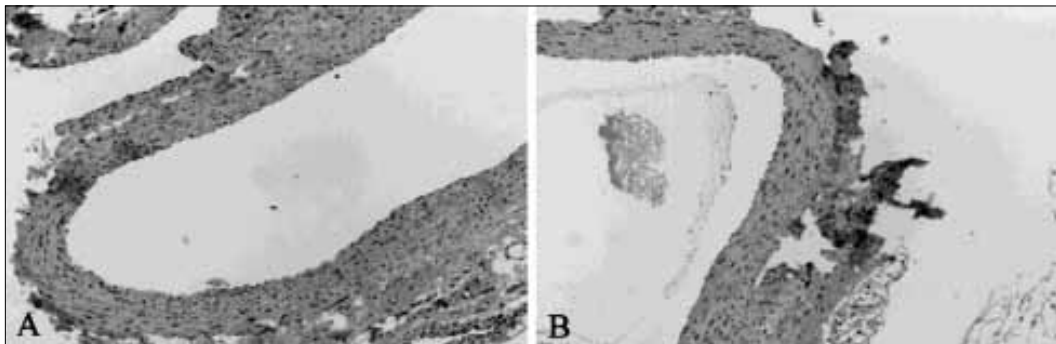
Mean amounts of bleeding in the first and NBCA groups were 473.75±260.5 and 327.5±155.36 µl, respectively. Blood loss was significantly lower in the NBCA arm (p=0.037). Mean period of anastomosis, mean operation time and mean amount of bleeding are depicted in Table 1.

**Table 1.** Mean ±SD of repair time, total operation time, amount of bleeding and thickness of intimal layer on postoperative 7th and 30th days in all rats

	Group	Mean ± SD	p
Anastomotic time (min)	Suture	13.5±1.64	0.356
	NBCA	13±1.75	
Total time (min)	Suture	23.45±3.63	0.027
	NBCA	21.0±3.09	
Amount of bleeding (µl)	Suture	473.75±260.5	0.037
	NBCA	327.5±155.36	
Thickness of intima (µm) (7th day)	Suture	80.62±7.92	0.35
	NBCA	83.24±3.42	
Thickness of intima (µm) (30th day)	Suture	81.64±5.11	0.87
	NBCA	88.77±11.03	



**Fig. 2.** (a, b) Cross-sectional view of an arteriotomy in the early phase (7th day) of suture- (a) and NBCA-treated (b) animals.



**Fig. 3.** (a, b) Cross-sectional view of an arteriotomy in the late phase (30th day) of suture- (a) and NBCA-treated (b) rats.

The degree of MIH was assessed on postoperative days 7 (early) and 30 (late). Mean intimal thicknesses during the early term were  $80.62 \pm 7.92$  and  $83.24 \pm 3.42$   $\mu\text{m}$  in the suture- and NBCA-treated groups, respectively (Figs. 2a, b). Late-term MIH scores were  $81.64 \pm 5.11$   $\mu\text{m}$  in the first group and  $88.77 \pm 11.03$   $\mu\text{m}$  in the NBCA arm (Figs. 3a, b). Both early and late MIH scores (Table 1) were similar between groups ( $p=0.35$  and  $0.87$ , respectively). Time course assessment of MIH within the study groups revealed a slight increase in both groups. For suture-treated rats, the mean difference from the 7th to 30th days was  $+1.02 \pm 9.85$   $\mu\text{m}$ , while in the NBCA-treated group, this value was  $+5.53 \pm 11.62$   $\mu\text{m}$ , both of which were insignificant ( $p=0.936$ ,  $p=0.362$ , respectively).

## DISCUSSION

In the present study, we compared conventional suture technique with a repair model of fewer sutures combined with NBCA application in an arteriotomy model. We observed similar repair times between the two groups. We believe this might be due to the small diameter of the rat aorta and the few numbers of sutures. We applied only one additional stitch to suture-treated rats. In the NBCA group, instead of a third stitch, we applied NBCA and observed the repair site until the application dried. In the NBCA

group, only minimal oozing was observed. However, in the suture-treated rats, even after accomplishment of arteriotomy closure, we observed oozing in almost all rats. This was also confirmed by higher amounts of bleeding in the suture-treated rats. Therefore, we believe that the shorter operation time in the NBCA arm can be attributed to shorter time needed for hemostasis. The benefits of reducing the number of sutures can lower the operation time and associated ischemic period, thereby decreasing both ischemic and reperfusion injury. In addition, the rates of anastomotic narrowing and foreign body reaction, which are major problems in vascular surgery, could be decreased by suture reduction.<sup>[12]</sup>

Derivatives of cyanoacrylates offer a number of advantages like easy application, rapid tissue interaction, external usage, and avoidance of the need for later removal.<sup>[13]</sup> These derivatives also have the essential properties of biomaterials including biocompatibility, gradual breakdown and absence of foreign body reaction. They have been used especially in the treatment of skin wounds and a variety of medical conditions including variceal bleeding, embolization, and treatment of fistulas.<sup>[14-18]</sup> In this study, we investigated whether a standard arteriotomy might be safely closed with fewer sutures with the assistance of NBCA.

In a study about sutureless arterial anastomosis using cyanoacrylate, it was shown that sutureless anastomosis was associated with similar leak rates, but less bleeding, less operation time and less MIH. The authors concluded, in parallel to our data, that sutureless anastomoses are associated with shorter completion time, less bleeding, less MIH, and equivalent patency.<sup>[19]</sup> In the present study, we applied NBCA to the outer surface of the vessels. One of the reasons for the external application is the high risk of distal emboli seen in NBCA treatment. Also, even if NBCA polymerizes very rapidly, it can be washed away before it polymerizes completely.<sup>[20]</sup> Other possible disadvantages of NBCA as a suture line sealant are its high cost and occasional foreign body or local inflammatory reaction.

Besides its rapid polymerization rate, cyanoacrylate, as a sealant, can be applied to numerous biomembranes,<sup>[21]</sup> and it does not carry the risk of viral transmission like fibrin glue, which is prepared from plasma pooled from human donors.<sup>[22]</sup> However, to date, only a few reports of viral transmission exist in the literature.<sup>[23]</sup> Biodegradability and lack of a reciprocal influence on coagulation are other points of concern while using tissue adhesives. Previous reports of cyanoacrylate were based on preparations that degraded into formaldehyde. This product is cytotoxic and is responsible for the high rates of tissue reaction in earlier reports based on this biomaterial.<sup>[24]</sup> However, recent synthetic cyanoacrylates are not associated with toxic end products. Fibrin or gelatin glues function by activating the physiologic clotting cascade leading to the formation of a stable fibrin matrix. Therefore, they are completely biodegradable.<sup>[25]</sup> However, gelatin glues in particular are associated with cytotoxicity due to the release of formaldehyde during degradation, and they function improperly in active bleeding. Therefore, current policy advocates their usage for the control of bleeding or if the tear is just oozing.<sup>[26]</sup>

Thrombus formation at the anastomotic site is a debilitating problem, and frequently requires intensive work-up for resolution. Sutured anastomoses, when compared with biodegradable devices, are more commonly associated with thrombus formation.<sup>[27]</sup> Sutureless vascular anastomoses, including cyanoacrylates, even in the presence of vascular prosthesis, are associated with less thrombus formation and MIH.<sup>[28-31]</sup> Cyanoacrylates can eventually be used in major lacerations<sup>[32]</sup> with no toxicity to the vessel wall and less foreign body reaction, with

equal tensile strength and stiffness when compared with conventional sutured anastomosis.<sup>[31]</sup>

Myointimal hyperplasia occurs as a result of alterations in the hemodynamic status of the endothelium, and has been shown to be an important adaptive mechanism of arterial healing against injuries. It has paramount importance in the remodelling of vascular structures and is also responsible for 30% of early stenosis in grafts per year.<sup>[33-35]</sup> For these reasons, it is an important concern in the treatment of vascular disorders. Previous reports indicate that maximal intimal thickening is detectable one month after injury.<sup>[36]</sup> We thus assessed MIH levels on the 30th day. Our results have shown that external application of NBCA provided adequate control on arteriotomy repair and did not alter the MIH rates in either the early- or the late-term evaluation. The data presented here parallels the literature data indicating similar rates of MIH in cyanoacrylate treatment compared with sutured repair or oxidized cellulose.<sup>[37,38]</sup> Cellulose is currently being used for hemostasis in surgical practice. However, cyanoacrylates have been proven to be more effective than cellulose<sup>[38]</sup> and sutured repair<sup>[19]</sup> in bleeding control. We also detected lower amounts of bleeding in the NBCA-treated rats.

Considering the risk of acute narrowing, restenosis and even obstruction after each attempt to repair anastomotic leakage by extra stitches, we believe that NBCA application, by avoiding the need for more stitches, would be beneficial.

Our study suggests that appropriate hemostasis in arteriotomy can be achieved with the application of NBCA. This technique is associated with shorter operation time, less bleeding, and unaltered rates of MIH, compared to suture repair. It is concluded that this technique should be the preferred choice in patients in poor medical condition, in whom operation time is crucial, and in cases where appropriate hemostasis can not be achieved due to technical difficulty or localization, with no side effect on intimal hyperplasia.

## REFERENCES

1. Bedirli A, Sözüer EM, Şakrak Ö, Yılmaz Z, Kerek M. Abdominal büyük damar yaralanmaları. *Turkish Journal of Trauma & Emergency Surgery* 1999;5:116-9.
2. Cihan HB, Gülcan O, Hazar A, Türköz R. Peripheral vascular injuries. *Ulus Travma Derg* 2001;7:113-6.
3. Szumilak A, Frańczuk B, Kasperek M, Bernacki K. Arterial injuries in the Emergency Room Practice of Traumatic Surgery. *Ortop Traumatol Rehabil* 2001;3:272-5.
4. Hunting CB, Noort WA, Zwaginga JJ. Circulating endothelial

- (progenitor) cells reflect the state of the endothelium: vascular injury, repair and neovascularization. *Vox Sang* 2005;88:1-9.
5. Ngakane H, Muckart DJ, Luvuno FM. Penetrating visceral injuries of the neck: results of a conservative management policy. *Br J Surg* 1990;77:908-10.
  6. Pruvot FR, Meaux F, Truant S, Plénier I, Saudemont A, Gambiez L, et al. Severe blunt liver injury: reappraisal of criteria for nonoperative management decision. Experience with 88 cases. *Ann Chir* 2005;130:70-80.
  7. Yang J, Gao JM, Jean-Claude B. Non-operative management of adult blunt splenic injuries. *Chin J Traumatol* 2006;9:246-8.
  8. Myers SI, Wang L, Myers DJ. Loss of renal function and microvascular blood flow after suprarenal aortic clamping and reperfusion (SPACR) above the superior mesenteric artery is greatly augmented compared with SPACR above the renal arteries. *J Vasc Surg* 2007;45:357-66.
  9. Laca L, Olejnik J, Vician M, Grandtnerova B, Zahradnik V. The effects of occlusive techniques on the short-term prognosis after liver resections. *Hepatogastroenterology* 2006;53:576-9.
  10. Wang WZ, Fang XH, Stephenson LL, Khiabani KT, Zamboni WA. Melatonin reduces ischemia/reperfusion-induced superoxide generation in arterial wall and cell death in skeletal muscle. *J Pineal Res* 2006;41:255-60.
  11. Chiappa AC, Makuuchi M, Zbar AP, Biella F, Vezzoni A, Torzilli G, et al. Protective effect of methylprednisolone and of intermittent hepatic pedicle clamping during liver vascular inflow occlusion in the rat. *Hepatogastroenterology* 2004;51:1439-44.
  12. Ong YS, Yap K, Ang ES, Tan KC, Ng RT, Song IC. 2-Octylcyanoacrylate-assisted microvascular anastomosis in a rat model: long-term biomechanical properties and histological changes. *Microsurgery* 2004;24:304-8.
  13. Singer AJ, Quinn JV, Hollander JE. The cyanoacrylate topical skin adhesives. *Am J Emerg Med* 2008;26:490-6.
  14. Quinn J, Wells G, Sutcliffe T, Jarmuske M, Maw J, Stiell I, et al. A randomized trial comparing octylcyanoacrylate tissue adhesive and sutures in the management of lacerations. *JAMA* 1997;277:1527-30.
  15. Noophun P, Kongkam P, Gonlachanvit S, Rerknimitr R. Bleeding gastric varices: results of endoscopic injection with cyanoacrylate at King Chulalongkorn Memorial Hospital. *World J Gastroenterol* 2005;11:7531-5.
  16. Denys A, Lacombe C, Schneider F, Madoff DC, Doenz F, Qanadli SD, et al. Portal vein embolization with N-butyl cyanoacrylate before partial hepatectomy in patients with hepatocellular carcinoma and underlying cirrhosis or advanced fibrosis. *J Vasc Interv Radiol* 2005;16:1667-74.
  17. Aslan G, Men S, Gülcü A, Kefi A, Esen A. Percutaneous embolization of persistent urinary fistula after partial nephrectomy using N-butyl-2-cyanoacrylate. *Int J Urol* 2005;12:838-41.
  18. Kuran S, Disibeyaz S, Parlak E, Arhan M, Kacar S, Sahin B. Biliocutaneous fistula following alveolar hydatid disease surgery treated successfully with percutaneous cyanoacrylate. *Dig Dis Sci* 2006;51:18-20.
  19. Qu L, Jing Z, Wang Y. Sutureless anastomoses of small and medium sized vessels by medical adhesive. *Eur J Vasc Endovasc Surg* 2004;28:526-33.
  20. Aytakin C, Boyvat F, Gebedek O, Coskun M. Balloon-assisted ultrasound-guided direct percutaneous embolization of a peripheral pseudoaneurysm with n-butyl cyanoacrylate. *Eur Radiol* 2002;12 Suppl 3:S185-8.
  21. Stooker W, Niessen HW, Wildevuur WR, van Hinsbergh VW, Fritz J, Jansen EK, et al. Perivenous application of fibrin glue reduces early injury to the human saphenous vein graft wall in an ex vivo model. *Eur J Cardiothorac Surg* 2002;21:212-7.
  22. Kim T, Kharod BV. Tissue adhesives in corneal cataract incisions. *Curr Opin Ophthalmol* 2007;18:39-43.
  23. Hino M, Ishiko O, Honda KI, Yamane T, Ohta K, Takubo T, et al. Transmission of symptomatic parvovirus B19 infection by fibrin sealant used during surgery. *Br J Haematol* 2000;108:194-5.
  24. Coover HN, Joyner FB, Sheer HN. Chemistry and performance of cyanoacrylate adhesive. *J Soc Plast Surg Eng* 1959;15:5.
  25. Byrne DJ, Hardy J, Wood RA, McIntosh R, Cuschieri A. Effect of fibrin glues on the mechanical properties of healing wounds. *Br J Surg* 1991;78:841-3.
  26. Bingley JA, Gardner MA, Stafford EG, Mau TK, Pohlner PG, Tam RK, et al. Late complications of tissue glues in aortic surgery. *Ann Thorac Surg* 2000;69:1764-8.
  27. Ichikawa M, Muneshige H, Ikuta Y. Comparison of tensile strength and thrombus formation between mechanical microvascular anastomoses using a biodegradable ring device and sutured anastomoses. *J Reconstr Microsurg* 2002;18:131-9.
  28. Sakai O, Nakayama Y, Nemoto Y, Okamoto Y, Watanabe T, Kanda K, et al. Development of sutureless vascular connecting system for easy implantation of small-caliber artificial grafts. *J Artif Organs* 2005;8:119-24.
  29. Baguneid MS, Goldner S, Fulford PE, Hamilton G, Walker MG, Seifalian AM. A comparison of para-anastomotic compliance profiles after vascular anastomosis: nonpenetrating clips versus standard sutures. *J Vasc Surg* 2001;33:812-20.
  30. Hawthorne WJ, Ao PY, Fletcher JP. Vascular closure staples reduce intimal hyperplasia in prosthesis implantation. *ANZ J Surg* 2002;72:862-6.
  31. Ong YS, Yap K, Ang ES, Tan KC, Ng RT, Song IC. 2-Octylcyanoacrylate-assisted microvascular anastomosis in a rat model: long-term biomechanical properties and histological changes. *Microsurgery* 2004;24:304-8.
  32. Lachapelle K, deVarennes B, Ergina PL, Cecere R. Sutureless patch technique for postinfarction left ventricular rupture. *Ann Thorac Surg* 2002;74:96-101.
  33. Stansby G, Chan YC, Berwanger CS, Shurey S, Rook GA, Stanford JL. Prevention of experimental myointimal hyperplasia by immunomodulation. *Eur J Vasc Endovasc Surg* 2002;23:23-8.
  34. Hobson RW 2nd, Goldstein JE, Jamil Z, Lee BC, Padberg FT Jr, Hanna AK, et al. Carotid restenosis: operative and endovascular management. *J Vasc Surg* 1999;29:228-38.
  35. Neville RF, Sidawy AN. Myointimal hyperplasia: basic science and clinical considerations. *Semin Vasc Surg* 1998;11:142-8.
  36. Kayaoglu HA, Ersoy OF. Etiopathogenesis of myointimal hyperplasia and therapy alternatives. *Turkish J Vasc Surg* 2005;14:1-7.
  37. Kaplan M, Bozkurt S, Kut MS, Kullu S, Demirtas MM. Histopathological effects of ethyl 2-cyanoacrylate tissue adhesive following surgical application: an experimental study. *Eur J Cardiothorac Surg* 2004;25:167-72.
  38. Ellman PI, Brett Reece T, Maxey TS, Tache-Leon C, Taylor JL, Spinosa DJ, et al. Evaluation of an absorbable cyanoacrylate adhesive as a suture line sealant. *J Surg Res* 2005;125:161-7.