



Diagnostic process and management of diaphragmatic injuries: approach in patients with blunt and penetrating trauma

Diyafam yaralanmalarında tanı süreci ve yönetim:
Künt ve penetran travmalı hastalara yaklaşım

Atilla ÇELİK,¹ Ediz ALTINLI,¹ Neşet KÖKSAL,¹ Kasım ÇAĞLAYAN,²
Mehmet Ali UZUN,¹ Doğan ERDOĞAN,¹ Ömer Faruk ÖZKAN¹

BACKGROUND

Diaphragmatic rupture is one of the most commonly missed injuries in trauma cases. Traditionally, laparotomy or thoracotomy has been the treatment of choice for this condition. We aimed to evaluate the diagnostic process in patients with diaphragmatic injuries (DIs) who were diagnosed with diaphragm rupture during the preoperative or intraoperative course together with morbidity and mortality rates.

METHODS

Sixteen patients with DIs were admitted to our department during the last seven-year period. Surgical procedure, accompanying injuries, duration of hospital stay, transfusion necessity, and morbidity and mortality rates were analyzed retrospectively.

RESULTS

In seven years, 16 patients were treated and followed-up for DI. Female/male ratio was 2/14. Fifteen patients were operated and one was treated conservatively. The mortality rate was 2/16.

CONCLUSION

DIs are being seen with increasing frequency in recent years. In patients with high Injury Severity Score (ISS), probability of DI should be taken into consideration.

Key Words: Algorithm; diaphragm injury; Injury Severity Score; management.

AMAÇ

Travmalı hastalarda en sık gözden kaçan yaralanmalardan birisi diyafram yırtığıdır. Tespit edilmesi halinde tedavi için laparotomi veya torakotomi gerekmektedir. Bu çalışmanın amacı, ameliyat öncesinde ve ameliyat esnasında tespit edilen diyafram yaralanmalı, hastaların tanılma süreçlerini, mortalite ve morbidite oranları eşliğinde değerlendirmektir.

GEREÇ VE YÖNTEM

Kliniğimize yedi yıllık süre içinde kabul edilen 16 diyafram yaralanmalı hastada cerrahi girişim, eşlik eden yaralanmalar, hastanede kalış süresi, transfüzyon gereksinimi, mortalite ve morbidite oranları retrospektif olarak incelendi.

BULGULAR

Yedi yılda 16 hasta diyafram yaralanması nedeniyle tedavi edildi. Kadın/erkek oranı 2/14 idi. Hastaların 15'i ameliyat edilirken bir hasta konservatif tedavi edildi.

SONUÇ

Diyafam yaralanmaları son yıllarda giderek artmaktadır. Yaralanma şiddeti skoru yüksek hastalarda diyafram yaralanması olasılığı mutlaka düşünülmelidir.

Anahtar Sözcükler: Algoritm; diyafram yaralanması; yaralanma şiddet skoru; yönetim.

¹2nd Department of General Surgery, Haydarpaşa Numune Training and Research Hospital, Istanbul; ²Department of General Surgery, Kars State Hospital, Kars, Turkey.

¹Haydarpaşa Numune Eğitim ve Araştırma Hastanesi, 2. Genel Cerrahi Kliniği, İstanbul; ²Kars Devlet Hastanesi, Genel Cerrahi Kliniği, Kars.

The diaphragm is a dome-shaped musculofibrous septum, which separates the thorax from the abdominal cavity.^[1,2] The first description of a traumatic diaphragmatic rupture was made by Sennertus in 1541, and the first successful surgical repair was performed by Riolfi in 1886.^[3,4] Diaphragmatic injuries (DIs) are usually caused by blunt trauma or penetrating injuries.^[5] DI occurs in 0.8-5% of hospitalized automobile victims, in approximately 5% of blunt trauma patients who undergo laparotomy, and in 10-15% of patients with penetrating trauma.^[6,7] Diaphragmatic rupture as a result of abdominal trauma is one of the most commonly missed injuries.^[8] The diagnosis may be delayed due to confusing clinical and radiographic findings. Delayed or missed diagnosis at the time of the initial injury and the life-threatening catastrophic sequelae if left untreated for an extended period compound the problem.^[9,10] Acute DI is associated with widely ranging mortality of 5.5-51%, with death typically resulting from associated injuries or in-hospital complications, such as adult respiratory distress syndrome.^[11] Complications usually relate to visceral herniation through the diaphragmatic defect, and include respiratory compromise that is due to impaired pulmonary inflation and visceral incarceration with or without strangulation or perforation.^[12]

The aim of this retrospective study was to review the experience of our department with the management of DI in order to identify incidence, associated morbidity and mortality, predictors of outcome, and factors contributing to diagnostic delay.

MATERIALS AND METHODS

Haydarpaşa Numune Training and Research Hospital is an affiliated hospital of the Ministry of Health and one of the largest multidisciplinary training hospitals in Turkey. It has a trauma center, and is considered to be the one of the busiest hospitals in Istanbul as well. Our hospital has approximately 40,000 admissions per year, and traumatized patients and blunt and penetrating trauma to the body account for approximately 10,000 admissions among those.

A total of 16 patients with a diagnosis of DI admitted to the 2nd Department of General Surgery of Haydarpaşa Numune Training Hospital between January 2001 and June 2008. We investigated the medical records and radiological examinations of the patients who were diagnosed as DI in our department.

The variables studied in relation to the outcome were incidence, age, sex, causes of injury, side of rupture, type of injury, hemodynamic status upon admission, imaging studies performed, method of diagnosis, time to diagnosis, concomitant injuries, Injury Severity Score (ISS), performed and additional surgical intervention, herniated organs, morbidity, mortality,

duration of hospital stay, and reasons for diagnostic delay.

Unpaired Student's t-test was used for continuous variables and the χ^2 test for differences between categorical variables. A p-value of <0.05 was considered statistically significant.

RESULTS

Patient Demographics

In the seven-year period, there were 14 (87%) male and 2 (13%) female patients, aged 14-52 (mean: 28) years. The causes of injury were: motor vehicle crash (n: 1, 6.2%), penetrating injury (n: 12, 75%), fall from height (n: 1, 6.2%), and gunshot injury (n: 2, 12.5%). The anatomic distributions of DIs consisted of 3 right-sided injuries (19%) and 13 left-sided injuries (81%). One of the two patients with blunt injury had right and the other had left DI. The clinical features of the 16 patients are listed in Table 1.

Diagnostic Course

Five of 16 patients were hemodynamically unstable upon admission (patients had systolic blood pressure of <80 mmHg or pulse >120 per minute and/or shock table clinically). All of the unstable patients were admitted to the emergency operating room after fast resuscitation that included proper fluid, electrolyte and blood transfusion. Stable patients were evaluated fully, according to the appropriate advanced life support modalities. After the radiological evaluation, required surgical interventions were performed. There were 5 unstable patients (3 stab wounds, 2 gunshot injuries).

Diagnostic modalities included plain chest X-rays (all patients), abdominal ultrasonography (4 patients), computerized tomography (CT) (4 patients), diagnostic peritoneal lavage (1 patient), and diagnostic laparoscopy (1 patient).

Abdominal ultrasonography and CT of the thorax and abdomen were performed for hemodynamically stable patients.

Among the 16 operated patients, the reasons for surgery were as follows:

- 3 patients due to DI detected on CT scans
- 5 patients due to suspicion on X-ray films and physical examination
- 5 patients because of hemodynamic instability
- 3 patients for their progression into acute abdominal findings

The earliest operation was performed at the 10th minute of the hospital admission while the latest was on the 11th day.

Table 1. Demographic and clinical characteristics of the patients

No	Sex	Age	TI	H	D	ISS	AOI	TO	A	OT	Side	HS	SY
1	M	52	B	S	CT	41	+	48 hrs	Lp	P, SP	L	20	Mrt
2	F	25	P	S	AA	12	+	15 min	Lp	P, J, C, H	L	9	Dis
3	M	19	P	S	AA	33	+	30 min	Lp	P, S	L	5	Dis
4	M	17	P	S	CxR, PE	12	-	72 hrs	La	P	L	7	Dis
5	M	40	P	S	CxR, PE	33	+	90 min	Lp	P, S	L	7	Dis
6	M	25	B	S	CT	50	+	6 hrs	Lp	P, J, RN, VCI, H	R	22	Dis
7	M	17	P	S	AA	12	+	25 min	Lp	P, G	L	9	Dis
8	M	47	P	S	CxR, PE	8	-	55 min	Lp	P	R	4	Dis
9	M	48	P	S	CT	8	-	-	-	-	R	4	Dis
10	M	30	P	S	CxR, PE	13	+	264 hrs	T	P, O	L	18	Dis
11	F	18	P	US	HiS	38	+	10 min	Lp	P, G, S, LR	L	5	Dis
12	M	24	P	US	HiS	45	+	29 hrs	Lp	P, G, PR	L	6	Dis
13	M	27	P	S	CxR, PE	8	-	30 min	Lp	P	L	3	Dis
14	M	20	P	US	HiS	21	+	30 min	Lp	P, C	L	5	Dis
15	M	14	P	US	HiS	75	+	10 min	T	-	L	0	Mrt
16	M	30	P	US	HiS	41	+	10 min	LT	P, G, LR	L	7	Dis

M: Male; F: Female; TI: Type of injury; B: Blunt; P: Penetrating; H: Hemodynamic status; S: Stable; US: Unstable; D: Diagnosis; CT: Computerized tomography; AA: Acute abdomen; CxR-PE: Chest X-ray-physical examination; HiS: Hemodynamic instability; ISS: Injury Severity Score; AOI: Additional organ injury; TO: Timing of operation; A: Application; Lp: Laparotomy; La: Laparoscopy; T: Thoracotomy; LT: Laparothoracotomy; OT: Operation type; P: Primary; SP: Splenectomy; J: Jejunorrhaphy; C: Colorrhaphy; H: Hepatorrhaphy; S: Splenorrhaphy; RN: Renorrhaphy; VCI: Vena cava inferior repair; G: Gastrorrhaphy; O: Omentorrhaphy; LR: Lung repair; PR: Pancreaticorrhaphy; L: Left; R: Right; HS: Hospital stay (day); SY: Survey; Mrt: Mortality; Dis: Discharged.

Associated Injuries

Associated organ injuries were present in 12 patients (75%) and included spleen (n: 4, 33%), bowel (n: 2, 16%), stomach (n: 3, 25%), liver (n: 2, 16%), kidney (n: 1, 8%), pancreas (n: 1, 8%), heart (n: 1, 8%), lung (n: 2, 16%), major vessel (n: 1, 8%), omentum (n: 1, 8%), and head injury (n: 1, 8%). Four patients had isolated DI. All of the patients with isolated diaphragmatic rupture had penetrating injuries.

The majority of patients had multiple trauma and significant associated injuries, which are shown in Table 2.

Surgery

The diaphragm was repaired via laparotomy in 11 patients (73%), thoracotomy in 2 patients (13%), laparoscopy in 1 patient (6.6%), and both laparotomy and thoracotomy in 1 patient (6.6%). Both interrupted and running techniques with non-absorbable suture were used.

Among the 16 patients with DI, one had right-sided injury. As he was hemodynamically stable, he was conservatively treated without surgical intervention.

Outcome

Beginning from the admission to the hospital, the earliest operation was performed at the 10th minute, and the latest operation was performed on the 11th day. Among 13 patients operated and discharged, the mean hospital stay was 8.2 (3-22) days. One patient medically treated was discharged on the 4th day. Two patients (12.5%) died due to the injury (2/16). One of

the patients who died had admitted to hospital with penetrating cardiac injury because of gunshot and was hemodynamically unstable. He was operated 10 minutes after admitting to our hospital. Thoracotomy was performed, but the patient died on the operating table due to non-reversible hypovolemic shock. Totally, 2 units of erythrocyte suspension were administered during the operation intravenously, and the ISS score was 75. The other mortality had admitted to the hospital due to a fall from height. In the first physical examination, the patient was evaluated as stable. In addition to the DI, the patient had splenic laceration and cranial injury. Splenectomy and phrenography were performed. This patient was treated in the intensive care unit for 20 days due to diffuse subarachnoid bleeding and died with an ISS score of 41.

Table 2. Additional organ injuries observed in 12 patients

Concomitant injury	No. of patients
Lung laceration	2
Pericardial laceration	1
Major vessel injury	1
Spleen laceration	4
Liver laceration	2
Bowel laceration	2
Kidney rupture	1
Stomach rupture	3
Head injury	1
Omentum injury	1
Pancreas laceration	1

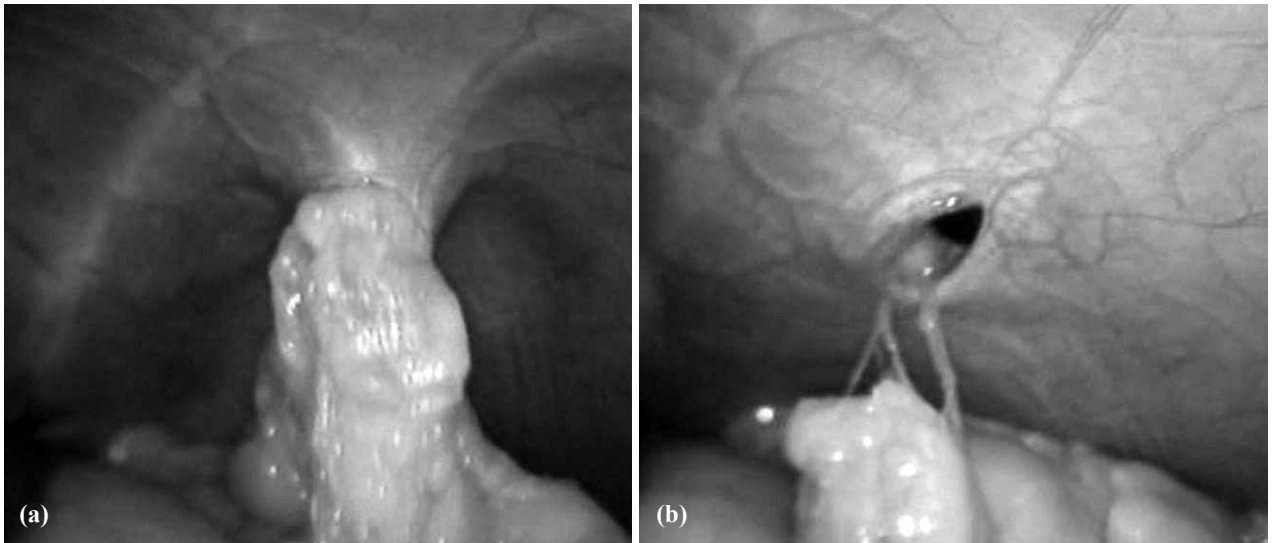


Fig. 1. Typical operative findings of diaphragmatic injury in a patient with thoraco-abdominal stab wound. **(a)** A part of the omentum was herniated into the thoracic cavity. **(b)** Diaphragmatic defect was seen after reduction of incarcerated material.

The mean ISS score of the patients who did not survive was 58, while this was 23.8 in surviving patients, and the difference was statistically significant ($p < 0.005$).

The mean ISS score in the patients with additional organ injury was 34.5, while it was 9 in DI only patients, and the difference was statistically significant ($p < 0.005$). We found that additional organ injury prolonged the hospital stay.

The postoperative complications were empyema,^[1] intraabdominal abscess,^[2] pneumonia,^[3] urinary tract infection,^[3] and wound infection.^[4]

DISCUSSION

Diaphragmatic injury is not a condition commonly faced by emergency care physicians, which may partially explain why the diagnosis and onset of the treatment are not always so easy. Furthermore, in the literature, the clinical series do not include sufficient cases. Our study included 16 patients, 15 of whom were operated. One patient with right-sided DI was treated medically and released on the 4th day of the hospital stay.

The true incidence of DI is unknown because in 7-66% of major trauma victims, the diagnosis is missed. This is particularly true for right-sided DI.^[9] Left-sided DIs are considerably more common than right-sided injuries.^[13,14] In our study, the left-sided injury rates were higher than stated in the literature (3/16). It may be due to high penetrating injury rates.

Diagnostic methods that have been reported to be useful in the evaluation of DI include plain chest X-ray, upper gastrointestinal contrast study, diagnostic peritoneal lavage, ultrasound, CT, magnetic resonance

imaging, laparoscopy, and thoracoscopy. However, there are no studies comparing the sensitivity, specificity and diagnostic accuracy of these modalities in the evaluation of DI.^[9] In our study, different diagnostic methods were used; however, none of them was shown to be superior to another. The most common method was chest X-ray, followed by CT. In our series, CT detected the injury in only 3 of 16 patients. The typical operative findings of left DI are shown in Fig. 1a and b in patients with penetrating injury.

Recent series from western countries state the ratio of penetrating to blunt injury as 2:1.^[15] In our study, this ratio was much higher, in 14 of 16 patients. This varying ratio may be attributed to the location of the hospital.

Early morbidity and mortality from blunt diaphragmatic rupture are due to the associated injuries. Desforges et al.^[15] postulated that diaphragmatic rupture results from the transmission of a force applied to the abdomen or flank through the abdominal viscera to the diaphragm and that the liver buffers the right diaphragm. This hypothesis was supported by Bekassy et al.^[15] In our series, two patients admitted with blunt trauma, one with right- and the other with left-sided injury; however, more cases are needed for a precise comparison. One of these two patients died due to cranial trauma, and the other patient was treated and discharged.

Particularly among the patients with thoracoabdominal penetrating trauma, in those operated for intraabdominal injury, the diagnosis of DI was easier; however, the diagnosis can still be missed in these cases. Arak et al.^[15] missed the diagnosis in five cases, but this was not a factor in the present study.

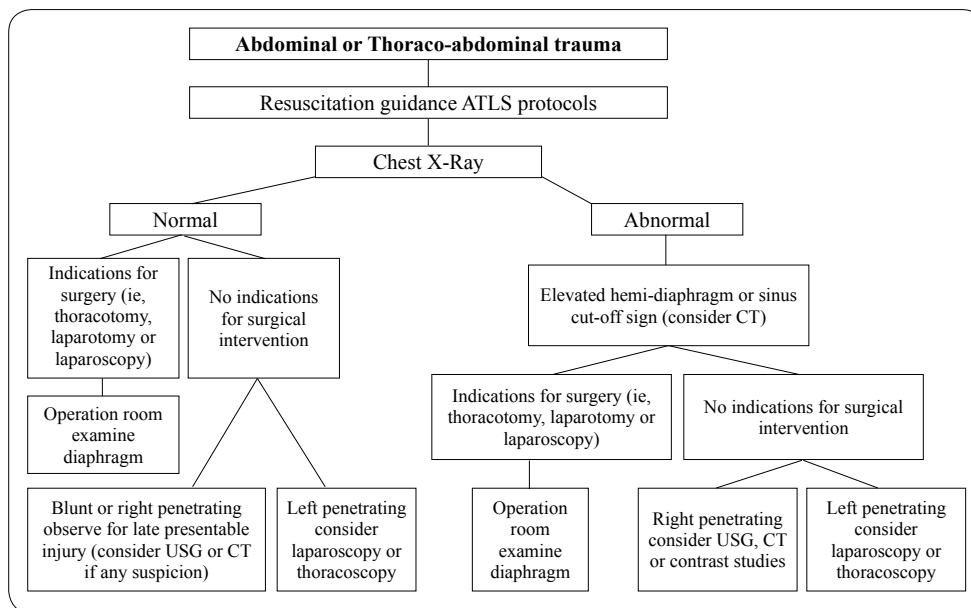


Fig. 2. A simple and suitable algorithm to avoid misdiagnosis in patients with high ISS score.

In penetrating traumas, there is no predisposing area of injury and the defect of the diaphragm is usually smaller than in defects caused by blunt traumas; therefore, they are potentially more dangerous in terms of later obstruction and strangulation.^[16] Eighty-four percent of DIs due to penetrating injury have a defect of less than 2 cm, but the defects due to blunt trauma are larger, with the majority being over 10 cm.^[17] In our study, in one of the blunt trauma patients, the injury was as long as 10 cm, and in the other patient, the diaphragm was injured on three different sides. In two of the penetrating injury patients, the lesions were 4 cm, while in the other 11 patients, the lesions were smaller than 2 cm. In the patients treated medically, the lesions detected on CT measured 2 cm.

In conclusion, we think that suspicion is the leading step in diagnosing DI; otherwise, it can be missed easily. We suggest that blunt trauma and high ISS score are the alarming factors. In misdiagnosed cases, especially left-sided, the patients have the risk of developing diaphragmatic hernias and pulmonary complications. To avoid morbidity and mortality, the operation should be performed as soon as the diagnosis is established. We suggest a simple algorithmic guide in patients having high ISS score, as seen in Fig. 2, in order to prevent a missed diagnosis of DI.

REFERENCES

1. Sangster G, Ventura VP, Carbo A, Gates T, Garayburu J, D'Agostino H. Diaphragmatic rupture: a frequently missed injury in blunt thoracoabdominal trauma patients. *Emerg Radiol* 2007;13:225-30.
2. Eren S, Ciriş F. Diaphragmatic hernia: diagnostic approaches with review of the literature. *Eur J Radiol* 2005;54:448-59.
3. Gavelli G, Canini R, Bertaccini P, Battista G, Bnà C, Fattori R. Traumatic injuries: imaging of thoracic injuries. *Eur Radiol* 2002;12:1273-94.

4. Mihos P, Potaris K, Gakidis J, Paraskevopoulos J, Varvatsoulis P, Gougoutas B, et al. Traumatic rupture of the diaphragm: experience with 65 patients. *Injury*. 2003;34:169-72.
5. Shackleton KL, Stewart ET, Taylor AJ. Traumatic diaphragmatic injuries: spectrum of radiographic findings. *Radiographics* 1998;18:49-59.
6. Esme H, Solak O, Sahin DA, Sezer M. Blunt and penetrating traumatic ruptures of the diaphragm. *Thorac Cardiovasc Surg* 2006;54:324-7.
7. Athanassiadi K, Kalavrouziotis G, Athanassiou M, Vernikos P, Skrekas G, Poultisidi A, et al. Blunt diaphragmatic rupture. *Eur J Cardiothorac Surg* 1999;15:469-74.
8. Matz A, Landau O, Alis M, Charuzi I, Kyzer S. The role of laparoscopy in the diagnosis and treatment of missed diaphragmatic rupture. *Surg Endosc* 2000;14:537-9.
9. Shah R, Sabanathan S, Mearns AJ, Choudhury AK. Traumatic rupture of diaphragm. *Ann Thorac Surg* 1995;60:1444-9.
10. Hacıbrahimoglu G, Solak O, Olcmen A, Bedirhan MA, Solmaz N, Gurses A. Management of traumatic diaphragmatic rupture. *Surg Today* 2004;34:111-4.
11. Sliker CW. Imaging of diaphragm injuries. *Radiol Clin North Am* 2006;44:199-211.
12. Patselas TN, Gallagher EG. The diagnostic dilemma of diaphragm injury. *Am Surg* 2002;68:633-9.
13. Lomoschitz FM, Eisenhuber E, Linnau KF, Peloschek P, Schoder M, Bankier AA. Imaging of chest trauma: radiological patterns of injury and diagnostic algorithms. *Eur J Radiol* 2003;48:61-70.
14. Petrone P, Leppaniemi A, Inaba K, et al. Diaphragmatic injuries: challenges in the diagnosis and management. *Trauma* 2007;9:227-36.
15. Arak T, Solheim K, Pillgram-Larsen J. Diaphragmatic injuries. *Injury* 1997;28:113-7.
16. Reber PU, Schmied B, Seiler CA, Baer HU, Patel AG, Büchler MW. Missed diaphragmatic injuries and their long-term sequelae. *J Trauma* 1998;44:183-8.
17. Gelman R, Mirvis SE, Gens D. Diaphragmatic rupture due to blunt trauma: sensitivity of plain chest radiographs. *AJR Am J Roentgenol* 1991;156:51-7.