

Is ultrasound guidance necessary to avoid complications in the implantation of venous access ports?

İlhan B,¹ İbrahim Fethi Azamat,¹ Süleyman Bademler,² Ömer Avlanmis,³
Görkem Uzunyolcu,¹ Başak Erginel,⁴ Fatih Yanar¹

¹Department of General Surgery, Istanbul University Faculty of Medicine, İstanbul-Türkiye

²Department of General Surgery, Istanbul University, Oncology Institute, İstanbul-Türkiye

³Department of General Surgery, Liv Hospital Ulus, İstanbul-Türkiye

⁴Department of Pediatric Surgery, Istanbul University Faculty of Medicine, İstanbul-Türkiye

ABSTRACT

BACKGROUND: The aim of this study was to present demographic information of patients undergoing totally implantable venous access port (TIVAP) implantation and to investigate the rates of early and late complications, assessing the benefits of performing the procedure under US guidance.

METHODS: From May 2018 to December 2023, the outcomes of a total of 537 TIVAP implantation procedures were analyzed retrospectively. Data of the surgeons' experiences for both puncture methods (anatomical landmarks and ultrasound guidance) are presented in the study.

RESULTS: The average age of the patients was 53.1 ± 11.9 years, and 261 (48.6%) were female. The right subclavian vein was the preferred insertion site. Fourteen patients developed early complications and 11 developed late complications. Arterial puncture was the most common early complication, while catheter-related infection was the most common late complication. The age, sex, and body mass index of the patients were not independent risk factors for developing complications. Early complications increased as the number of puncture attempts did ($p=0.034$) and developed significantly less when ultrasound guidance was used during insertion ($p=0.011$).

CONCLUSION: The risk of developing complications was not affected by patient's age or sex. In addition, body mass index was not shown to be an independent risk factor for patients developing complications. It may be concluded from the study that early complications in particular can be reduced with ultrasound-guided implantation.

Keywords: Chemotherapy; complication; totally implantable venous access port; ultrasound.

INTRODUCTION

If the peripheral venous system is used in patients due to receive cancer treatment, these patients may be subject to repetitive cannulations and related consequences that may impair their quality of life. An implanted venous port is a long-term vascular access device often used to eliminate such adverse effects.^[1] These port systems are considered the most

appropriate method both for preventing repeated irritation of the patient's peripheral vascular pathways and for bolstering the patient's morale during the long-term treatment process. In short, they are perceived as the most comfortable options in oncology-based treatment processes.^[2-5] However, both during and in the follow-up of totally implantable venous access port (TIVAP) implantation, some complications may occur. These complications can be classified as either early

Cite this article as: İlhan B, Azamat İF, Bademler S, Avlanmis Ö, Uzunyolcu G, Erginel B, Yanar F. Is ultrasound guidance necessary to avoid complications in the implantation of venous access ports? *Ulus Travma Acil Cerrahi Derg* 2024;30:210-215.

Address for correspondence: Fatih Yanar

Department of General Surgery, Istanbul University Faculty of Medicine, İstanbul, Türkiye

E-mail: yanar_fatih@yahoo.com

Ulus Travma Acil Cerrahi Derg 2024;30(3):210-215 DOI: 10.14744/tjtes.2024.58665

Submitted: 24.02.2024 Revised: 28.02.2024 Accepted: 10.03.2024 Published: 13.03.2024

OPEN ACCESS This is an open access article under the CC BY-NC license (<http://creativecommons.org/licenses/by-nc/4.0/>).



complications (such as pneumothorax, arterial puncture, and malposition) or late complications (including catheter-related infection, thrombosis, and catheter fracture).^[6-8]

The interest in enhancing the safety and effectiveness of Totally Implantable Venous Access Port (TIVAP) implantation procedures has been growing. Techniques such as insertion with ultrasound (US) guidance have emerged as promising approaches, aiming to reduce complications and improve procedural success rates. Nonetheless, the impact of US guidance on the complication rates of TIVAP implantation remains an area ripe for continued research. This study aims to evaluate the demographic information of patients undergoing TIVAP implantation, utilizing either anatomical landmarks or US guidance techniques. Furthermore, it seeks to investigate the incidence of early and late complications, assessing the advantages of conducting the procedure under US guidance.

MATERIALS AND METHODS

Study protocol

Retrospectively, 537 TIVAP implantation procedures conducted between May 2018 and December 2023 were analyzed and included in this study. The right subclavian vein (SCV) route was utilized for these implantations. Techniques involving both anatomical landmarks and ultrasound-guided implantation methods were employed. Patients whose implantation procedures via the SCV route failed and who subsequently underwent the procedure through alternative routes were excluded from the study. The demographic details of the patients, observations made during the procedures, and any complications encountered were meticulously recorded.

The study's protocol received approval from the Ethical Committee of Istanbul University, Istanbul Medical Faculty (Decision year/no: 2023/1564). All participants were fully briefed on the diagnostic and therapeutic procedures involved, and written informed consent was obtained prior to their inclusion.

Port catheter insertion

Anatomical landmarks were identified using both conventional percutaneous and ultrasound (US) guidance methods before applying local anesthetic to the puncture and pocket sites for implantation. The surgical area was sterilized with an alcoholic chlorhexidine solution. Venous access was achieved using an 18G needle, through which a 0.088 mm J-tipped flexible wire was inserted and subsequently removed. An 8-F dilator was passed over the wire, which was then removed, and a 7.5-F catheter was inserted through the dilator toward the subclavian vein (SCV) and advanced to the cavoatrial junction. The catheter length, determined by the patient's height and thoracic surface measurement, ranged from 14 to 19 cm during the initial clinical implantation phase. The electrocardiography (ECG) technique became the preferred method to confirm the catheter tip's position near the atrio-caval junction. A pocket for the port chamber was formed 2 cm below the clavicle, where the port chamber was placed and secured

with sutures. The incision length varied between 2 to 4 cm. The proximal tip and the port chamber were connected by subcutaneous tunneling.

In the US-guided method, a 7.5 MHz superficial real-time US probe (Aloka Prosound Alfa 7 sonography machine; 10-14 MHz Linear probe) was employed. The probe, covered with a sterile sheath, was positioned parallel to the infraclavicular area to differentiate the vein from the artery by its non-pulsatile nature and change in diameter upon compression. Following the procedure, chest X-ray radiography was performed for all patients to confirm the catheter's placement and to check for early complications.

Statistical Analysis

Data on patient demographics, number of puncture attempts, insertion methods, and complications were meticulously collected. Each variable's association with complications was assessed using Fisher's exact test or the Chi-square test in two-tailed univariate analyses. The independent T-test was utilized to explore the relationship between complications and patient demographics, specifically age and body mass index (BMI). Additionally, a stepwise backward logistic regression model was applied in the multivariate analysis to discern significant associations, with early complication designated as the dependent variable. The results were presented with a 95% confidence interval, and a P-value <0.05 was considered to indicate statistical significance. All statistical analyses were performed using the Statistical Package for the Social Sciences (SPSS) version 21.0 (SPSS, Inc., Chicago, IL, USA).

RESULTS

The mean age of the patients was 53.1 ± 11.9 years, with a range from 28 to 75 years. The average body mass index (BMI) was 24.9 ± 5.1 , spanning from 16 to 51. Of the participants, 261 (48.6%) were female and 276 (51.4%) were male. Successful insertion on the first puncture attempt occurred in 223 (41.5%) cases, whereas the remainder, 314 (58.5%), required a second or subsequent attempts. The conventional anatomical landmark method was used for 256 (47.8%) punctures, and ultrasound (US) guidance was utilized in 281 (52.2%) punctures. In total, 25 patients developed complications, including 14 early and 11 late complications. These outcomes, along with demographics and observations during the procedures, are summarized in Table 1.

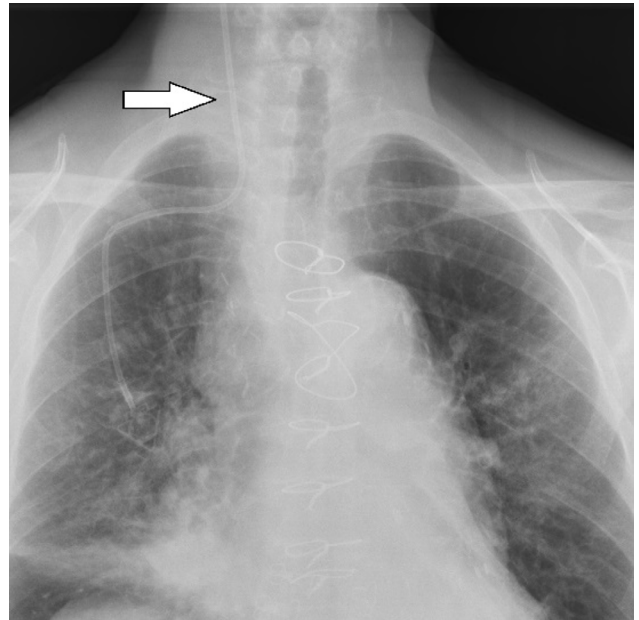
Early complications detected during or immediately after the procedure included seven arterial punctures, four pneumothoraxes, and three malpositions. Arterial punctures, while common, did not necessitate further intervention beyond minimal compression, indicating their minimal impact on procedure continuation. All arterial punctures resolved with simple pressure application, requiring no additional intervention. Of the pneumothoraxes encountered, two were minimal and resolved spontaneously, whereas two necessitated hospitalization and thoracic tube drainage. One case, in a patient with

Table 1. Demographics of patients, complications

Total=537	n	%
Mean age, range	53.1 (± 11.9)	(28-75)
Mean body mass index, range	24.9 (± 5.1)	(16-51)
Sex		
Male	276	51.4
Female	261	48.6
Number of punctures		
1	223	41.5
≥ 2	314	58.5
Insertion method		
Anatomic landmark	256	47.8
Ultrasound	281	52.2
Early complications	14	2.6
Arterial puncture	7	1.3
Pneumothorax	4	0.7
Malposition	3	0.6
Late complications	11	2.1
Catheter related infection	8	1.5
Mild	5	0.9
Severe	3	0.6
Catheter fracture	2	0.4
Deep vein thrombosis	1	0.2
Overall complication	25	4.7

a 70-year smoking history, presented a persistent air leak and massive pneumothorax, recurring even after initial thoracic tube drainage. (Fig. 1). This case was ultimately resolved on the 14th day with the introduction of a digital tube drainage system (Medela) and a blood patch material injection through the drainage tube, leading to the removal of the system without further complications. Catheter malpositions were corrected using conventional angiography, facilitating proper placement. (Fig. 2)

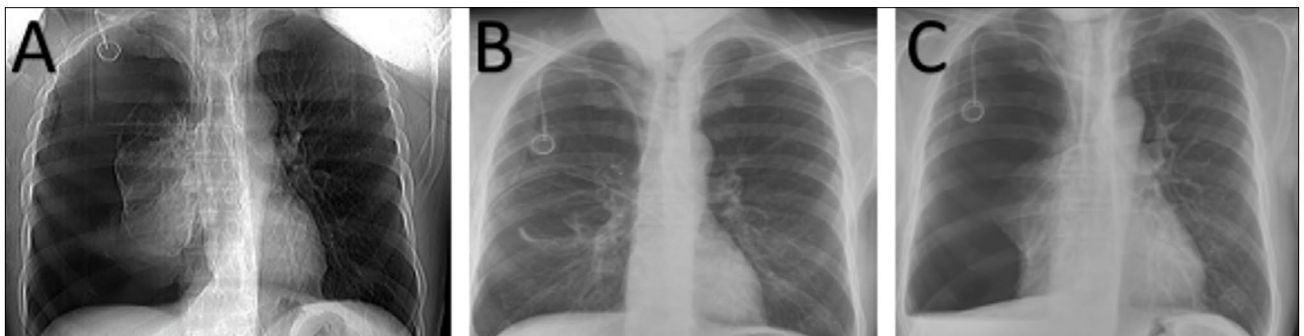
Late complications comprised eight catheter-related infections, two catheter fractures, and one vein thrombosis. Of

**Figure 2.** Malposition into the jugular vein.

the eight catheter-related infections, symptoms in five cases regressed with oral antibiotic treatment alone, negating the need for further intervention. However, three cases presented with severe local wound infections and/or signs of septicemia, necessitating catheter removal and hospitalization for intravenous antibiotic therapy due to escalating infection.

Despite initial confirmations of correct catheter placement via early X-rays, two instances of catheter fracture (pinch-off syndrome) were later identified through follow-up X-rays and additional computed tomography, after the obstruction was noted during the second chemotherapy regimen infusion. The fractured catheter segments were successfully extracted from the right ventricle with the aid of conventional angiography, and the associated port chambers were also removed. (Fig. 3) Subsequently, treatment for these patients continued via peripheral venous access.

Among the 25 noted complications, seven (1.3%)—including two pneumothoraxes, three catheter-related infections, and two cases of pinch-off syndrome—required significant intervention leading to hospitalization.

**Figure 1.** (A) Massive pneumothorax, (B) Resolved pneumothorax in the X-ray, (C) Repeated pneumothorax after removing the drainage tube.

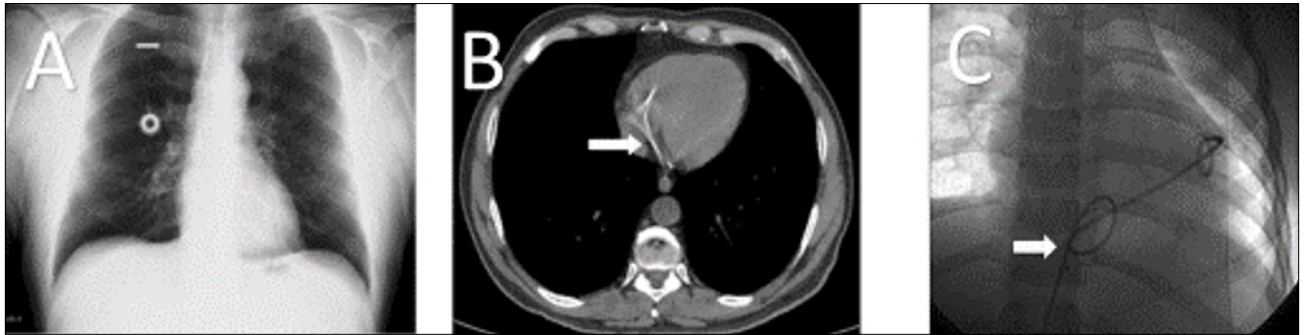


Figure 3. (A) Pinch-off syndrome due to chronic compression between the clavicle and the first rib (X-ray imaging), (B) Part of a fractured catheter is seen in the heart on a computed tomography scan, (C) Fractured part of a catheter removed under angiography from the right ventricle.

In the cohort of patients who developed complications, neither age nor sex was identified as a risk factor for the onset of complications. Although a high BMI was found to be a risk factor for early complications in univariate analysis ($p=0.049$), it was not significant in multivariate analysis ($p=0.26$). An increased number of puncture attempts was significantly associated with the development of early complications ($p=0.029$). Furthermore, US guidance during the puncture process was found to significantly decrease the risk of early complications

($p=0.018$). No determinants were identified for the development of late or overall complications.

Multivariate analyses revealed that the number of puncture attempts significantly increased the risk of early complications, while US guidance significantly decreased this incidence. Specifically, a puncture number of two or more, compared with one, resulted in a 3.39-fold increased risk of early complications, while US guidance was associated with a 4.16-fold reduction in risk (Tables 2 and 3).

Table 2. Factors associated with complications

	Early complications		Late complications		Overall complications	
	n (%)	p	n (%)	p	n (%)	p
Mean age, (Complication no/yes)	53.5/51.8	0.06	53.2/52.5	0.24	53.3/52.1	0.14
Mean body mass index, (Complication no/yes)	24.7/25.8	0.049	25.0/24.7	0.43	24.8/25.1	0.32
Male	8 (2.9%)	0.44	4 (1.4%)	0.24	12 (4.3%)	0.44
Female	6 (2.3%)		7 (2.7%)		13 (5.0%)	
Number of punctures						
1	2 (0.9%)	0.029	5 (2.2%)	0.51	7 (3.1%)	0.11
≥ 2	12 (3.8%)		6 (1.9%)		18 (5.7%)	
Insertion method						
Anatomic landmark	11 (4.3%)	0.018	5 (2.0%)	0.56	16 (6.3%)	0.07
Ultrasound	3 (1.1%)		6 (2.1%)		9 (3.2%)	

Table 3. Multivariate logistic regression analysis on significant parameters for early complications

	OR	95% C.I. EXP(B)		p
		Lower	Upper	
Compared with body mass index ≤ 25				
>25	1.24	0.94	1.96	0.26
Compared with 1 puncture				
≥ 2	3.39	0.91	7.81	0.034
Compared with ultrasound				
Anatomical landmark	4.16	1.14	10.08	0.011

DISCUSSION

Many studies in the literature have evaluated the factors that cause complications related to port catheter implantation in cancer patients. However, conflicting results have been obtained regarding the possible risk factors for complications. For example, some studies have found a significant association between the increasing age of patients and an increased risk of infection, while others have argued that there is no such association.^[9,10] In our study, there was no association between patient age and the frequency of complications. Although some studies concluded that a high body mass index (BMI) would increase the risk of complications, others associated an increased pneumothorax risk with a low BMI.^[11,12] In the current study, although there was an association between high BMI and increased risk of complications in univariate analysis, no such association was found in multivariate analysis.

The literature shows a significant relationship between the increasing number of puncture attempts and increasing complication rates. Consistent with this, the current study revealed a similar association between the number of puncture attempts and increased early complication risk. In addition, there is evidence that implantation using ultrasound (US) guidance might provide a decreased rate of complications. In this study, a similar correlation was found between puncture following US guidance and a lower early complication incidence. This suggests that US-guided implantation is more likely to be used to prevent early complications.^[13]

The percutaneous approach remains the most commonly utilized technique for TIVAP implantation, yet immediate complications persist despite specialists' endeavors. Clinical experience is recognized as paramount in mitigating complications associated with the percutaneous approach.^[14] This method, practiced extensively over time, has demonstrated a high level of expertise and minimal complication rates. Previous investigations have reported complication rates ranging from 1.8% to 30.2% attributed to TIVAP implantation.^[15] Notably, the complication rate observed in this study period for surgeons was 4.7%, indicative of a commendably low rate attributable to the proficiency of the high-level training center. Pneumothorax is acknowledged as the most severe complication linked to the traditional anatomical landmark approach, with interventional radiologists reporting an incidence of 1–2.5%, whereas surgeons report rates of 2.4%–4.3%.^[16–20] In our study, only 4 (0.7%) patients experienced pneumothorax, with 2 necessitating thoracic tube drainage and hospitalization. Literature findings suggest that utilizing US guidance and the jugular vein routing can maintain a low port catheter malposition rate of 1.1%.^[21] In our study, malposition occurred at a rate of 0.6% in the entire patient cohort when employing the SCV route. Across studies encompassing diverse disease groups and implantation routes, infection rates attributed to TIVAD implantation range from 6.6% to 14%.^[22,23] For instance, a study involving 2996 breast cancer patients who un-

derwent TIVAD implantation reported an infection incidence of 1.6%.^[24] In our study, the infection rate stood at 1.5%, with no identifiable predictor for late complications following TIVAP implantation. Catheter fracture (pinch-off syndrome), a rare complication resulting from mechanical compression of the catheter between the clavicle and the first rib in SCV catheterization, was previously documented in our research, with five instances associated with TIVAP implantation via the right SCV.^[25] During the current study, two catheter fractures were observed, and the same removal methods for fractured catheter segments under angiography were employed.

The limitation of our study arises from its retrospective design and limited number of patients. Furthermore, the study did not investigate the effects of some factors that might affect port complications, such as the use of additional, potentially nutritional treatment products.

CONCLUSION

The implantation of a totally implantable port catheter is a valuable tool in the treatment of cancer patients; however, complications may arise during insertion or subsequent follow-up. Our findings suggest that the incidence of complications is not influenced by a patient's age or sex. Furthermore, utilizing ultrasound guidance during insertion was associated with a decreased rate of complications, particularly early complications. Therefore, prioritizing ultrasound-guided implantation may help mitigate the risk of complications.

Ethics Committee Approval: This study was approved by the Istanbul University Faculty of Medicine Ethics Committee (Date: 24.08.2023, Decision No:2065927).

Peer-review: Externally peer-reviewed.

Authorship Contributions: Concept: F.Y.; Design: B.İ.; Supervision: F.Y.; Resource: Ö.A.; Materials: İ.A.; Data collection and/or processing: G.U.; Analysis and/or interpretation: İ.A.; Literature search: S.B.; Writing: B.İ.; Critical review: B.E.

Conflict of Interest: None declared.

Financial Disclosure: The author declared that this study has received no financial support.

REFERENCES

1. Niederhuber JE, Ensminger W, Gyves JW. Totally implanted venous and arterial access system to replace external catheters in cancer treatment. *Surgery* 1982;92:706–12.
2. Bustos C, Aguinaga A, Carmona-Torre F, Del Pozo JL. Long-term catheterization: current approaches in the diagnosis and treatment of port-related infections. *Infect Drug Resist* 2014;7:25–35. [\[CrossRef\]](#)
3. Xu H, Chen R, Jiang C, You S, Zhu Q, Li Y, et al. Implanting totally implantable venous access ports in the upper arm is feasible and safe for patients with early breast cancer. *J Vasc Access* 2020;21:609–14. [\[CrossRef\]](#)
4. Machat S, Eisenhuber E, Pfarl G, Stübler J, Koelblinger C, Zacherl J, et al. Complications of central venous port systems: a pictorial review. *Insights Imaging* 2019;10:86. [\[CrossRef\]](#)
5. Fang S, Yang J, Song L, Jiang Y, Liu Y. Comparison of three types of central venous catheters in patients with malignant tumor receiving chemo-

- therapy. Patient Prefer Adherence 2017;11:1197–204. [CrossRef]
- Surov A, Wienke A, Carter JM, Stoevesandt D, Behrmann C, Spielmann RP, et al. Intravascular embolization of venous catheter--causes, clinical signs, and management: a systematic review. JPEN J Parenter Enteral Nutr. 2009; 33:677–85. [CrossRef]
 - Ishizuka M, Nagata H, Takagi K, Kubota K. Total parenteral nutrition is a major risk factor for central venous catheter-related bloodstream infection in colorectal cancer patients receiving postoperative chemotherapy. Eur Surg Res 2008;41:341–5. [CrossRef]
 - Vescia S, Baumgärtner AK, Jacobs VR, Kiechle-Bahat M, Rody A, Loibl S, et al. Management of venous port systems in oncology: a review of current evidence. Ann Oncol 2008;19:9–15. [CrossRef]
 - Ji L, Yang J, Miao J, Shao Q, Cao Y, Li H. Infections related to totally implantable venous-access ports: long-term experience in one center. Cell Biochem Biophys 2015;72:235–40. [CrossRef]
 - Maki DG, Kluger DM, Crnich CJ. The risk of bloodstream infection in adults with different intravascular devices: a systematic review of 200 published prospective studies. Mayo Clin Proc 2006;81:1159–71. [CrossRef]
 - Ignatov A, Hoffman O, Smith B, Fahlke J, Peters B, Bischoff J, et al. An 11-year retrospective study of totally implanted central venous access ports: complications and patient satisfaction. Eur J Surg Oncol 2009;35:241–6. [CrossRef]
 - Palmaers T, Frank P, Eismann H, Sieg L, Leffler A, Schmitt H, et al. Catheterization of the subclavian vein and the risk of pneumothorax : Mechanical ventilation increases the risk of pneumothorax during infraclavicular landmark-guided subclavian vein puncture: a prospective randomized study. Anaesthetist 2019;68:309–16. [CrossRef]
 - Bademler S, Üçüncü M, Yıldırım İ, Karanlık H. Risk factors for complications in cancer patients with totally implantable access ports: A retrospective study and review of the literature. J Int Med Res 2019;47:702–9.
 - Biffi R, Orsi F, Pozzi S, Pace U, Bonomo G, Monfardini L, et al. Best choice of central venous insertion site for the prevention of catheter-related complications in adult patients who need cancer therapy: a randomized trial. Ann Oncol 2009;20:935–40. [CrossRef]
 - Biffi R, de Braud F, Orsi F, Pozzi S, Mauri S, Goldhirsch A, et al. Totally implantable central venous access ports for long-term chemotherapy. A prospective study analyzing complications and costs of 333 devices with a minimum follow-up of 180 days. Ann Oncol 1998;9:767–73. [CrossRef]
 - Simpson KR, Hovsepian DM, Picus D. Interventional radiologic placement of chest wall ports: results and complications in 161 consecutive placements. J Vasc Interv Radiol 1997;8:189–95. [CrossRef]
 - Struk DW, Bennett JD, Kozak RI. Insertion of subcutaneous central venous infusion ports by interventional radiologists. Can Assoc Radiol J 1995;46:32–6. [CrossRef]
 - Shetty PC, Mody MK, Kastan DJ, Sharma RP, Burke MW, Venugopal C, et al. Outcome of 350 implanted chest ports placed by interventional radiologists. J Vasc Interv Radiol 1997;8:991–5. [CrossRef]
 - Nelson BE, Mayer AR, Tseng PC, Schwartz PE. Experience with the intravenous totally implanted port in patients with gynecologic malignancies. Gynecol Oncol 1994;53:98–102. [CrossRef]
 - Harvey WH, Pick TE, Reed K, Solenberger RI. A prospective evaluation of the Port-A-Cath implantable venous access system in chronically ill adults and children. Surg Gynecol Obstet 1989;169:495–500. [CrossRef]
 - Liu W, Han Q, Li L, Chi J, Liu X, Gu Y. Catheter malposition analysis of totally implantable venous access port in breast cancer patients. Front Surg 2023;9:1061826. [CrossRef]
 - Chang TC, Yen MH, Kiu KT. Incidence and risk factor for infection of totally implantable venous access port. Langenbecks Arch Surg 2022;407:343–51. [CrossRef]
 - Zerati AE, Figueredo TR, de Moraes RD, da Cruz AM, da Motta-Leal Filho JM, Freire MP, et al. Risk factors for infectious and noninfectious complications of totally implantable venous catheters in cancer patients. J Vasc Surg Venous Lymphat Disord 2016;4:200–5. [CrossRef]
 - Ma LL, Liu Y, Wang J, Chang Y, Yu L, Geng C. Totally implantable venous access port systems and associated complications: A single-institution retrospective analysis of 2,996 breast cancer patients. Mol Clin Oncol 2016;4:456–60. [CrossRef]
 - İlhan BM, Sormaz İC, Türkay R. Pinch-off syndrome, a rare complication of totally implantable venous access device implantation: a case series and literature review. Korean J Thorac Cardiovasc Surg 2018;51:333–7.

ORJİNAL ÇALIŞMA - ÖZ

Venöz erişim portlarının implantasyonunda komplikasyonları önlemek için ultrason kılavuzluğu gerekli midir?

Burak İlhan,¹ İbrahim Fethi Azamat,¹ Süleyman Bademler,² Omer Avlanmis,³ Görkem Uzunolcu,¹ Basak Erginel,⁴ Fatih Yanar¹

¹İstanbul Üniversitesi İstanbul Tıp Fakültesi, Genel Cerrahi Anabilim Dalı, İstanbul, Türkiye

²İstanbul Üniversitesi İstanbul Tıp Fakültesi, Onkoloji Enstitüsü, Genel Cerrahi Anabilim Dalı, İstanbul, Türkiye

³Liv Hospital Ulus, Genel Cerrahi Kliniği, İstanbul, Türkiye

⁴İstanbul Üniversitesi İstanbul Tıp Fakültesi, Çocuk Cerrahisi Anabilim Dalı, İstanbul, Türkiye

AMAÇ: Bu çalışmanın amacı, tamamen implante edilebilir venöz erişim portu (TİVAP) implantasyonu yapılan hastaların demografik bilgilerini sunmak, erken ve geç komplikasyon oranlarını araştırmak ve işlemin ultrasonografi (US) kılavuzluğunda yapılmasının faydalarını değerlendirmektir.

GEREÇ VE YÖNTEM: Mayıs 2018 ile Aralık 2023 tarihleri arasında 537 TİVAP implantasyon prosedürünün sonuçları retrospektif olarak analiz edildi. Çalışmada cerrahların her iki ponksiyon yöntemi (anatomik işaretler ve ultrason kılavuzluğu) için deneyimlerine ilişkin veriler sunulmuştur.

BULGULAR: Hastaların ortalama yaşı 53.1 ± 11.9 yıldır ve 261'i (%48.6) kadındır. Sağ subklavyen ven tercih edilen giriş yeriydi. On dört hastada erken komplikasyon ve 11 hastada geç komplikasyon gelişti. Arteriyel ponksiyon en sık görülen erken komplikasyon iken, kateterle ilişkili enfeksiyon en sık görülen geç komplikasyondur. Hastaların yaşı, cinsiyeti ve vücut kitle indeksi komplikasyon gelişimi için bağımsız risk faktörleri değildi. Erken komplikasyonlar ponksiyon girişim sayısı arttıkça daha fazla görüldü (p=0.034) ve ultrason kılavuzluğu kullanıldığında anlamlı olarak daha az görüldü (p=0.011).

SONUÇ: Komplikasyon gelişme riski hastanın yaşı veya cinsiyetinden etkilenmemiştir. Ayrıca, vücut kitle indeksinin komplikasyon gelişen hastalar için bağımsız bir risk faktörü olmadığı gösterilmiştir. Çalışmadan, ultrason kılavuzluğunda implantasyon ile özellikle erken dönem komplikasyonların azaltılabileceği sonucu çıkarılabilir.

Anahtar sözcükler: Kemoterapi; komplikasyon; total implante edilebilir venöz erişim portu; ultrasonografi.

Ulus Travma Acil Cerrahi Derg 2024;30(3):210-215 DOI: 10.14744/tjtes.2024.58665