



Small bowel perforation after drawing a blood sample in the femoral artery: a case report

Femoral arterden kan örneği alınması sonrası ince bağırsak perforasyonu:
Olgu sunumu

Cengiz ARA,¹ Sacid ÇOBAN,¹ Burak IŞIK,¹ Canan Ceran ÖZCAN,² Sezai YILMAZ¹

Small bowel perforation is a rare complication of femoral artery access in cases of femoral hernia. A 48-year-old woman was admitted to the intensive care unit due to pulmonary insufficiency. After a routine femoral arterial blood gas analysis, severe abdominal pain and nausea began. She underwent emergency laparotomy due to acute abdomen. Laparotomy revealed small bowel perforation. Segmental resection and end-to-end anastomosis were performed. The femoral canal was closed using plaque mesh. Special attention is needed during femoral artery access to avoid accidental small bowel perforation. As seen in this case, a careful examination should be done in cases of femoral hernia.

Key Words: Femoral artery; femoral hernia; small bowel perforation.

Femoral herni olgularında, femoral artere uygulanan invaziv girişimler sonucu ince bağırsak perforasyonu nadir görülen bir komplikasyondur. Pulmoner yetersizlik nedeniyle yoğun bakımda takip edilen 48 yaşında kadın hastada, kan gazı incelenmesi amacıyla femoral artere uygulanan girişimden sonra şiddetli kusma ve karın ağrısı oldu. Hasta akut karın olarak değerlendirilerek ameliyata alındı. Laparotomide ince bağırsak perforasyonu saptanması üzerine ince bağırsak rezeksiyonu, uç-uç anastomoz yapıldı. Femoral kanal plak meş ile kapatıldı. Femoral arter girişimleri esnasında iyatrojenik ince bağırsak perforasyonunu önlemek için femoral herni olasılığı gözönüne alınarak dikkatli fiziksel inceleme yapılmalıdır.

Anahtar Sözcükler: Femoral arter; femoral herni; ince bağırsak perforasyonu.

Femoral hernia is a subtle condition, frequently diagnosed in asymptomatic patients, and is often associated with life-threatening complications. Acute emergency presentation of femoral hernia cases can vary, and the correct diagnosis is commonly missed until the patient undergoes surgery. Incarceration and strangulation are feared complications that lead to morbidity and death.^[1] Small bowel perforation is a rare complication of femoral artery access in cases of femoral hernias.^[2]

We present herein an unusual case and perhaps the first in the literature of perforation of the small bowel after drawing a blood sample in the femoral artery.

CASE REPORT

A 48-year-old obese woman was admitted to the intensive care unit because of chronic obstructive pulmonary disease. Femoral arterial blood samples for

routine blood gas analysis were required several times (Figs. 1, 2). After interventions, the needle insertion site was compressed manually to prevent hematoma. Seventy-two hours later, she presented with severe abdominal pain and nausea. Abdominal tenderness and rebound were present on physical examination. Plain abdominal radiography showed air-fluid levels. An ultrasound examination revealed free abdominal fluid in the pelvic space. White cell count was 16000/mm³. The patient underwent laparotomy after nasogastric suction and appropriate fluid replacement. Laparotomy revealed free intestinal fluid in the pelvic space. She had a right femoral hernia containing a knuckle of ileal segment that was adhesive to the hernia sac. Exploration revealed an accidental perforation of about 0.5 cm in diameter due to the several femoral access attempts. Segmental resection and end-to-end anastomosis were performed. The femoral canal was

Departments of ¹General Surgery, ²Pediatric Surgery, İnönü University Faculty of Medicine, Malatya, Turkey.

İnönü Üniversitesi Tıp Fakültesi, ¹Genel Cerrahi Anabilim Dalı, ²Çocuk Cerrahisi Anabilim Dalı, Malatya.

Correspondence (İletişim): Cengiz Ara, M.D. İnönü Üniversitesi Turgut Özal Tıp Merkezi Genel Cerrahi Anabilim Dalı, Malatya, Turkey. Tel: +90 - 422 - 341 06 87 e-mail (e-posta): cara@inonu.edu.tr

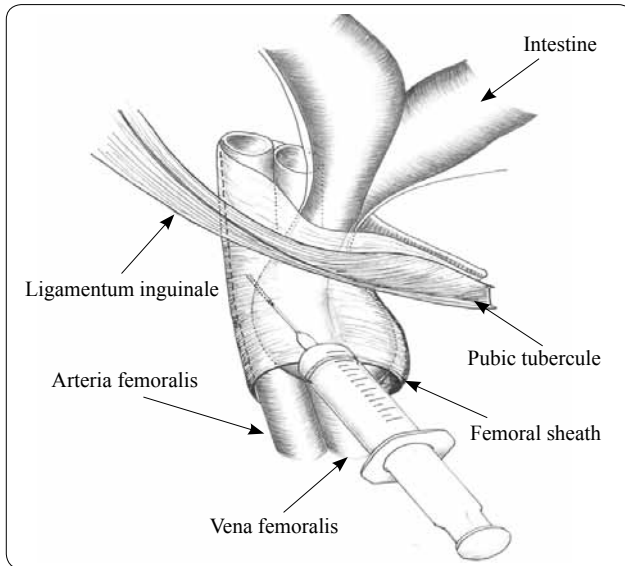


Fig. 1. Illustration of the femoral access for obtaining the blood sample.

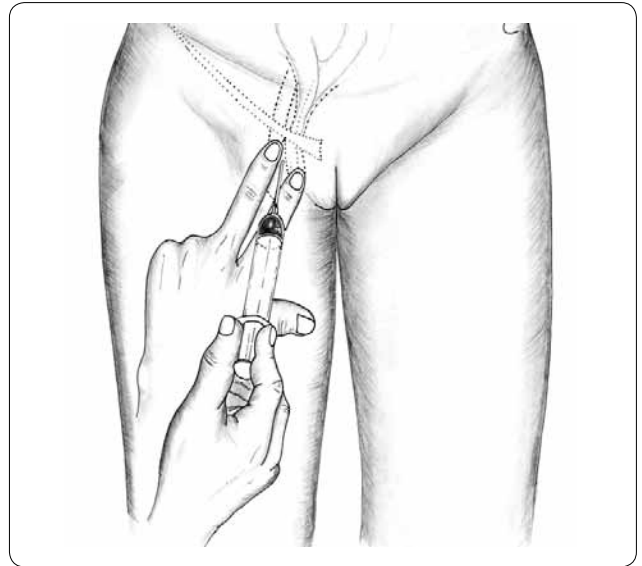


Fig. 2. Illustration of the penetration of the syringe into the intestinal wall in the femoral hernia sac.

closed using plaque mesh. The patient's recovery was uneventful.

DISCUSSION

Femoral hernia is not easily diagnosed preoperatively because it is hard to palpate when asymptomatic, and when swollen, it may resemble an inguinal hernia.^[3,4] Femoral hernias are generally acquired and occur in association with those conditions that increase intraabdominal pressure over a prolonged period of time, such as in pregnancy, obesity, intrapelvic masses, chronic cough, urinary retention, or constipation.^[4] In our patient, obesity and chronic cough were present. The needle insertion that was required several times was probably due to inadequate localization of the femoral artery due to the patient's obesity and feeble pulse muffled by overlying bowel while taking the blood sample. The perforation occurred due to the repetitive penetration of the syringe into the intestinal wall in the femoral hernia sac as shown in the figure. After the perforation due to penetration, the manual compression undertaken to prevent the hematoma may have traumatized the bowel loop. Perforation of the small bowel after drawing a blood sample may be an as yet unreported complication of this routine procedure. Perforation occurs with prolonged necrosis and loss of the integrity of the bowel wall, but more often

than not, the process stays in the hernia sac unless the loop that is already compromised is reduced mechanically or spontaneously.^[2,5,6] Acute awareness and early operation appear to be the key to prevent this rare condition and its potential complications.

In conclusion, femoral hernia injury is a serious complication of vascular interventions. Knowledge of this possible risk may remind healthcare providers to consider the possibility of femoral hernia and the importance of a careful examination.

REFERENCES

1. Alvarez JA, Baldonado RF, Bear IG, Solís JA, Alvarez P, Jorge JJ. Incarcerated groin hernias in adults: presentation and outcome. *Hernia* 2004;8:121-6.
2. Seyfarth T, Baumgartner I, Triller J, Dinkel HP. Accidental small bowel perforation after antegrade femoral artery access for percutaneous thromboembolectomy and angioplasty. *J Endovasc Ther* 2002;9:685-9.
3. Ponka JL, Brush BE. Problem of femoral hernia. *Arch Surg* 1971;102:417-23.
4. Rhind JR. Lateral femoral hernia. *J R Coll Surg Edinb* 1971;16:299-300.
5. Naude GP, Ocon S, Bongard F. Femoral hernia: the dire consequences of a missed diagnosis. *Am J Emerg Med* 1997;15:680-2.
6. Oncel M, Kurt N, Eser M, Bahadır I. Small bowel perforation due to blunt trauma directly to the inguinal region: a case report. *Hernia* 2003;7:218-9.