

# Wrapping degloved fingers with a distal-based radial forearm perforator flap: A repair method for multiple digital degloving injury

Yusuf Kenan Çoban, M.D., Özcan Öcük, M.D., Kaan Bekircan, M.D.

Department of Plastic Reconstructive and Aesthetic Surgery, İnönü University Turgut Özal Medical Center, Malatya-Turkey

## ABSTRACT

Degloving hand injuries present challenging situations to hand surgeons as they present with difficulties in reconstructive microsurgery, particularly in multiple digital injuries. Time is a limiting factor when multiple degloving finger amputations are present. Thus, we proposed a repair method for multiple degloving finger injuries that involves coverage with a distal-based reverse forearm flap of all injured fingers in a two-stage procedure. Early vigorous physical therapy after pedicle division of the flap at postoperative third week eliminates joint stiffness problems at wrist and metacarpophalangeal joints.

**Keywords:** Degloved fingers; radial forearm flap; reverse flap.

## INTRODUCTION

The three types of mechanisms or nature of injury are clean-cut, crush-cut, and crush-avulsion. Degloving injury belongs to the last type of mechanism. As surgeons continue to push the borders of microsurgery, novel techniques are prepared to manage the difficulties of degloving avulsed digits. Venous flow-through flaps or transfer of vessels from adjacent fingers are some of the novel techniques for recovering degloved fingers.<sup>[1,2]</sup> When the possibility of replantation is not feasible, then some sort of flap must be used to cover the defect. The commonly used methods for hand degloving injury defects include the use of abdominal flaps, anterolateral thigh flap, latissimus dorsi flap, medial arm, and cutaneous free flaps.<sup>[1-3]</sup> Restoration with abdominal flaps has been shown to lead to poor recovery of hand functions in degloving injuries.<sup>[4]</sup> There is no one ideal operation to achieve all desired outcomes for the degloved hand. Nazerani et al.<sup>[5]</sup> described a modified

abdominal flap, which was designed in two layers. One layer covers the dorsum and the other is created in the fatty layer with separate compartments for each finger. The volar surface is left to granulate and is then covered by grafts. All these modifications result in a bulky mass on the fingers and hand.

Radial forearm flap has a thin pliable soft tissue structure. Several reports have established the ability of this flap for reconstruction of ipsilateral hand injuries.<sup>[6,7]</sup> There are appropriately 10 small perforators arising from the distal radial artery around the radial styloid process on which the flap may be based upon. Here we report a case with multiple digital degloving injuries treated with distal-based reverse radial forearm perforator flap and discuss the functional results.

## CASE REPORT

A 24-year-old male was wounded due to compression injury in his right hand in a textile factory. His physical examination showed that his third, fourth, and fifth fingers were totally degloved at the metacarpophalangeal joint level (Fig. 1a and b). He was immediately operated under general anesthesia. Severe multiple avulsion injuries averted the microsurgical replantation of the amputated parts. To cover the three injured fingers, a more proximal 6×13-cm reverse radial forearm flap was outlined. The involved upper limb was prepared in a sterile maneuver, and the arm was draped. Before inflating the tourniquet, the Allen test was performed. The flap was incised down to fascia and subfascially raised. Proximally, muscle belly and distally, tendon with paratenons were left in-

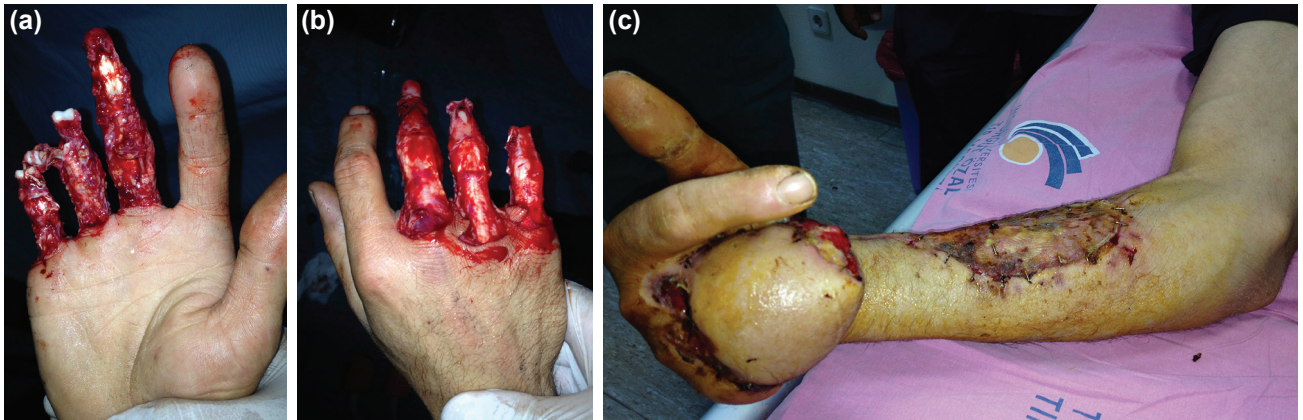
Address for correspondence: Yusuf Kenan Çoban, M.D.  
İnönü Üniversitesi Turgut Özal Tıp Merkezi, Plastik Rekonstrüktif ve Estetik Cerrahi Anabilim Dalı, Malatya, Turkey  
Tel: +90 422 - 341 06 60 E-mail: ykenanc@yahoo.com

Submitted: 21.10.2016  
Accepted: 12.04.2017

Ulus Travma Acil Cerrahi Derg  
2017;23(6):525-527  
doi: 10.5505/tjtes.2017.57227

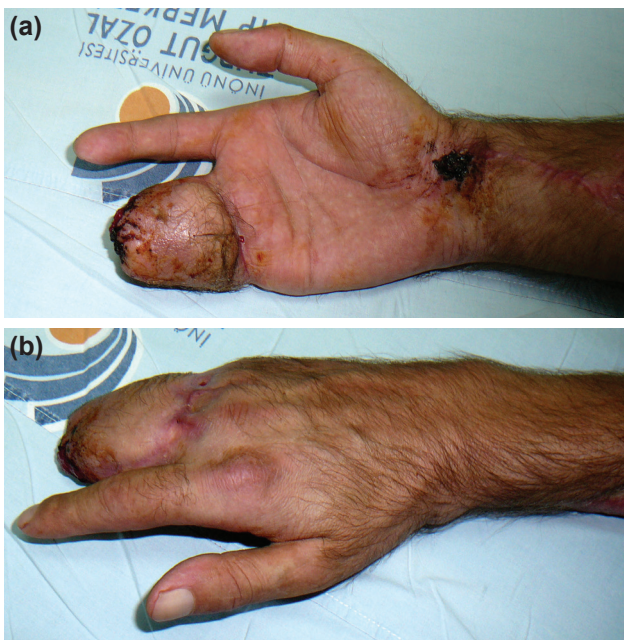

Copyright 2017  
TJTCS



**Figure 1.** (a) Dorsal view of the degloved fingers. (b) Volar view of the hand. (c) Early view after the flap transfer.

tact in the donor bed. The incision pierced the muscle bellies and reached the space between the flexor carpi radialis and brachioradialis. At this point, perfusion of the flap was observed after releasing tourniquet. No nerve repair was performed. The flap was then transferred and wrapped around the three fingers and donor side was skin grafted (Fig. 1c). The area between skin-grafted donor site and pivot point was primarily closed in a zig-zag fashion. A below elbow splint was placed for 3 weeks. At the third postoperative week, the flap and donor site uneventfully healed (Fig. 2a and b). Then, the pedicle was ligated and severed at the end of 3rd postoperative week. During the postoperative period, joint stiffness occurred at the wrist and metacarpophalangeal joints, which was resolved with early physical therapy. Nevertheless, 90% range of motion at the MP joint of the degloved fingers was achieved, and no functional deficits occurred at the wrist joint. At the 3<sup>rd</sup> postoperative month, fingers in the flap bulk had a good range of motion.



**Figure 2.** Late view showing the hand following the pedicle division (a) volar view (b) dorsal view.

## DISCUSSION

Degloving finger injuries are challenging situations for hand surgeons. Controversies exist regarding whether replantation or revision amputation should be performed. Urbaniak et al.<sup>[8]</sup> calculated that the general practice of replanting complete avulsion injuries results in compromised hand function. The mean survival rate for complete avulsion finger injuries undergoing replantation was 66%. Reconstruction of vessels with long vein grafts, venous flow-through flaps, or transfer of vessels from adjacent digits are options for repairing finger avulsion injury. Patients treated with microvascular revascularization or replantation were analyzed according to survival rate, total active range of motion (TAM), and two-point static discrimination data as functional outcomes.

Outcomes obtained from studies may aid surgeons in treatment decision making for finger avulsion injuries. The American Society for Surgery of The Hand grading of results of TAM in tendon repair categories has an excellent result of 100% for the corresponding contralateral digits.<sup>[9]</sup> Implantation into the abdomen of the degloved hand and tubed flaps usually result in an unacceptable outcome.

In multiple digit degloving injuries, there is a challenge for surgeons due to the complexity of replantation process of avulsion type amputations. In single avulsion type amputation, time is not a limiting factor. An experienced microsurgeon may successfully manage and get a desired outcome in a single degloving avulsion amputation. However, in case of presence of multiple digital degloving injuries, a need for different solution option is clearly evident. Therefore, we proposed a new repair procedure that covers multiple digit degloving injuries. In a fully flexed position of all degloved digits, a reverse radial forearm flap can easily be reach to cover all fingers. The only disadvantage of the process is maintaining the fixed position of the hand for 3 weeks. After dividing the pedicle and achieving wound healing, an early physical therapy can overcome joint stiffness problems of the hand. Noaman was the first to describe a reverse radial forearm flap wrapped around the complex degloved digit.<sup>[10]</sup> He performed 26 reversed radial

pedicle forearm flaps for 21 patients. He used a dorsal subcutaneous tunnel to reach the finger defects, all of which were single degloved fingers. Our technique was similar to his, but we had to cover much bigger defects as three ulnar side digits had degloved. The dimension of our flap was 6×13 cm, and it was difficult to pass such a big flap through the subcutaneous tunnel. Therefore, we chose a two-staged operation. A much longer pedicle of reverse radial forearm flap is needed to reach multiple digital degloved defects, unlike single degloved fingers. In this way, one retains a longitudinal curtain of fascia between the brachioradialis and flexor carpi radialis muscles, connecting the skin to the radial artery.

Conflict of interest: None declared.

## REFERENCES

1. Tok O, Tok L, Ozkaya D, Eraslan E, Ornek F, Bardak Y. Epidemiological characteristics and visual outcome after open globe injuries in children. *J AAPOS* 2011;15:556–61. [CrossRef]
2. Ulrich D, Pallua N. Treatment of avulsion injury of three fingers with a compound thoracodorsal artery perforator flap including serratus anterior fascia. *Microsurgery* 2009;29:556–9. [CrossRef]
3. Kim KS, Kim ES, Kim DY, Lee SY, Cho BH. Resurfacing of a totally degloved hand using thin perforator-based cutaneous free flaps. *Ann Plast Surg* 2003;50:77–81. [CrossRef]
4. Ju J, Li J, Hou R. Microsurgery in 46 cases with total hand degloving injury. *Asian J Surg* 2015;38:205–9. [CrossRef]
5. Nazerani S, Motamedi MH, Nazerani T, Bidarmaghz B. Treatment of traumatic degloving injuries of the fingers and hand: introducing the “compartmented abdominal flap”. *Tech Hand Up Extrem Surg* 2011;15:151–5. [CrossRef]
6. Coban YK, Balik O, Boran C. Cutaneous anthrax of the hand and its reconstruction with a reverse-flow radial forearm flap. *Ann Plast Surg* 2002;49:109–11. [CrossRef]
7. Kaufman MR, Jones NF. The reverse radial forearm flap for soft tissue reconstruction of the wrist and hand. *Tech Hand Up Extrem Surg* 2005;9:47–51. [CrossRef]
8. Urbaniak JR, Roth JH, Nunley JA, Goldner RD, Koman LA. The results of replantation after amputation of a single finger. *J Bone Joint Surg Am* 1985;67:611–9. [CrossRef]
9. Kay S, Wertz J, Wolff TW. Ring avulsion injuries: classification and prognosis. *J Hand Surg Am* 1989;14:204–13. [CrossRef]
10. Noaman HH. Salvage of complete degloved digits with reversed vascularized pedicled forearm flap: a new technique. *J Hand Surg Am* 2012;37:832–6. [CrossRef]

## OLGU SUNUMU - ÖZET

### Çoklu parmak degloving yaralanmasında bir tamir yöntemi: Yaralı parmakların distal bazlı radyal önkol perforator flebi ile sarılması

Dr. Yusuf Kenan Çoban, Dr. Özcan Öcük, Dr. Kaan Bekircan

İnönü Üniversitesi Turgut Özal Tıp Merkezi, Plastik Rekonstrüktif ve Estetik Cerrahi Anabilim Dalı, Malatya

Eldiven tarzı avulsiyon yaralanmaları el cerrahları çözülmesi zor problem oluşturur. Çünkü özellikle çoklu parmak yaralanmasında, rekonstrüktif mikrocerrahi, zaman sınırlaması gibi nedenlerle zorluklar taşır. Biz çoklu parmak “degloving” yaralanması olan olgular için yeni bir metod öneriyoruz. Bu teknik iki aşamalı olarak distal bazlı radyal ön kol flebi ile, yaralanmış tüm parmakların sarılması ve üçüncü hafta flep pedikülünün kesilmesini içeriyor. Erken yoğun fizik tedavi ile, el bileği ve parmak eklemlerinde oluşacak sertlikler önlenecektir.

Anahtar sözcükler: Deglove parmaklar; radyal ön kol flep; ters akımlı flep.

Ulus Travma Acil Cerrahi Derg 2017;23(6):525–527 doi: 10.5505/tjtes.2017.57227