

# Transcranial arrow injury: a case report

## Transkranyal ok yaralanması: Olgu sunumu

Gökhan KURT, Alp Özgün BÖRCEK, Özgür KARDEŞ, Özgen AYDINCAK, Necdet ÇEVİKER

As demonstrated in various studies, with mortality and morbidity rates reaching 90%-100%, penetrating brain injuries are among the most devastating subjects of neurosurgery. Shell and shrapnell fragments are the most common cause of this type injuries; although rarely reported in "modern times", transcranial arrow injuries may also be the cause. In this report, a 37 year-old male patient, who was shot by an "arrow" accidentally, was evaluated regarding clinical presentation, treatment and clinical progress.

**Key Words:** Arrow injuries; penetrating brain trauma; transcranial brain injuries.

Penetran kafa travmaları, çeşitli çalışmalarda gösterildiği gibi, %90-100 oranlarına ulaşan mortalite ve morbidite sonuçları nedeniyle beyin ve sinir cerrahisinin en ciddi konuları arasındadır. Genellikle kurşun ve şarapnel parçaları ile olan bu yaralanmalar, her ne kadar modern zamanlarda az görülse de "ok" ile de olabilmektedir. Bu yazıda bir kaza sonucu başından "ok" ile yaralanan, 37 yaşındaki erkek hastanın klinik bulguları, tedavisi ve klinik seyri tartışıldı.

**Anahtar Sözcükler:** Ok yaralanmaları; penetran kafa travması; transkraniyal beyin yaralanması.

Penetrating brain injuries are one of the most devastating subjects of neurosurgery because of their high mortality and morbidity rates. Estimated mortality rates were reported to be 34% and 93% in various studies and unfavorable result rates were 58% and 99%. Although the incidence of penetrating brain injury differs between series, the vast majority of the cases are mainly caused by shell and shrapnell fragments.<sup>[1]</sup> Among them arrow injuries are rarely reported events in modern times.

### CASE REPORT

We experienced an interesting case of a 37 year-old man who was shot by an arrow in an archery facility accidently. The patient was admitted to our Emergency Department with an arrow within the cranial cavity which had entered through his left parietal bone, penetrated the brain and come out of

the skull by the right part of the frontal bone (Fig.1). His initial Glasgow Coma Scale was 10. In his neurological examination he had moderate right hemiparesia and motor aphasia. The cranial computed tomography (CT) revealed the foreign body lying in the brain from left parieto-occipital region through the right frontal lobe accompanied with intraparenchymal hematoma in the parieto-occipital entry zone. There was no signs of bone displacement (Fig. 2). During the operation the inlet hole of the arrow was accepted as a reference point in order to perform the left parieto-occipital craniectomy. The subdural and intraparenchymal hematoma was evacuated with the necrotic tissue. After flattening the sharp ends of the arrow we pulled it out through the outlet hole from the frontal bone slowly. We did not perform a second craniotomy over the outlet hole. After removal of the arrow we performed an



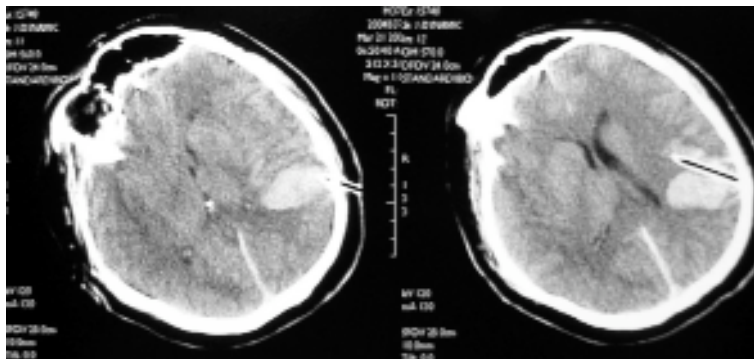
**Fig. 1.** Pre-operative photograph of the patient showing the injury type.

intraoperative CT which revealed hemoragic densities through the pathway of the arrow and the hematoma in the lateral ventricle (Fig. 3).

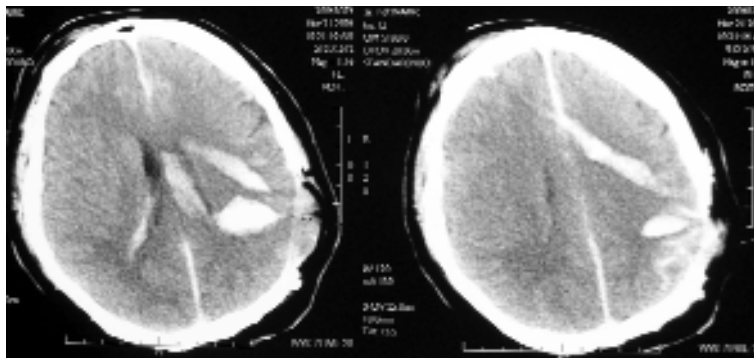
Following the hemostasis and evacuation of the residual hematoma, duraplasty was performed. The bone flap was not put back to prevent not only the

increase of intracranial pressure but also any possible complication due to infection.

He is followed up in the intensive care unit with antiepileptic, antibiotic and antiedema therapy. He improved gradually except his aphasia which has remained constant. To verify any intracranial vas-



**Fig. 2.** Pre-operative CT demonstrating the arrow and the hematoma.



**Fig. 3.** Intraoperative CT demonstrating the hemoragic densities along the arrow's pathway and the hematoma in the lateral ventricle.

cular injuries, his magnetic resonance angiography was performed and the intracranial vasculature was proven intact. He was discharged on the second week of the event with severe motor aphasia. He began to talk on the first month by using simple words with the help of an intensive speech therapy. His control cranial tomography was within normal limits except the signs of the operation and injury.

### **DISCUSSION**

The aim of this article was to describe the methods used in the management of an unexpected kind of injury that a neurosurgen would come across. Although there are famous cases like Phineas Gage (1848), transcranial injuries of the head and brain by foreign bodies other than bullet or shrapnel are extremely unusual.<sup>[2]</sup> The method we used in evaluating and treating the patient was not, infact original. Ho-

wever, it should be always kept in mind that these atypical injuries can be handeled with good results by strict conformance to general neurosurgery practice rules. This case is the proof of the flexibility of neurosurgical practice which can be applied to every situation, even in the first experience.

### **CONCLUSION**

Management of such cases are still beyond the textbooks and guidelines and it is depending on the surgeon's skill and experience in general neurosurgery.

### **REFERENCES**

1. Basil A. Prognosis in penetrating brain injury. *J Neurotrauma* 2001;51:S44-S86.
2. Stone JL. Transcranial brain injuries caused by metal rods and pipes over the past 150 years. *J Hist Neurosci* 1999;8:227-34.