

# Wrist ligaments: their significance in carpal instability

## El bileği ligamentleri: karpal instabilitedeki önemleri

Abdurrahman ÖZÇELİK<sup>1</sup>, İzge GÜNAL<sup>2</sup>, Nusret KÖSE<sup>1</sup>, Sinan SEBER<sup>1</sup>, Hakan ÖMEROĞLU<sup>1</sup>

### AMAÇ

Karpal instabiliteelerin tanı ve tedavisinde el bileğinin işlevsel bütünlüğünü kontrol etme amacıyla el bileğine destek sağlayan bağların instabilite oluşumuna kesin katkısını kavramak kritik önem taşımaktadır. Bu çalışma el bileği bağlarının işlevsel önemini araştırmayı amaçlamaktadır.

### GEREÇLER VE YÖNTEMLER

On altı yeni ölmüş insanın el bilekleri diseke edilmiştir. El bileklerinin dış ve iç bağları sırasıyla l. skafotrapeziotrapezoidum, l. radyoskafokapitatum, l. radyolunotriketrum ve l. triketrohmatokapitatum diseke edilerek instabilite kriterlerinin var olup olmadıkları araştırılmıştır. Her bağı kestikten sonra el bileği karpal kemiklerinde hatalı dizilimi, kısıtlı hareket erimi ve dorsal çevrim gibi klinik instabilite belirtileri incelenmiştir. Instabiliteden kuşulanıldığında radyografiler çekilmiş. Instabilite doğrulandığında ilgili ligament onarılarak instabilitenin iyileşip iyileşmediği kontrol edilmiştir.

### BULGULAR

Herhangi bir dorsal bağın kesisi instabiliteye neden olmasına rağmen l. skafotrapeziotrapezoidum, l. radyoskafokapitatum, l. radyolunotriketrum ve l. triketrohmatokapitatum bağlarının kesilmesi sırasıyla skafotrapeziotrapezoidal, dorsal interkalat segment, lunotriketral ve kapitohamatal instabiliteye sonuçlanmıştır. Artrozlu iki el bileğinde tüm bağların kesilmesinin herhangi bir instabiliteye yol açmadığı gözlenmiştir.

### SONUÇ

El bileği instabilitesi dört bağın başka bir deyişle l. skafotrapeziotrapezoidum, l. radyoskafokapitatum, l. radyolunotriketrum ve l. triketrohmatokapitatum bağların adına göre sınıflandırılabilir. Bu yaklaşım karpal instabiliteelerin etyoloji ve tedavisini aydınlatılabilir.

**Anahtar sözcükler:** skafotrapeziotrapezoidum ligament, radyoskafokapitatum ligament, radyolunotriketrum ligament ve triketrohmatokapitatum, el bileği instabilitesi sınıflandırması

### BACKGROUND

Understanding the exact contribution of the supporting ligaments to the functional integrity of the wrist is crucial for the diagnosis and treatment of carpal instabilities. The present study evaluates the functional significance of the wrist ligaments with respect to carpal instabilities..

**Materials and Methods:** Sixteen fresh cadaver wrists were dissected. Extrinsic and intrinsic ligaments of the wrists (ligamentum radioscaphocapitatum, ligamentum radiolunotriquetrum and ligamentum triquetrohmatocapitatum) were sectioned sequentially. After sectioning of each ligament, the wrist was examined for clinical signs of instability such as misalignment of carpal bones, limited range of motion and dorsal translation. When instability was suspected, radiographs were taken and if instability was confirmed, then the ligament was repaired.

### RESULTS

Although none of the dorsal ligaments sectioning resulted in instability, sectioning of ligamentum scaphotrapeziotrapezoideum, ligamentum radioscaphocapitatum, ligamentum radiolunotriquetrum and ligamentum triquetrohmatocapitatum displayed scaphotrapeziotrapezoidal, dorsal intercalated segment, lunotriquetral and capitolunate instability respectively. In two wrists with arthrosis, sectioning of all ligaments didn't lead to any instability

### CONCLUSION

Instability of the wrist can be classified on anatomical basis after the name of these four ligaments involved i.e. l. scaphotrapeziotrapezoideum, l. radioscaphocapitatum, l. radiolunotriquetrum and l. triquetrohmatocapitatum respectively. This approach clarifies the etiology and treatment of carpal instabilities.

**Key words:** ligamentum scaphotrapeziotrapezoideum, ligamentum radioscaphocapitatum, ligamentum radiolunotriquetrum, ligamentum triquetrohmatocapitatum, wrist instability

<sup>1</sup>Osman Gazi Üniversitesi Tıp Fakültesi  
Ortopedi Anabilim Dalı, Eskişehir,  
Turkey <sup>2</sup>Dokuz Eylül Üniversitesi  
Ortopedi Anabilim Dalı, İzmir, Turkey

<sup>1</sup> Department of Orthopaedics, Osmangazi  
University Hospital, Eskişehir, Turkey <sup>2</sup> Department of Orthopaedics, Dokuz Eylül  
University Hospital, İzmir, Turkey

Although many studies addressing carpal instabilities have been reported since the publication of Linscheid on wrist injuries in 1972,<sup>[1]</sup> there is a great deal of confusion over carpal instabilities. This, in part, may arise from the various classifications and lack of consensus as for the importance of the function of the structures involved in the carpal mechanism, as well as the precise role of intrinsic and extrinsic ligaments which support the wrist joints.<sup>[2,3]</sup>

The knowledge of functional significance of the wrist ligaments and the correlation between specific ligamentous injury and the instability would lead to a more accurate therapeutic management. A proposed classification system for carpal instability should define precisely the ligament injured and designate the instability with the name of the ligament involved as was done in ankle instabilities which turned out to be a satisfactory and practical nomenclature.<sup>[4]</sup>

To evaluate the exact contribution of the supporting ligaments to the functional integrity of the wrist we designed and conducted an experimental study using fresh cadaver specimens to demonstrate clinical instability. The radiographic changes seen on standard and stress wrist radiograms correlated with the specific ligamentous injury.

## MATERIAL AND METHODS

This study is based on observations of 16 fresh human cadaver wrists. All of them were amputated from adults of both sexes who needed forearm amputation for trauma or ischemia. Specimens with deep necrosis or wound of the wrist region and carpal fractures were excluded. The case histories were studied to exclude diseases deleterious to ligamentous integrity and plain X-rays were obtained to exclude other bony pathology. There were no wrist instability, as assessed clinically or roentgenographically in any specimens even in two wrists with arthrosis.

In 14 of 16 wrists, the ligaments were exposed using volar and dorsal approaches. Then the ligaments were sectioned sequentially as displayed in table 1. After sectioning of each ligament, the wrist was examined clinically by ballotement test of each carpal bone at the insertion of the ligament and the wrist was brought to maximum ulnar and radial deviation, flexion and extension. Additionally, Watson test was performed if the at-

**Table 1:** The sequence of ligament sectioning

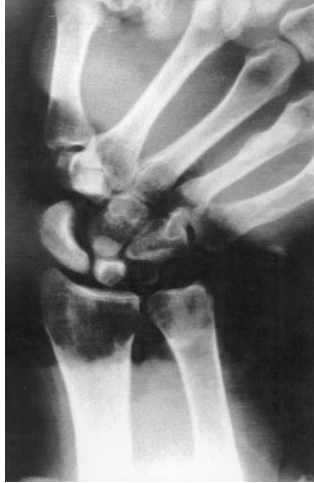|              |   |
|--------------|---|
| Dorsal       | Lig. radiocarpeum dorsale                 |
|              | Lig. intercarpeum dorsale                 |
|              | Lig. radiotriquetrale                     |
|              | Lig. triquetroscaophotrapeziotrapezoideum |
|              | Lig. scapholunate transversalis           |
|              | Lig. lunotriquetrale                      |
| Interosseous | Lig. radioscaphoideum                     |
|              | Lig. radiolunatum                         |
|              | Lig. ulnolunatum                          |
|              | Lig. ulnotriquetrum                       |
|              | Lig. scaphocapitatum                      |
|              | Lig. scapholunatum                        |
|              | Lig. scaphotrapeziotrapezoideum           |
|              | Lig. lunocapitatum                        |
|              | Lig. lunotriquetrum                       |
|              | Lig. triquetrohamatum                     |
|              | Lig. capitotrapezium                      |
|              | Lig. capitohamatum                        |
| Volar        | Lig. radioscaphocapitatum                 |
|              | Lig. pisohamatum                          |
|              | Lig. triquetrohamatocapitatum             |
|              | Lig. radiolunotriquetrum                  |

tachment of ligament was on either os scaphoideum or os lunatum or both. If instability was suspected, then posteroanterior (PA) radiographs with the wrist in neutral, ulnar and radial deviation and lateral radiographs with the wrist in neutral, flexion and extension were taken. If instability is detected radiographically, then the ligament was repaired using 4.0 silk sutures and stability was confirmed radiographically and the sectioning was continued by the sequence outlined in table 1.

In the second part of the study all dorsal and volar ligaments except for those that showed instability in the previous 14 wrists were sectioned. Then the experiment was repeated but beginning from the volar ligaments.

## RESULTS

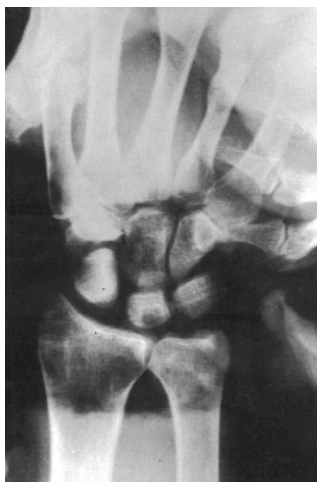No instability either clinically or radiographically, was detected with the sectioning of the dorsal carpal ligaments in all specimens. By sectioning the interosseous ligaments in 12 of the 14 wrists without arthrosis, only the section of liga-



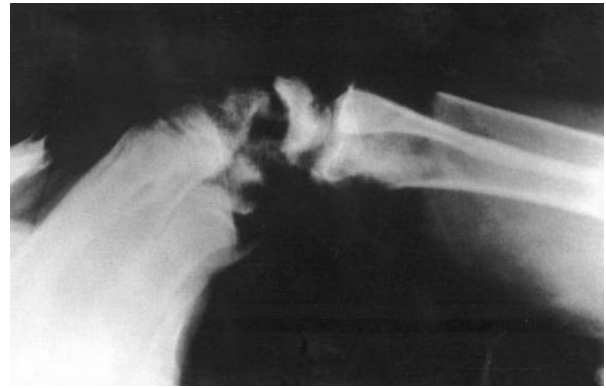**Fig. 1.** Radiograph of the wrist with increased gap between os scaphoideum, trapezium and trapezoideum after sectioning of the STT interosseous ligament on PA view.

mentum scaphotrapeziotrapezoideum (STT) resulted in instability, detected by an increased gap between os scaphoideum, trapezium and trapezoideum on ulnar deviation (Fig. 1).

Sectioning the ligamentum triquetrohamatocapitatum (THC) resulted in capitoamate (CH) dissociation. After sectioning the ligamentum radiolunotriquetrum (RLT), capitate articular surface of lunate moved volarly and volar intercalated segment instability (VISI) was seen on lateral view. It was not until the ligamentum radioscapohcapitatum (RSC) was sectioned that the change of alignment of carpal bones on movement was observed. No change was present on ulnar or radial



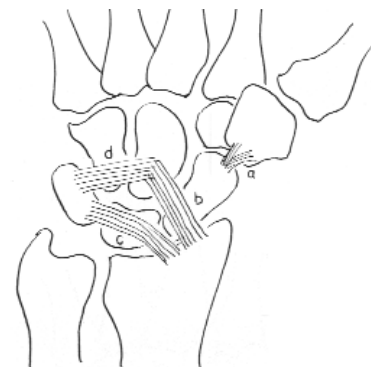
**Fig. 3.** SL gap was demonstrated on PA view after sectioning RSC ligament



**Fig. 2.** Os capitatum was subluxated on os lunatum when os capitatum was pushed dorsally after sectioning RSC ligament.

deviation but os lunatum moved dorsally and os scaphoideum showed volar flexion on dorsiflexion and scapholunate (SL) gap was increased and os capitatum was subluxated when os lunatum was forced to dorsal translation. A typical lateral radiographic view of capitolunate (CL) instability is shown (Fig. 2). While there was a dorsal intercalated segment instability (DISI) deformity on lateral view, PA radiograms demonstrated SL gap (Fig. 3). All these signs were returned to normal with the repair of the RSC ligament.

In all stages no dislocation could be created with physiological movements. In addition to sectioning of the ligaments, forceful manual loading



a) Ligamentum scaphotrapeziotrapezoideum  
b) Ligamentum radioscapohcapitatum  
c) Ligamentum radiolunotriquetrum  
d) Ligamentum triquetrohamatocapitatum

**Fig. 4.** Four ligaments which are responsible for carpal instability

was necessary to create a degree of any dislocation. In two specimens with arthrosis no instability, clinically or radiographically occurred with the sectioning of all ligaments. The effects of RSC, RLT, THC ligaments on stability could not be demonstrated on wrists with arthrosis.

In the last two specimens, after removing volar and dorsal ligaments and the capsule without disturbing the intrinsic ligaments, ligaments were sectioned and repaired sequentially. Sectioning of RSC ligament was resulted in SL and CL instability and SL ballotement and Watson tests were positive. These were confirmed on radiographic examination taken while applying force to bones. Typical CL dissociation was observed on lateral view. On ulnar deviation SL dissociation was seen. On clinical examination SL and SC ligaments were seen to be ruptured spontaneously.

After sectioning of RLT ligament, LT instability was detected clinically. This was characterized as abnormal movement on LT ballotement test. On radiographic examination VISI deformity was observed. On clinical examination LT interosseous ligament was seen to be ruptured spontaneously. THC ligament was seen as a single ligament. With the sectioning of this ligamentum triquetrohamatum, CH separation was occurred. There were abnormal movements between these joints clinically. Only after the rupture of interosseous ligaments, radiographic changes were seen on wrist radiographs in these clinical instabilities. The ligaments responsible for carpal instability are shown in figure.<sup>[4]</sup>

## DISCUSSION

Carpal bones have virtually no muscle insertions, and their movements in relation to the neighboring bones is dictated through ligaments and the relevant joint surfaces. The arrangement of the carpal bones and their ligaments is crucial to wrist stability. Ligaments are the primary stabilizers of the wrist. Idiopathic degenerative osteoarthritis of the wrist is rare. Rupture of specific ligaments may generate articular dysfunction by an abnormal distribution of forces within the wrist and also by substantial change in the intracarpal kinematics which may lead to wrist pain and progressive arthritis.<sup>[5]</sup> The specific goal of this study is a better understanding of the different types of ligament disruptions.

No instability, radiologically or clinically was detected with the sectioning of single interosseous ligaments except for STT. Rupture of these ligaments may increase the degree of instability when they accompany other ligament ruptures but they do not cause instability themselves. There are some reports which support this, especially for ligamentum radioscapholunatum (RSL).<sup>[6,7]</sup> It has been reported that in addition to RLT, RSL, RSC ligaments had the most important role in wrist stability. However, biomechanical studies demonstrated that it was the weakest ligament with 50 N distraction could rupture it.<sup>[8]</sup> Our study demonstrated that this ligament had no role in stability. Even in perilunate dislocation the presence of intact RSL proves this argument.<sup>[9]</sup> Some reports suggested that RSL ligament is a neurovascular structure which supports SL interosseous ligament.<sup>[7,8,10]</sup> The result of this study correlates well with that of Mayfield and associates regarding dorsal ligament complex.<sup>[11]</sup> They did not define any instability with the rupture of these ligaments. There are some other reports which demonstrate minimal effect of dorsal ligament complex on stability compared to volar ligaments.<sup>[12,13]</sup> Dorsal capsule is attached to the carpal bones very tightly and was difficult to dissect. It is our clinical impression that dorsal capsulo-ligamentous complex is not responsible for the stability directly but it is the final restrain to dislocation which is the last stage of the instability might play a role.

There is no clear consensus regarding the role of the interosseous ligaments in wrist instability. The SL interosseous ligament normally connects os scaphoideum and lunatum. It has been felt to be a critical structure for maintaining structural integrity within the proximal carpal row, and thus important in maintaining normal carpal mechanics.<sup>[5,14]</sup> It has been demonstrated, however, that advancing age produces degenerative tears in the central region of the SL ligament, not associated with instability patterns.<sup>[15]</sup> Additionally, contralateral communications have been demonstrated in patients with asymptomatic wrist.<sup>[16]</sup> Brunelli and associates and others have demonstrated that no SL dissociation occur with the sectioning of the SL ligament and no clinical instability could be produced as well.<sup>[17-19]</sup> In the current study no instability was detected, both clinically and radiographically, with the sectioning of all dorsal structures in addition to all intrinsic ligaments,

excluding STT instability. Additionally, we demonstrated SL dissociation with the sectioning of the RSC ligament even when all intrinsic ligaments, RLT ligament and THC ligament were left intact. We detected clinically that SL and SC ligaments were ruptured. Forceful manual loading was enough for the rupture. Except STT ligaments, rupture of intrinsic ligaments does not cause instability and clinical instability could be detected before interosseous ligaments rupture spontaneously.

In biomechanical studies SL ligament resisted 3900N but in these studies force was not applied longitudinally.<sup>[17]</sup> It is well known that intrinsic ligaments have longitudinal collagen fibrils and excessive fibrocartilage tissue especially in ligament-bone interval which make them resist excessive longitudinal forces.<sup>[20,21]</sup> This could explain the difference of findings between those studies and the current study. We apply deviation, rotation and translation forces longitudinally. The authors are not aware of any study examining the behavior of interosseous ligaments under deviation, rotation and translation forces. The fact that the interosseous ligaments resist excessive longitudinal forces does not necessarily indicate that these ligaments could not rupture easily with forces applied in a different directions. In clinical situation wrist instabilities usually developed after hyperextension and rotation forces of the wrist.<sup>[7,22]</sup>

The other point is that intrinsic ligaments are under the protection of extrinsic ligaments overlying them. SC and SL interosseous ligaments are protected by RSC, and LT interosseous ligament by RLT ligament. Interosseous ligaments could not be disrupted without rupturing overlying extrinsic ligaments. Although interosseous ligaments do not play a role in the wrist stability, STT sectioning created STT dissociation. It was the only instability produced by interosseous ligament rupture. STT ligaments do not have a defending extrinsic ligament volarly, which may explain this difference.

Mayfield described the sequential pattern of ligament failure in the wrist.<sup>[20]</sup> Progressive perilunate instability was classified into four stages. According to Mayfield perilunate instability is the preface of wrist instability, while stage I and II represented SL and CL instability respectively.<sup>[22]</sup>

In our study we demonstrated that RSC ligament sectioning produced both SL and CL instability. In the literature SL and CL instability have been described as different entities and RSC ligament rupture has been reported as a cause of both.<sup>[23-28]</sup> The terms VISI and DISI are used to define position of the lunate. DISI is the characteristic of static SL dissociation.<sup>[8,14]</sup> and CL instability is always associated with DISI.<sup>[26]</sup> RSC ligament sectioning is inevitable for DISI deformity. We think SL and CL instabilities are the same clinical case which might be named as capitolunate instability.

RLT ligament is the other structure important in wrist instability. The sectioning of the RLT ligament and loading result in LT instability and VISI deformity. Green cited 7 anatomical dissection studies addressing the ligament injuries and VISI deformities. Five of them reported that RLT ligament sectioning was necessary in order to produce VISI deformity.<sup>[29]</sup> The remaining two studies did not mention about RLT ligament sectioning while producing VISI deformity. In the current study sectioning of RLT ligament was enough to produce instability and THC ligament sectioning may increase the instability but it was not necessary as pointed out by some authors.<sup>[29]</sup>

In the literature not as triquetrohamate or CH instability has been described properly, however in the current study, sectioning THC ligaments produced these instabilities experimentally emphasizing the necessity to examine patients with mid carpal instability with this regard.

In conclusion based on our findings, and considering the reports of others, we propose that four ligaments, binding all carpal bones sequentially, excluding os pisiforme, are the primary ligaments responsible in various carpal instabilities (RSC ligament in SL and CL dissociation, RLT ligament in LT dissociation, THC ligament in CH separation and STT interosseous ligament in STT dissociation). The names of the ligaments could be used to define the instabilities. CL instability appears to us to be the same as SL instability which is caused by RSC ligament injury. Different studies reported that RSC ligament should be injured to reveal these two instabilities individually. The term of capitolunate instability should be better used to cover both instabilities.

## REFERENCES

1. Linscheid RL, Dobyns JH, Beabout JW, Bryan RS. (1972). Traumatic instability of the wrist. Diagnosis classification and pathomechanics. *J Bone Joint Surg*, 54-A: 1612-1632.
2. Garcia-Elias M. (1999). Carpal instabilities and dislocations. In: Green DP, Hotchkiss RN, Pederson WC, editors. *Green's Operative Hand Surgery*. 3rd Ed. Philadelphia: Churchill Livingstone, Vol 1, p 865-928.
3. Saffar P. (1996). Classification of carpal instabilities. In: Büchler U, editor. *Wrist Instability*. London: Martin Dunitz, p 29-33.
4. Brostrom L. (1965). Sprained ankles. 3. Clinical observations in recent ligament ruptures. *Acta Chir Scand* 130: 560-569.
5. Blevens AD, Light TR, Jablonsky WS, Smith DG, Patwardhan AG, Guay ME, Woo TS. (1989). Radiocarpal articular contact characteristics with scaphoid instability. *J Hand Surg* 14-A: 781-790
6. Berger RA, Kauer JMG. (1991). Radioscapholunate ligament: A gross anatomic and histologic study of fetal and adult wrists. *J Hand Surg* 16-A: 350-355.
7. Berger RA, Landsmeer JMF (1990). The palmar radiocarpal ligaments: A study of adult and fetal human wrist joints. *J Hand Surg* 15-A: 847-854.
8. Mayfield JK, Johnson RP, Kilcoyne RK. (1980). Carpal dislocations: pathomechanics and progressive perilunate instability. *J Hand Surg* 5-A: 226-241.
9. Herzberg G. (1996). The treatment of perilunate dislocations. In: Büchler U, editor. *Wrist Instability*. London: Martin Dunitz, p 101-105.
10. Hixson ML, Stewart C. (1990). Microvascular anatomy of the radioscapholunate ligament of the wrist. *J Hand Surg* 15-A: 279-282.
11. Mayfield J, Gilula LA, Totty WG. (1992). Static carpal ligament instabilities. In: Gilula LA, editor. *The traumatized hand and wrist*. Radiographic and anatomic correlation. Philadelphia: WB Saunders, p 315-326.
12. Green DP. (1993). Carpal dislocations and instabilities. In: Green DP, editor. *Green's Operative Hand Surgery*. 3rd Ed. New York: Churchill Livingstone, Vol. 1, p 861-928.
13. Groh GI, Lichtman DM. (1996). Is there instability of the triquetrohamate joint? In: Büchler U, editor. *Wrist Instability*. London: Martin Dunitz, p 171-173.
14. Ruby LK, An KN, Linscheid RL, Cooney WP, Chao EYS. (1987). The effect of scapholunate ligament section on scapholunate motion. *J Hand Surg* 12-A: 767-771.
15. Mikic ZD. (1978). Age changes in the triangular fibrocartilage of the wrist joint. *J Anat* 126: 367-384.
16. Berger RA, Imaeda T, Berglund L, An KN, Cooney WP, Amadio PC, Linscheid RL. (1994). The anatomic, constraint, and material properties of the scapholunate interosseous ligament: a preliminary study. In: Schuind F, An KN, Cooney WP, Garcia-Elias M, editors. *Advances in the Biomechanics of the Hand and Wrist*. New York: Plenum Press, p 9-16.
17. Brunelli GA, Brunelli GR. (1995). A new technique to correct carpal instability with scaphoid rotatory subluxation: A preliminary report. *J Hand Surg* 20-A: 82-85.
18. Mayfield JK, Johnson RP, Kilcoyne RF. (1976). The ligaments of the human wrist and their functional significance. *Anat Rec* 186: 417-428.
19. Schuh JF, Leroy B, Comtet JJ. (1985). Biodynamics of the wrist: radiologic approach to scapholunate instability. *J Hand Surg* 10-A: 1006-1008.
20. Cooper RR, Misol S. (1970). Tendon and ligament insertion: A light and electron microscopic study. *J Bone Joint Surg* 52-A: 1-20.
21. Johnston RB, Seiler JG, Miller EJ, Drvaric DM. (1995). The intrinsic and extrinsic ligaments of the wrist. A correlation of collagen typing and histologic appearance. *J Hand Surg* 20-B: 750-754.
22. Mayfield JK. (1984). Wrist ligamentous anatomy and pathogenesis of carpal instability. *Orthop Clin North Am* 15: 209-216.
23. Johnson RP, Carrera GF (1986). Chronic capitulate instability. *J Bone Joint Surg* 68-A: 1164-1176.
24. Mayfield JK. (1980). Mechanism of carpal injuries. *Clin Orthop* 149: 45-54.
25. Meade TD, Schneider LH, Cherry K. (1990). Radiographic analysis of selective ligament sectioning at the carpal scaphoid: a cadaver study. *J Hand Surg* 15-A: 855-862.
26. Horii E, Garcia-Elias M, An KN, Bishop AT, Cooney WP, Linscheid RL, Chao EYS. (1991). A kinematic study of luno-triquetral dissociations. *J Hand Surg* 16-A: 355-362.
27. Schernberg F (1996). Ulnar translocation of the carpus: A rare type of wrist instability. In: Büchler U, editor. *Wrist Instability*. London: Martin Dunitz, p 175-179.
28. Dautel G, Merle M. (1996). Diagnosis and staging of scapholunate dissociation. In: Büchler U, editor. *Wrist Instability*. London: Martin Dunitz, p 107-116.
29. Kuhlmann JN. (1996). Lunotriquetral dissociation. In: Büchler U, editor. *Wrist Instability*. London: Martin Dunitz, p 147-153.



