



Urgent endovascular treatment of iatrogenic subclavian artery rupture: report of three cases

İyatrojenik subklavyan arter yırtığında acil endovasküler tedavi: Üç olgu sunumu

Polytimi LEONARDOU, Paris PAPPAS

The increased use of central venous catheters in modern medical practice has brought a proportional increase in the number of cases of iatrogenic vascular injuries. Concerning the subclavian artery, the site of the lesion and the vessel size demand urgent and effective treatment in order to obtain a favorable prognosis. It has been common practice for a long time to consider this type of lesion as a surgical emergency. Nevertheless, emerging endovascular interventional procedures appear to offer an alternative that is effective and safe as well. We hereby report three cases of subclavian artery injury, in which repair was achieved by endovascular approach with the placement of a cover stent. Hypovolemic shock (demonstrated in two patients) as well as brachial plexus palsy due to pseudoaneurysm of the subclavian artery (presented in another patient) were successfully managed by percutaneous brachial (in two patients) or right femoral (in the patient with the pseudoaneurysm) approach and placement of balloon expandable covered stents (4-9 mm x 38 mm). No procedure-related complications were observed. Short-term follow-up results in two of the three patients were quite satisfactory concerning patency.

Key Words: Angiography; hemorrhage; stents; subclavian artery.

Modern tıbbi pratikte santral venöz kateterlerin giderek artan kullanımı iyatrojenik damar yaralanmalarının sayısında orantısız bir artışa neden olmuştur. Subklavyen arter açısından lezyonun yeri ve damarın büyüklüğü olumlu bir prognoz elde etmek için acil ve etkili tedaviyi gerektirmektedir. Uzun zamandan beri bu lezyon tipinin bir cerrahi acil olarak düşünülmesi olağan bir uygulamadır. Herşeye rağmen yeni gelişen girişimsel işlemlerin etkili ve güvenli bir alternatif sunduğu görülmektedir. Bu yazıda, bir kaplı stent yerleştirilmesiyle uygulanan endovasküler yaklaşımla onarımın gerçekleştiği üç subklavyen arter yaralanma olgusu sunuldu. İki hastada hipovolemik şok ve yine başka bir hastada görülen subklavyen arter psödoanevrizmasına bağlı brakial palsy, perkütan brakial (iki hastada) veya sağ femoral yaklaşım (psödoanevrizma olan hastada) ve genişleyebilir kaplı balon stentlerin (4-9 mm x 38 mm) yerleştirilmesiyle başarılı bir şekilde tedavi edildi. İşlemlerle ilgili herhangi bir komplikasyon gözlenmedi. Damar açıklığı açısından üç hastanın ikisinde izlem sonuçları oldukça tatminkâr idi.

Anahtar Sözcükler: Anjiyografi; kanama; stentler; subklavyen arter.

The increasing use of central venous catheters in daily hospital practice has been associated with a proportionate increase in the frequency of traumatic vascular lesions.^[1] The most serious vascular complication is arterial wall rupture, which can result in critical hemorrhage and development of pseudoaneurysm or arteriovenous fistula. The lesion becomes more common, more severe and complex when produced by large catheters such as dialysis catheters.^[2] The location of the above lesions, often requiring thoracic access, makes traditional surgical repair quite challenging. Percutaneous intravascular procedures

can alternatively offer favorable results in the urgent management of this type of lesion.

Herein, we report three cases of endovascular repair of iatrogenic subclavian artery injury associated with clinical manifestations of acute hemorrhage or brachial neuropathy.

CASE REPORTS

Case 1– Severe arterial bleeding occurred in an 82-year-old female patient during attempted right subclavian vein catheterization in order to place a hemo-

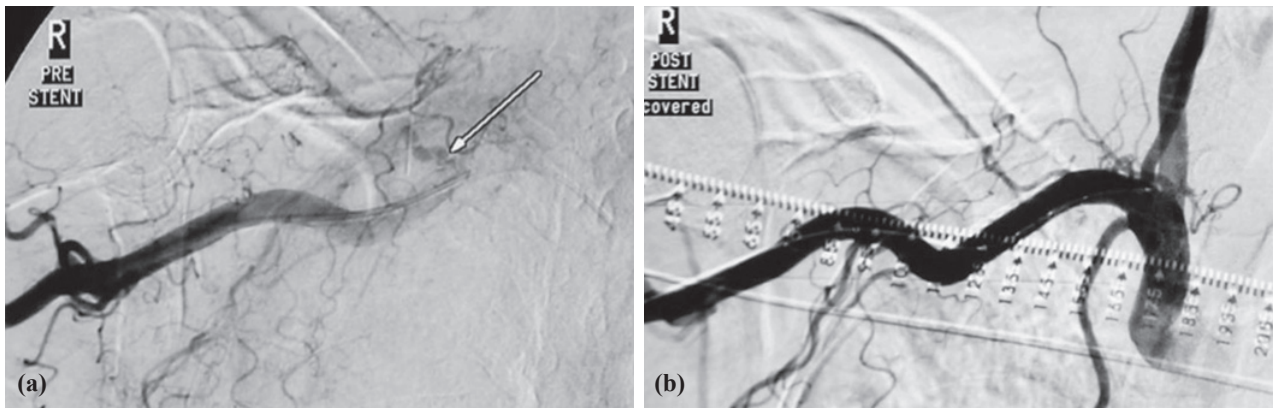


Fig. 1. (a) Contrast extravasation (arrow) in the right subclavian artery (angiography; brachial approach). (b) Sealing of the wall rupture using an intravascular endoprosthesis.

dialysis catheter. Urgent angiography was performed and demonstrated contrast extravasation in the site of the right subclavian artery. The lesion was considered to be amenable to endovascular treatment, and percutaneous balloon-expandable covered stent placement (4-9 mm x 38 mm stent mounted on a 7 mm x 40 mm angioplasty balloon catheter) was performed, through a 7F-10 cm introducer sheath placed into the right brachial artery (Fig. 1a, b). Signs of active hemorrhage subsided and the patient's condition improved rapidly.

Case 2- A 77-year-old male patient with severe acute renal failure presented abrupt reduction in arterial pressure and hematocrit level following right subclavian vein cannulation for introduction to hemodialysis. Initially, venography was performed with no significant findings, and arteriography followed via percutaneous right brachial artery approach. Contrast extravasation from the right subclavian artery was demonstrated and it was immediately repaired with endovascular placement of a covered stent (4-9 mm x 38 mm) mounted on an 8 mm x 40 mm angioplasty balloon catheter (Figs. 2a, b). Bleeding was successfully controlled; however, a few hours later the patient died, due to his general critical condition, with signs of disseminated intravascular coagulation.

Case 3- A 63-year-old male patient presented with left arm weakness and loss of tendon reflexes, numbness and hypesthesia confined to the territory of the ulnar nerve. Brachial plexus compression by a left subclavian artery pseudoaneurysm was demonstrated with color Doppler ultrasonographic examination and diagnostic angiography. A subclavian vein cannulation had been attempted unsuccessfully a few days earlier for placement of a dialysis catheter, and this was considered to be the cause of the pseudoaneurysm formation. The lesion was immediately managed with balloon-expandable stent placement (4-9 mm x 38 mm mounted on an 8 mm x 40 mm angioplasty balloon catheter) after elective left subclavian artery catheterization through a right femoral artery approach (Fig. 3a, b).

In all three cases, the covered stent placement was technically successful. No immediate or early procedure-related complication occurred. The stent used was the Jostent peripheral graft stent (Abbott) and the balloon was the "FoxCross PTA catheter" (Abbott).

DISCUSSION

Percutaneous subclavian vein catheterization has been established as a relatively safe and reliable pro-

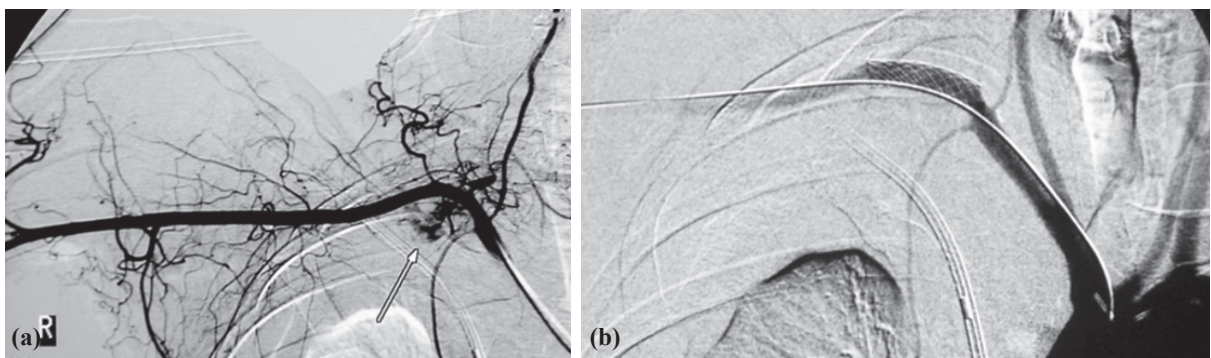


Fig. 2. (a) Right femoral approach, contrast extravasation at the site of the right subclavian artery (arrow). Bloody pleural collection (hemothorax) coexists. (b) Covered stent placement through the right brachial artery is considered to be satisfactory.

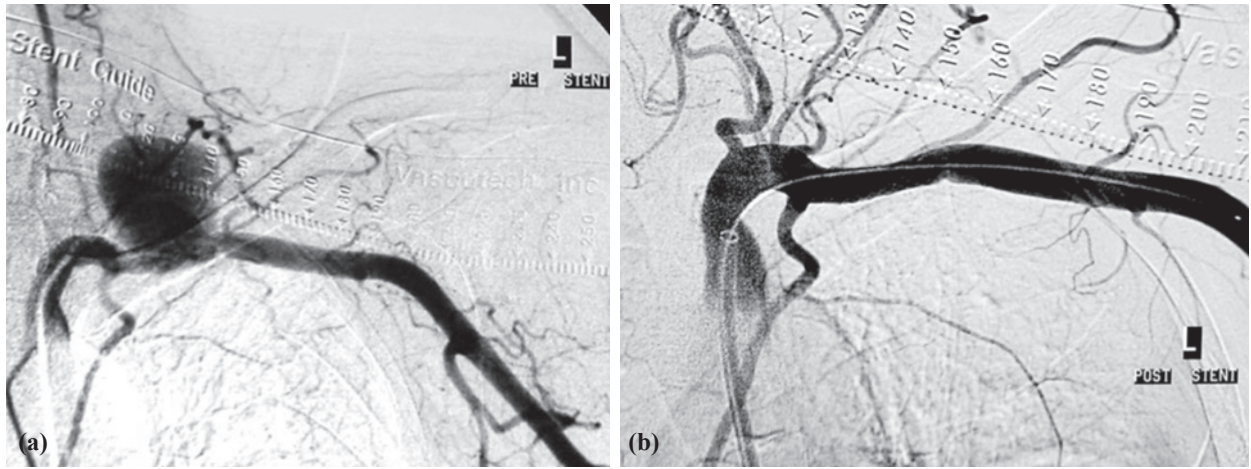


Fig. 3. (a) Left subclavian artery pseudoaneurysm (angiography; femoral approach). (b) Pseudoaneurysm exclusion using balloon expandable covered stent.

cedure for attaining immediate dialysis access, guaranteeing also drug administration or parenteral feeding.^[3] However, the use of central venous catheters is associated with a complication rate of 4-35%. Potential complications include subclavian artery injury, brachial plexus injury, pneumothorax, or hemothorax.^[4] Technical difficulties (>3 attempts), lack of experience, hypovolemia, pathological body mass index (BMI), inappropriate patient positioning, and anatomic variation or alteration due to previous operation or radiation increase the complication rate.^[5-7]

The subclavian artery is quite vulnerable; it lays posteriorly and inferiorly to the ipsilateral subclavian vein. In case of subclavian artery pseudoaneurysm formation, management should be immediate because of the inability to apply external pressure, the contiguity to vital intrathoracic structures and the potential danger of rupture.^[8-11]

Brachial plexus injury can result from compression (by an aneurysm or tumor) or from direct plexus puncture and application of local anesthesia or mechanical injury.^[12] Iatrogenic brachial plexus neuropathy has been reported rarely as a result of central venous cannulation (less than 10 cases reported), and consequently, there is not enough experience in the treatment of this type of lesion using endovascular procedure.^[9] However, application of covered endovascular endoprostheses in the subclavian artery has been more widely accepted as a reliable minimally invasive modality to exclude arteriovenous fistulas and aneurysms, facilitating a reduction in hospitalization time and blood loss and avoiding the need for general anesthesia.^[13-15]

In a recent study of du Toit et al.^[16] concerning the long-term results of stent graft treatment of subclavian artery injuries with a mean follow-up period of 49 months, significant stenosis or occlusion occurred in

eight of the 25 patients available for long-term follow-up. These patients all presented with non-incapacitating claudication, and the stenotic lesions were all treated successfully with angioplasty and remained patent on follow-up. Occlusions were treated conservatively. Structurally, the stent grafts were intact and there was no evidence of stent graft fracture or compression between the first rib and clavicle. None of the patients presented with early or late graft sepsis. In that study, it was concluded that stent graft management of selected subclavian artery injuries is safe with morbidity and mortality rates comparable with those of open surgery. The long-term results demonstrated in the study were also acceptable, and there are no published results available providing any evidence that open surgery might be better. In this unit, they therefore would consider any patient who was stable enough to undergo an angiogram as a possible candidate for stent graft treatment if a subclavian artery injury is demonstrated. Stent graft repair is now their first choice in the management of selected, stable patients with subclavian artery injuries.

A technical detail that should be emphasized is that the need to use 7F sheaths of variable length in order to introduce the vascular endoprosthesis (4-9 mm x 38 mm) through the angioplasty catheter with 8 mm - 4 cm balloon may require a closure device or surgical repair, particularly concerning the cases of brachial artery approach. The brachial artery is frequently selected as it provides a direct, shorter and less tortuous approach.

Finally, despite the urgent nature of these procedures, exclusion of arterial structures such as vertebral artery or internal thoracic artery should be cautiously avoided.

In conclusion, endovascular management of iatrogenic injury to the subclavian artery using covered

intravascular endoprosthesis seems to represent an effective alternative showing favorable initial results, as long as it is performed by experienced physicians in well-organized departments with good cooperation between interventional radiologists and surgeons.

REFERENCES

1. Thompson EC, Calver LE. Safe subclavian vein cannulation. *Am Surg* 2005;71:180-3.
2. Cantú-Martínez A, de-la-Garza-Castro O, Espinosa-Galindo AM, Cárdenas-Estrada E, de-la-Garza-Pineda O, Palacios-Ríos D, et al. Modification of the technique for subclavian-vein catheterization. *Rev Invest Clin* 2009;61:476-81.
3. Lin CH, Wu HS, Chan DC, Hsieh CB, Huang MH, Yu JC. The mechanisms of failure of totally implantable central venous access system: analysis of 73 cases with fracture of catheter. *Eur J Surg Oncol* 2010;36:100-3.
4. Guilbert MC, Elkouri S, Bracco D, Corriveau MM, Beaudoin N, Dubois MJ, et al. Arterial trauma during central venous catheter insertion: Case series, review and proposed algorithm. *J Vasc Surg* 2008;48:918-25.
5. Tan BK, Hong SW, Huang MH, Lee ST. Anatomic basis of safe percutaneous subclavian venous catheterization. *J Trauma* 2000;48:82-6.
6. Boon JM, van Schoor AN, Abrahams PH, Meiring JH, Welch T, Shanahan D. Central venous catheterization - an anatomical review of a clinical skill - Part 1: subclavian vein via the infraclavicular approach. *Clin Anat* 2007;20:602-11.
7. Ramdial P, Singh B, Moodley J, Haffejee AA. Brachial plexopathy after subclavian vein catheterization. *J Trauma* 2003;54:786-7.
8. Cayne NS, Berland TL, Rockman CB, Maldonado TS, Adelman MA, Jacobowitz GR, et al. Experience and technique for the endovascular management of iatrogenic subclavian artery injury. *Ann Vasc Surg* 2010;24:44-7.
9. Hernandez JA, Pershad A, Laufer N. Subclavian artery pseudoaneurysm successful exclusion with a covered self-expanding stent. *J Invasive Cardiol* 2002;14:278-9.
10. Kapadia S, Parakh R, Grover T, Agarwal S, Yadav A. Endovascular covered stent for management of arterial pseudoaneurysms after central venous access. *J Cardiothorac Vasc Anesth* 2007;21:99-102.
11. Basile A, Calcara G, Rapisarda F, Fatuzzo P, Desiderio C, Granata A, et al. Aberrant right subclavian artery laceration due to internal jugular vein catheterization treated by stent-graft implantation. *J Vasc Access* 2010;11:80-2.
12. Porzionato A, Montisci M, Manani G. Brachial plexus injury following subclavian vein catheterization: a case report. *J Clin Anesth* 2003;15:582-6.
13. Peynircioğlu B, Ergun O, Hazirolan T, Serter T, Uçar I, Cil B, et al. Stent-graft applications in peripheral non-atherosclerotic arterial lesions. *Diagn Interv Radiol* 2008;14:40-50.
14. Hilfiker PR, Razavi MK, Kee ST, Sze DY, Semba CP, Dake MD. Stent-graft therapy for subclavian artery aneurysms and fistulas: single-center mid-term results. *J Vasc Interv Radiol* 2000;11:578-84.
15. Abi-Jaoudeh N, Turba UC, Arslan B, Hagspiel KD, Angle JF, Schenk WG, et al. Management of subclavian arterial injuries following inadvertent arterial puncture during central venous catheter placement. *J Vasc Interv Radiol* 2009;20:396-402.
16. du Toit DF, Lambrechts AV, Stark H, Warren BL. Long-term results of stent graft treatment of subclavian artery injuries: management of choice for stable patients? *J Vasc Surg* 2008;47:739-43.