

Interesting X-ray and computed tomography images of a cervical trauma patient

Havva Kalkan, M.D.,¹ Ganime Dilek Emlik, M.D.,¹ Mesut Sivri, M.D.²

¹Department of Radiology, Necmettin Erbakan University Meram Faculty of Medicine, Konya, Turkey

²Department of Radiology, Selcuk University Faculty of Medicine, Konya, Turkey

ABSTRACT

Patients admitted to emergency departments with loss of consciousness following trauma often have cervical vertebrae fractures and spinal cord injuries with a ratio of 5–10%. Computed tomography (CT) and radiography are important for diagnosis. The aim of this study was to describe the interesting CT and radiography findings of a patient who had C3-4 dislocation and distraction that was called shearing injury. C3 and C4 were separated, but there was no fracture or major vascular injuries. Images were interesting. NEXUS and Canadian Rules were also referred to for clinical evaluation. Imaging modalities, especially reformatted CT images, make it easier to diagnose where and what the problem is.

Keywords: Cervical vertebrae; computed tomography; distraction; radiography; trauma.

INTRODUCTION

Cervical vertebrae injuries are mostly the result of motor vehicle collisions, falls, diving into shallow water, industrial accidents from backhoe loaders, and gunshot wounds to the neck. Most fatal cervical spine injuries occur in the upper cervical levels, either at the craniocervical junction, C1, or C2. Patients admitted to emergency departments with loss of consciousness following trauma often have cervical vertebrae fractures and spinal cord injuries with a ratio of 5–10%.^[1] The aim of this study was to present the findings of computed tomography (CT) and radiography of a patient who suffered an industrial backhoe loader accident. The patient had a C3–C4 separation because of hematoma. Despite these findings, there was no fracture. To the best of our knowledge, this is the first case reporting separated vertebral components without a fracture. The patient's imaging findings proved very interesting.

CASE REPORT

A 41-year-old male patient with a cervical collar was brought to our emergency department by ambulance. Following the accident, he was initially managed in a state hospital and transferred to our hospital a few hours later. According to the history given by his coworkers, a backhoe loader fell onto his body and neck. Once the emergency medical technicians in the ambulance secured the ABCs (airway, breathing, & circulation) at the scene, the patient was transferred to the nearest hospital. He was monitored, resuscitated, and intubated at the hospital. A thorax tube was placed for hemopneumothorax. Then, because of the critical care inadequacies at the state hospital, he was transferred to our university hospital. On arrival in our emergency department, the patient was unconscious. His pupils were myotic, his light reflexes were negative, and his Glasgow Coma Scale was 3. His blood pressure was 60/40 mmHg and his pulse was 30 beats per minute. He had neurogenic shock with marked hypotension, anemia, and bradycardia. As the patient was unconscious, his neurologic physical examination could not be performed by the emergency team. Therefore, he was transferred to the radiology department to have a body imaging from a lateral cervical graphy to a cervical and abdominopelvic multislice CT. There were no detected major vascular or solid organ injuries other than the hemopneumothorax.

The lateral cervical graphy revealed a craniocaudal separation between C3–C4 (Fig. 1a). A sagittal reformatted image

Address for correspondence: Havva Kalkan, M.D.
Necmettin Erbakan Üniversitesi Meram Tıp Fakültesi,
Radyoloji Anabilim Dalı, 42080 Konya, Turkey
Tel: +90 332 - 223 63 37 E-mail: drhavvaradyoloji2011@gmail.com

Qucik Response Code



Ulus Travma Acil Cerrahi Derg
2016;22(1):100–102
doi: 10.5505/tjtes.2015.49596

Copyright 2016
TJTES

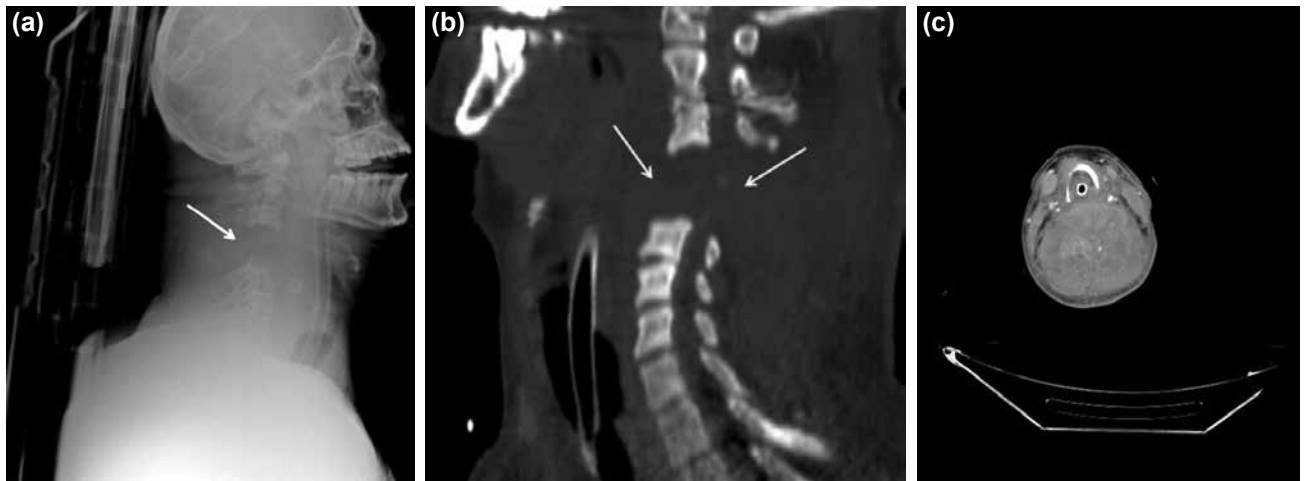


Figure 1. (a) Lateral cervical radiography reveals the distraction of C3-4 and craniocaudal displacement, separation (arrow). (b) Cervical sagittal reformat image shows distraction of C3-4 and craniocaudal displacement, widening of the space between C3 and C4 (arrows) because of the hematoma without fracture. (c) The axial CT image of the hematoma (curved arrow) between C3 and C4, and slight hyperdensities represent active extravasation from microvasculars.

(Fig. 1b) revealed the distraction and craniocaudal dislocation better than the axial CT images. The space between the separated vertebrae could also be seen. On the axial cervical CT (Fig. 1c), the hematoma between C3 and C4 was heterogeneous and contained slight hyperdensities representative of microvascular extravasations. Surgery was immediately performed on the patient by the cardiovascular team. He was thoroughly examined for vascular injuries of the neck, but there were no great vessel injuries reported by the cardiovascular surgical team.

Despite having hypotension, bradycardia was also present. The reformatted CT images and vital findings were considered to be the result of neurogenic shock resulting from a spinal cord injury. However, due to the patient's low Glasgow Coma Scale score, this could not be proved with magnetic resonance imaging (MRI). The patient did not respond to treatment with massive intravenous transfusions, steroids, dopamine, or atropine. His blood pressure and pulse failed to increase. Ultimately, the patient died following three days in neurosurgery critical care.

DISCUSSION

Emergency departments receive a lot of patients every day. It is unimportant to which group these patients belong to, they must be treated with a multidisciplinary approach for their multitraumas. Firstly, they must also be stabilized for their vital signs. They must be examined in accordance with the initial findings and provided with appropriate imaging modalities to determine the problematic locations. Most fatal cervical spine injuries occur in the upper cervical levels, either at the craniocervical junction, C1, or C2. The most common levels of cervical vertebral fractures are found at C2, C6, and C7.^[2]

In emergency departments, clinical criteria to detect the need

for imaging are determined with the NEXUS Low-Risk Criteria^[3] and the Canadian C-spine Rule.^[4] Under the NEXUS criteria, tenderness in a cervical region, focal neurologic deficits, alcohol/drug intoxication, and altered mental states are the criteria strongly suggesting a cervical spine injury examination. Even when the patients meet only one of these criteria, the patient must undergo cervical spine imaging. Our patient's major criterion for imaging was the loss of consciousness. According to the Canadian C-spine Rule, the criteria for imaging in an alert patient include: older than 65 year of age, sensory neurologic deficits, and dangerous mechanisms of injury. Our patient had a terrible accident. These two clinical risk detection rules are important in preventing unnecessary imaging ratios in emergency departments.

The first modality preference for treatment and diagnosis changes between guidelines and departments. While international guidelines^[5] support CT as the first-line imaging, the most recent Advance Trauma Life Support (ATLS) Spine and Spinal Cord Trauma guideline recommend X-ray films with targeted axial CT imaging for areas of suspected injury.^[6]

Standard X-ray films taken in emergency departments are not entirely reliable for detecting cervical spinal injuries despite careful views. Therefore, if a cervical spinal injury is strongly suspected, a CT with sagittal and coronal reformatted images permits optimal detection and evaluation of fracture-luxation. Normal findings on an X-ray film of the cervical spine do not always indicate that there are not any neck problems. This must be confirmed with CT under the high suspicion of a cervical injury. Sometimes, both modalities will reveal the pathology; X-ray reveals fracture or dislocation and CT confirms or detects any other pathologies. CT provides faster and more accurate information than radiography. In addition, contrast-enhanced CT can simultaneously give details concerning neck vascular structures and fracture assessments.

Types of spine injury include flexion, extension, rotation, and shearing.^[3] These injuries can be combined with each other according to the force direction. Our patient's images suggested that the injury mechanism was shearing because there was a dissociation between the C3 and C4 levels. Shearing injuries are caused by forces in opposite directions. These are commonly seen at the craniocervical junction. Distraction is also a component of this injury. Three types of this injury have been reported in the literature: Type 1 results from posteroanterior trauma; Type 2 is a result of a cephalad separation of the craniocervical junction; and Type 3 is caused by a force directed anteroposterior. Our patient had a C3–C4 separation suggesting a Type 2 injury as the most appropriate type according to imaging findings. According to the lateral cervical graphy and cervical CT images, this injury was reported as a shearing injury Type 2 of the C3–C4 vertebrae.

Patients who have lost consciousness after trauma for any reason must be examined especially for cervical spinal cord injuries or vertebral fractures. Imaging modalities, especially CT, have the advantage of multiplanar reformatted images, therefore, diagnosis may be easier made when compared to

single-plane CT imaging or only radiography.

Conflict of interest: There were no conflicts of interests for any authors.

REFERENCES

1. Trafton PG. Spinal cord injuries. *Surg Clin North Am* 1982;62:61–72.
2. Como JJ, Diaz JJ, Dunham CM, Chiu WC, Duane TM, Capella JM, et al. Practice management guidelines for identification of cervical spine injuries following trauma: update from the eastern association for the surgery of trauma practice management guidelines committee. *J Trauma* 2009;67:651–9.
3. Panacek EA, Mower WR, Holmes JF, Hoffman JR; NEXUS Group. Test performance of the individual NEXUS low-risk clinical screening criteria for cervical spine injury. *Ann Emerg Med* 2001;38:22–5.
4. Stiell IG, Clement CM, McKnight RD, Brison R, Schull MJ, Rowe BH, et al. The Canadian C-spine rule versus the NEXUS low-risk criteria in patients with trauma. *N Engl J Med* 2003;349:2510–8.
5. American College of Surgeons Committee on Trauma. Spine and spinal cord trauma. In: *Advanced Trauma Life Support (ATLS) Student Course Manual*, 8th edn. Chicago: American College of Surgeons 2008;157–73.
6. Munera F, Rivas LA, Nunez DB Jr, Quencer RM. Imaging evaluation of adult spinal injuries: emphasis on multidetector CT in cervical spine trauma. *Radiology* 2012;263:645–60.

OLGU SUNUMU - ÖZET

Bir servikal travma olgusunda ilginç direkt grafi ve bilgisayarlı tomografi görüntüleri

Dr. Havva Kalkan,¹ Dr. Ganime Dilek Emlik,¹ Dr. Mesut Sivri²

¹Necmettin Erbakan Üniversitesi Meram Tıp Fakültesi, Radyoloji Anabilim Dalı, Konya
²Selçuk Üniversitesi Tıp Fakültesi, Radyoloji Anabilim Dalı, Konya

Acil servise düşme veya motorlu taşıt kazası sonrası bilinç kaybıyla gelen olguların yaklaşık %5–10'unda servikal vertebra kırığı ve kord hasarlanması vardır. Tanıda görüntüleme yöntemleri özellikle bilgisayarlı tomografi (BT) ve direkt grafi önemli role sahiptir. Amacımız C3–4 dislokasyonu ve distraksiyonu olan ve shearing hasarlanma olarak adlandırılan servikal travma olgusunda ilginç BT ve direkt grafi bulgularını tanımlamaktır. C3–4 vertebra korpusları arasında hematoma nedeniyle belirgin genişleme görülmüştür fakat kırık hattı ve majör vasküler yaralanma saptanmamıştır. Görüntüler oldukça ilginçti. Ayrıca klinik değerlendirmede NEXUS ve Kanada kuralları dikkate alınmıştır. Görüntüleme yöntemleri özellikle de reformat BT görüntüleri hasarı ne olduğu ve nerede olduğunu bulmada kolaylık sağlar.

Anahtar sözcükler: Bilgisayarlı tomografi; direkt grafi; distraksiyon; servikal vertebra; travma.

Ulus Travma Acil Cerrahi Derg 2016;22(1):100–102 doi: 10.5505/tjtes.2015.49596