

Median nerve entrapment in an adolescent medial epicondyle fracture of humerus: A case report

Ömer Cengiz, M.D.

Department of Orthopedics and Traumatology, Private Muş Şifa Hospital, Muş-Türkiye

ABSTRACT

A 14-year-old boy with a displaced medial epicondyle fracture without elbow dislocation was found to have an entrapped median nerve. Entrapment of the median nerve is a potential consequence of a displaced medial epicondyle fracture, even when there are no neurologic deficits on presentation. This provides additional support for the open reduction of these fractures rather than percutaneous treatment or non-operative management. The early identification and release of an interposed median nerve are imperative to prevent the catastrophic consequences of the upper extremity nerve palsy in children, as well as to optimize fracture healing and development.

Keywords: Adolescent; medial epicondyle fracture; median nerve entrapment.

INTRODUCTION

Medial epicondyle fractures of the distal humerus account for 12% of pediatric elbow fractures, most often seen between the ages of 9 and 14, and boys are affected 4 times more than girls. Medial epicondyle fractures of the distal humerus are frequently associated with intra-articular incarceration of the fracture fragment, elbow dislocation, ulnar nerve injury, and other upper extremity fractures.^[1] Undisplaced or minimally displaced fractures are easily treated with simple immobilization. Surgical treatment is considered in case of displacement of fracture fragment into the elbow joint, suspect of the ulnar nerve entrapment and valgus instability, or >5 mm displacement of the fracture fragment. Surgical treatment includes open reduction and fixation with K-wires or screws and excision of the fracture fragment with suture reattachment of tendons and the medial collateral ligament.^[2]

Ulnar nerve injury has been well-described in pediatric elbow trauma and is most common in dislocations with medial epicondyle avulsion fractures.^[3,4] In contrast, dysfunction or incarceration of the median nerve is rarer in pediatric elbow injuries. Median nerve entrapment has been reported to oc-

cur in 3% of pediatric elbow dislocations.^[5] Median nerve entrapment has been reported in one case of displaced medial condyle fracture in a young child before medial epicondyle ossification.^[6] To the best of our knowledge, the case described, herein, is the first report of median nerve entrapment in medial epicondyle fracture in an adolescent without elbow dislocation. The aim of our study is to reveal that median nerve entrapment due to medial epicondyle fracture may develop in adolescents without elbow dislocation, although it is extremely rare.

The patient's parents provided consent after being informed about possible publication of the data concerning the case.

CASE REPORT

A 14-year-old adolescent boy initially presented to an outside emergency department with the history of falling onto his right outstretched dominant hand. The elbow was splinted, and he was sent for further examination by an orthopedic surgeon. He presented to our clinic at the same day of the injury. According to his parents and previous radiographs, there was no history of a dislocation event or signs of elbow insta-

Cite this article as: Cengiz Ö. Median nerve entrapment in an adolescent medial epicondyle fracture of humerus: A case report. *Ulus Travma Acil Cerrahi Derg* 2022;28:1200-1203.

Address for correspondence: Ömer Cengiz, M.D.

Özel Muş Şifa Hastanesi, Ortopedi ve Travmatoloji Kliniği, Muş, Türkiye

Tel: +90 436 - 212 51 51 E-mail: dr.omercengiz@gmail.com

Ulus Travma Acil Cerrahi Derg 2022;28(8):1200-1203 DOI: 10.14744/tjtes.2020.45742 Submitted: 27.09.2020 Accepted: 02.12.2020

Copyright 2022 Turkish Association of Trauma and Emergency Surgery



bility. Our case had the complaints of pain, immediate swelling, and restricted range of motion of the right elbow. The median, ulnar, and radial nerve distribution was intact in motor and sensorial examination. Elbow radiographs revealed a displaced medial epicondyle fracture without dislocation (Fig. 1a and b). At the same day, we performed a standard medial approach to the elbow with a small curvilinear incision over the palpable fracture fragment. Medial epicondyle fracture was exposed, and we immediately noted an interposed nerve in the fracture site. Initially, this was thought to be the ulnar nerve, because it appeared to enter the fracture posteromedially. The nerve was carefully extracted. However, after tracing its origin to the anteromedial aspect of the humerus rather than posterior to the medial epicondyle, we determined that this structure was the median nerve. The ulnar nerve was subsequently identified more posteriorly, verifying the anatomy and the diagnosis. Ulnar nerve was carefully dissected and decompressed to prevent possible nerve damage during the reduction of the fragment due to its proximity to the medial epicondyle. Although there was partial crushing due to fracture compression in the anteromedial part of the median nerve, the nerve integrity was intact and preserved (Fig. 2). Next, the fracture was reduced anatomically and percutaneously pinned, while the nerves were identified and protected (Fig. 3a and b). Postoperatively, the elbow was placed in 70° of flexion in a well-padded loose splint. During the immediate post-operative neurologic examination, we found a median nerve palsy, with inability to fire the index flexor digitorum profundus and flexor pollicis longus muscles; however, the flexor digitorum superficialis and flexor carpi radialis muscles were intact, and there was paresthesia in the distribution of the median nerve especially over the index and middle fingers. Ulnar and radial nerves' motor and sensation functions also were intact. A repeat examination on the post-operative 1st day found that the motor function had improved to a strength of 3 of 5, but paresthesia persisted. As a result of clinical examination and radiological evaluation (Fig. 3a and b) at the 4th week follow-up, the pins and splint were removed, and passive joint movements were started.

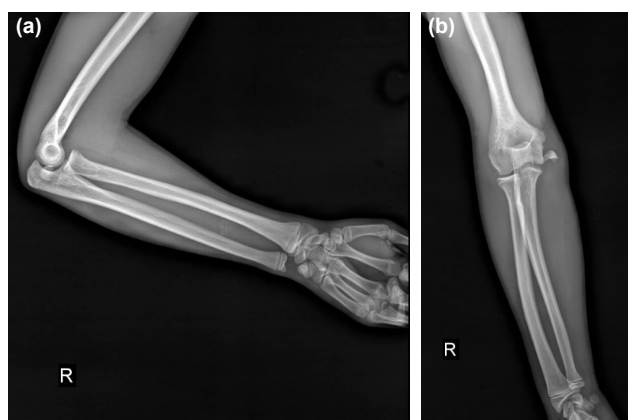


Figure 1. The displaced medial epicondyle fracture of humerus is shown on anteroposterior (a) and lateral (b) radiographs of the right elbow.

The motor function had improved to a strength of 4 of 5 with complete recovery of the sensory neuropraxia; radial and ulnar motor function remained 5 of 5. At the 6th months follow-up, the motor strength had returned to 5 of 5 (Fig. 4a-d). Fracture union was noted on radiographs (Fig. 5a and b).

DISCUSSION

Median nerve entrapment has been described previously as a rare complication of elbow dislocations and humeral medial epicondyle fractures in older children. Fourier et al.^[7] described three types of median nerve entrapment with elbow dislocation in 1977. In Type I, the child has a rupture in the medial epicondyle or tear in the adhesion of the medial

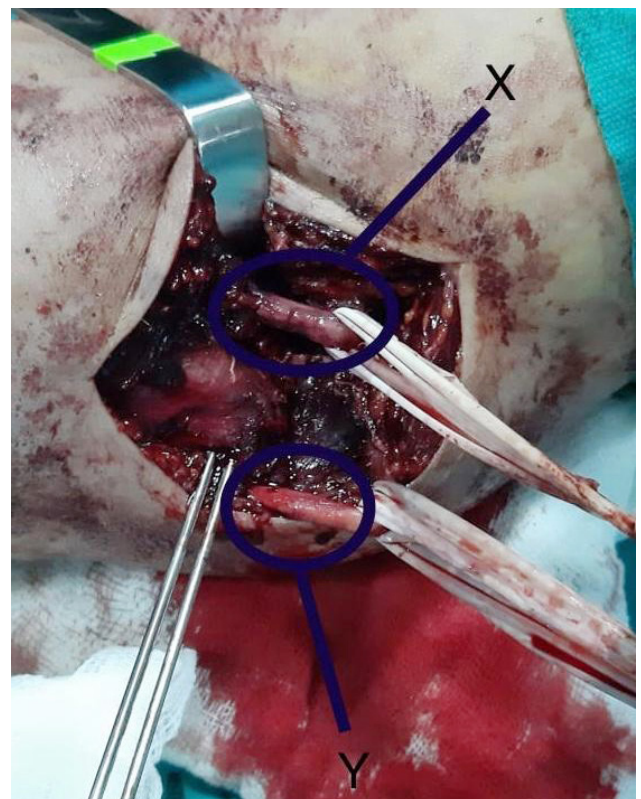


Figure 2. Intraoperative photograph. The fracture is fixed with 2 K-wires. The median nerve (X) partially crushed due to the fracture and ulnar nerve (Y) is visible posteriorly.

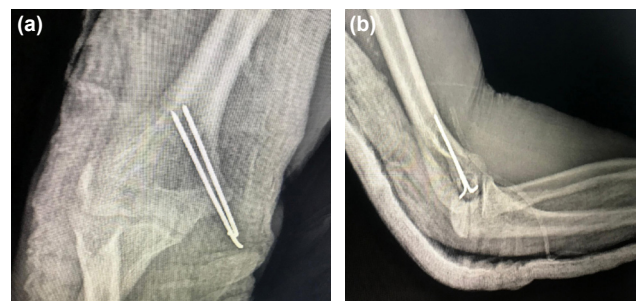


Figure 3. Post-operative anteroposterior (a) and lateral (b) radiographs show the anatomic reduction of the fracture with parallel 2 K-wires.

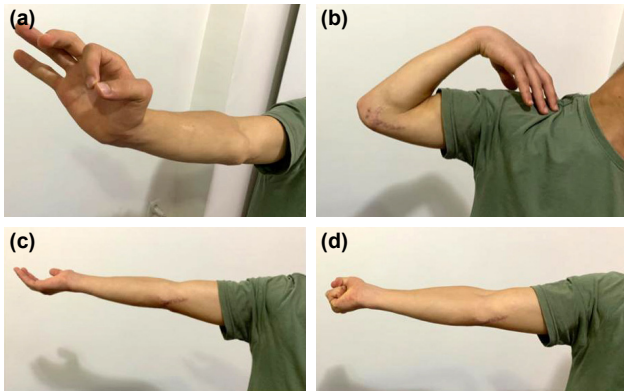


Figure 4. At the 6 months follow-up, the anterior interosseous nerve motor strength had returned to 5 of 5 and the patient fully recovered clinically (a) pinch grip of the right hand, (b) full flexion of the elbow, (c) full extension of the elbow, and (d) fully flexion of the right hand.

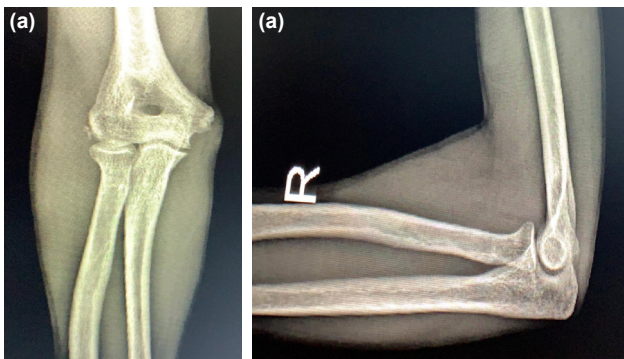


Figure 5. Complete fracture union noted on anteroposterior (a) and lateral (b) radiographs at the 6-month follow-up.

group muscles and the ulnar collateral ligament. In Type 2, the nerve is entrapped between the broken medial epicondyle and distal humerus. In Type 3, the nerve may be curled and entrapped between the distal humerus and the olecranon. Al-Qattan et al.^[8] described a Type 4 impingement in a 14-year-old boy with posterior elbow dislocation and medial epicondyle fracture. In a study by McCarthy et al.,^[6] median nerve entrapment has been reported in one case of displaced medial condyle fracture in a young child before medial epicondyle ossification. Although the ulnar nerve is usually injured in medial epicondyle fractures, the median nerve may also be compressed between the apophysis part and the distal humerus.^[1,9] In our study, it was observed that the median nerve was entrapped between the broken medial epicondyle and distal humerus as in Type 2. However, this is the first case in the literature since it occurred in adolescence without elbow dislocation.

Median nerve entrapment in a fractured medial epicondyle may occur without initial clear neurologic deficits on examination, as with our patient. Studies of median nerve entrapment after elbow dislocation or fracture dislocation have found that there is often a delay of several months in the diagnosis of median nerve damage.^[10,11] This delay may

be attributed to the difficulty of interviewing and examining younger patients or to the early attribution of findings to neuropraxia.^[10] In medial epicondyle fractures, displacement may not be fully understood due to the late onset of ossification of the medial epicondyle, thus reducing the clinician's suspicion of nerve interposition.^[10]

Ultrasound has been reported to be an effective and affordable tool to localize suspected median nerve entrapment and may be most helpful in missed cases after fracture union. Ultrasound or magnetic resonance imaging (MRI) also may be of use in pre-operative planning to assess the location of the median (or ulnar) nerve in the setting of a displaced and malrotated fracture fragment,^[12] while MRI is most useful at assessing ulnar neuropathy at the elbow due to its superficial location and is surrounded by abundant fat. This allows the nerve to be easily identified and evaluated for subtle changes in its morphology and signal intensity. Although MRI may allow evaluation of the course of the median nerve, it is less useful in evaluating patients with median neuropathy as median nerve is harder to be visualized at the elbow than ulnar nerve.^[13,14] Although there are such studies in the literature, we do not routinely apply ultrasonography and MRI for these fractures in our clinic.

Normal location of the median nerve in the elbow is best assessed with the arm in full extension, while external rotation may be helpful if medial entrapment is suspected.^[15] All attempts should be made to prevent the catastrophic consequences of missed nerve injuries in children. Consequences of delayed median nerve injury include atrophy and dysfunction of the forearm pronators, the wrist and finger flexors, and the thenar musculature, with additional sensory dysfunction. Late surgical options, including neurolysis, end-to-end anastomosis, or nerve-grafting, may regain some degree of function, but total return of function should not be expected, and late tendon transfers may be necessary.^[10,16] In 1 large retrospective review of over 1500 elbow injuries with 21 acute nerve injuries, an increased duration between nerve injury and repair was associated with a lower likelihood of recovery, with an 8% decrease with each month of delay.^[16] Complication rates are high and include joint stiffness, loss of reduction, cubitus varus, osteonecrosis, ulnar and median nerve dysfunction, and myositis ossificans. Intra-articular entrapment of the medial epicondyle, ulnar nerve dysfunction, and elbow instability is the surgical indications.^[16,17] We treated our patient surgically and observed complete clinical and radiological recovery in the 6th month follow-up. Surgeons should be aware that medial epicondyle fractures with >5 mm of displacement, as in our patient, are at risk for occult nerve entrapment.

Conclusion

To conclude, we recommend open reduction for all displaced medial condyle fractures. The substantial risk of malunion with this type of fractures justifies open treatment, and the

possibility of avoiding occult nerve entrapment or tethering with the injury or with fracture reduction supports open management. In our patient, a decompression proximally and distally made it possible to determine the entrapment of the median nerve in the fracture. This have prevented us from assuming that it was the ulnar nerve and leaving it tethered around the epicondyle. Thus, in case of encountering an interposed nerve at the time of open reduction, we also recommend decompression both proximally and distally to ensure proper identification and reduction.

Informed Consent: Written informed consent was obtained from the parents of the patient for the publication of the case report and the accompanying images.

Peer-review: Internally peer-reviewed.

Conflict of Interest: None declared.

Financial Disclosure: The authors declared that this study has received no financial support.

REFERENCES

1. Beaty JH, Kasser JR. Rockwood and Wilkins Pediatric Fractures. Rockwood CA, ed. Rockwood and Wilkins' fractures in children. Vol. 3. Philadelphia: Lippincott Williams; 2011: p. 628–42.
2. Park KB, Kwak YH. Treatment of medial epicondyle fracture without associated elbow dislocation in older children and adolescents. *Yonsei Med J* 2012;53:1190–6. [CrossRef]
3. Gottschalk HP, Eisner E, Hosalkar HS. Medial epicondyle fractures in the pediatric population. *J Am Acad Orthop Surg* 2012;20:223–32.
4. Alonzo F, Arevalo M, Cahueque M. A rare case of elbow dislocation with medial epicondyle fracture associated to ulnar neuropraxia. *J Surg Case Rep* 2017;20:rjx198. [CrossRef]
5. Ogden JA. *Skeletal Injury in the Child*. New York: Springer; 2000.
6. McCarthy CE, Kyriakides JC, Mistovich RJ. Type-V median nerve entrapment in a pediatric medial condyle fracture: A case report. *JBJS Case Connect* 2018;8:e108. [CrossRef]
7. Fourier P, Levai JP, Collin JP. Incarceration du nerf median au cours au cours d'une luxation du coude. *Rev Chir Orthop* 1977;63:13–6.
8. Al-Qattan MM, Zuker RM, Weinberg MJ. Type 4 median nerve entrapment after elbow dislocation. *J Hand Surg Br* 1994;19:613–5. [CrossRef]
9. Papatandrea R, Waters PM. Posttraumatic reconstruction of the elbow in the pediatric patient. *Clin Orthop Relat Res* 2000;370:115–26. [CrossRef]
10. Noonan KJ, Blair WF. Chronic median-nerve entrapment after posterior fracture dislocation of the elbow. A case report. *J Bone Joint Surg Am* 1995;77:1572–5. [CrossRef]
11. Hallett J. Entrapment of the median nerve after dislocation of the elbow. A case report. *J Bone Joint Surg Br* 1981;63 B:408–12. [CrossRef]
12. Dubev V, Saify A, Samant A, Shahane S. Median nerve entrapment after elbow dislocation and the role of ultrasonography-a case report. *J Orthop Case Rep* 2017;7:21–4.
13. Kijowski R, Tuite M, Sanford M. Magnetic resonance imaging of the elbow. Part II: Abnormalities of the ligaments, tendons, and the nerves. *Skeletal Radiol* 2005;34:1–18. [CrossRef]
14. Akansel G, Dalbayrak S, Yilmaz M, Bekler H, Arslan A. MRI demonstration of intra-articular median nerve entrapment after elbow dislocation. *Skeletal Radiol* 2003;32:537–41. [CrossRef]
15. Martinoli C, Bianchi S, Giovagnorio F, Pugliese F. Ultrasound of the elbow. *Skeletal Radiol* 2001;30:605–14. [CrossRef]
16. Galbraith KA, McCullough CJ. Acute nerve injury as a complication of closed fractures or dislocations of the elbow. *Injury* 1979;11:159–64.
17. Tarallo, L, Mugnai R, Fiacchi F, Adani R, Zambianchi F, Catani F. Paediatric medial epicondyle fractures with intra-articular elbow incarceration. *J Orthop Traumatol* 2015;16:117–23. [CrossRef]

OLGU SUNUMU - ÖZ

Adölesan medial epikondil kırığı sonrası gelişen median sinir tuzaklanması: Bir olgu sunumu

Dr. Ömer Cengiz

Özel Muş Şifa Hastanesi, Ortopedi ve Travmatoloji Kliniği, Muş

On dört yaşında bir erkek çocukta dirsek çıkığı olmaksızın deplase medial epikondil kırığına bağlı median sinir tuzaklanması tespit edildi. Median sinirin tuzaklanması, sunumda nörolojik defisit olmasa bile, yer değiştirmiş medial epikondil kırığının potansiyel bir sonucudur. Bu durum, perkütan tedavi veya nonoperatif tedavi yerine, bu tip kırıkların açık redüksiyonu için gerekçe sağlamaktadır. Tuzaklanan bir median sinirin erken tanımlanması ve tedavisi, çocuklarda üst ekstremité sinir felcinin katastrofik sonuçlarını önlemek ve kırık iyileşmesini ve gelişimini optimize etmek için zorunludur.

Anahtar sözcükler: Adölesan; medial epikondil kırığı; median sinir tuzaklanması.

Ulus Travma Acil Cerrahi Derg 2022;28(8):1200-1203 doi: 10.14744/tjtes.2020.45742