

# Protective effect of osthole on testicular ischemia/reperfusion injury in rats

Osman Hakan Kocaman, M.D.,<sup>1</sup> Tansel Günendi, M.D.,<sup>1</sup> Mustafa Erman Dörterler, M.D.,<sup>1</sup>  
İsmail Koyuncu, M.D.,<sup>2</sup> Hakim Celik, M.D.,<sup>3</sup> Nihat Yumusak, M.D.,<sup>4</sup> Mehmet Emin Boleken, M.D.<sup>1</sup>

<sup>1</sup>Department of Pediatric Surgery, Harran University Faculty of Medicine, Şanlıurfa-Turkey

<sup>2</sup>Department of Medical Biochemistry, Harran University Faculty of Medicine, Şanlıurfa-Turkey

<sup>3</sup>Department of Physiology, Harran University Faculty of Medicine, Şanlıurfa-Turkey

<sup>4</sup>Department of Pathology, Harran University Faculty of Veterinary Medicine, Şanlıurfa-Turkey

## ABSTRACT

**BACKGROUND:** Testicular torsion is a urological emergency that requires urgent surgical intervention which results in testicular loss if not diagnosed and treated in a timely fashion. Ischemic tissue damage with oxygen deficiency, which starts with the decrease in blood flow to the tissue, continues to increase with the reoxygenation of the damaged tissues as soon as reperfusion is achieved. In various studies, osthole has also been shown to reduce cerebral, spinal cord, intestinal, renal, and myocardial ischemia/perfusion (I/R) damage. The aim of this study is to examine the effects of osthole on testicular I/R injury.

**METHODS:** 28 Wistar-albino rats were randomly divided into four experimental groups (n=7). Group 1 was the sham operation group. In Group 2 (I/R), 3-h ischemia was created by rotating the testis 720° clockwise, followed by 3 h of reperfusion. In Group 3 (I/R + single dose of Osthole), 20 mg/kg ostol was administered intraperitoneally half an hour before detorsion after 3 h of torsion. The testis was detorsioned. Three h of detorsion was applied. In Group 4 (I/R + twice doses of Osthole), 20 mg/kg ostol was administered intraperitoneally half an hour before detorsion, followed by 3-h torsion. The testis was released and detorsioned. Half an hour after the detorsion, an intraperitoneal dose of 20 mg/kg osthole was administered again. Detorsion was done for 3 h. All rats were sacrificed after 6 h and right orchietomy was performed for blood for biochemical analysis and histopathological sample.

**RESULTS:** Glutathion, nuclear respiratory factor 2, Superoxide dismutase, and 8-hydroxydeoxyguanosine levels were decreased in I/R rats, while interleukin-6, malondialdehyde, and myeloperoxidase levels were increased. While caspase 3, caspase 8, caspase 9, and TUNEL showed moderate immunopositive tissues immunohistochemically in rats with I/R damage, mild immunopositive tissues were detected in Group 3 and Group 4. In the histochemical examination, degenerative tubule structure and separation of epithelial cells were observed in I/R rats, while partially healed testicular tissue was detected in Group 3 and Group 4.

**CONCLUSION:** In our study, we observed that osthole reduced oxidative damage, suppressed the inflammatory process, prevented apoptosis, and reduced cell damage. We think that with repeated doses, cellular damage would gradually decline.

**Keywords:** Antioxidant; apoptosis; caspase; osthole; testicular torsion.

## INTRODUCTION

Testicular torsion (TT) is a urological emergency that requires urgent surgical intervention which results in testicular loss if not diagnosed and treated in a timely fashion. To protect testicular functions, the testis should be detorsioned

by surgical means and reperfusion should be provided at an appropriate time interval. When TT is treated within the first 6 h of onset, there is a good chance that the affected testicle would be revived as high as 90% to 100% success rate. If treated within 6–12 h, 20–50% of these testicles would be saved and within a 12–24 h intervention interval, only 0–10%

Cite this article as: Kocaman OH, Günendi T, Dörterler ME, Koyuncu İ, Celik H, Yumusak N, et al. Protective effect of osthole on testicular ischemia/reperfusion injury in rats. *Ulus Travma Acil Cerrahi Derg* 2022;28:563-569.

Address for correspondence: Osman Hakan Kocaman, M.D.

Harran Üniversitesi Tıp Fakültesi, Çocuk Cerrahisi Anabilim Dalı, Şanlıurfa, Turkey

Tel: +90 414 - 344 44 44 E-mail: drhakankocaman@yahoo.com

*Ulus Travma Acil Cerrahi Derg* 2022;28(5):563-569 DOI: 10.14744/tjtes.2021.43333 Submitted: 11.07.2021 Accepted: 25.09.2021

Copyright 2022 Turkish Association of Trauma and Emergency Surgery



of testicles could be salvaged according to the literature.<sup>[1]</sup> Ischemic tissue damage with oxygen deficiency, which starts with the decrease in blood flow to the tissue, continues to increase with the reoxygenation of the damaged tissues as soon as reperfusion is achieved. Although reperfusion is essential for the survival of testicular cells and tissues, it is through the production of reactive oxygen species (ROS) and reactive nitrogen species that induce the sequence of events which cause testicular ischemia/reperfusion (I/R) damage.<sup>[2]</sup>

Osthole (7-methoxy-8-isopentenoxycoumarin) is a natural coumarin derivative isolated from various plants such as *Cnidium monnieri*, *Angelica pubescens*, and *Peucedanum ostruthium*.<sup>[3]</sup> In various studies, osthole has been reported to be effective on decreasing antitumor, antiosteoporotic, anti-inflammatory, anti-allergic, antiseizure, and antidiabetic I/R damage.<sup>[4]</sup> It has also been shown to reduce cerebral, spinal cord, intestinal, renal and myocardial I/R damage; however, to the best of our knowledge in English literature, no study has been conducted on testicular I/R damage.<sup>[3-7]</sup> The aim of this study is to examine the effects of osthole on testicular I/R injury.

## MATERIALS AND METHODS

### Animals

Animal experiments were approved by the Local Ethics Committee of Harran University (2017/001 01-05). Twenty-eight male Wistar-albino rats (350–450 g) were provided by the Harran University Animal Experiment Research Center. Animals were kept at 20–22°C with a 12 h light/dark cycle. Standard animal feed and water were given.

### Experiment Design

A total of four groups were formed with seven rats in each group. All rats were prepped and draped in sterile conditions and were administered intraperitoneal ketamine 60 mg/kg (Ketalar®, Pfizer, Turkey) and xylazine HCl 10 mg/kg for general anesthesia. Group 1 (sham operation group): A right scrotal incision was made, the tunica vaginalis was opened, and the right testis was removed outside the incision. Orchiectomy was performed after 4 h without any procedure. Group 2 (I/R group): A right scrotal incision was made, the tunica vaginalis was opened, and the right testis was removed outside the incision. The gubernaculum was excised and the testis was fixed to the scrotum by rotating it clockwise 720°. After 3 h of torsion, the testis was released and detorsion was performed. After 3 h of detorsion, blood and histopathological sample was obtained and right orchiectomy were performed for biochemical analysis. Group 3 (I/R + pre-operative osthole): A right scrotal incision was made, the tunica vaginalis was opened, and the right testis was removed outside the incision. The gubernaculum was excised and the testis was fixed to the scrotum by rotating it clockwise 720°. Following 3 h of torsion, an intraperitoneal dose of 20 mg/kg osthole was administered half an hour before

detorsion. The testis was released and detorsion was implemented. After 3 h of detorsion, blood and histopathological sample was obtained and right orchiectomy were performed for biochemical analysis. Group 4 (I/R + pre-operative and post-operative osthole): A right scrotal incision was made, the tunica vaginalis was opened, and the right testis was removed outside the incision. The gubernaculum was excised and the testis was fixed to the scrotum by rotating it clockwise 720°. Following 3 h of torsion, an intraperitoneal dose of 20 mg/kg osthole was administered half an hour before detorsion. The testis was released and detorsion was carried out. Half an hour after detorsion, an additional intraperitoneal dose of 20 mg/kg osthole was administered once again. After 3 h of detorsion, blood and histopathological sample was obtained and right orchiectomy was performed for biochemical analysis.

## Biochemical Analysis

### Enzyme-Linked Immunosorbent Assay (ELISA)

Interleukin (IL)-6, nuclear factor, erythroid derived-2 like-2 (NFE2L2 or NRF-2), 8-hydroxydeoxyguanosine (8-OHdG), and myeloperoxidase (MPO) (Fine Test, Wuhan, China) ELISA was performed using the kit protocol. The samples to be studied in serum were brought to room temperature at least 2 h before the protocol. Before the samples were added to the 96-well plate, they were washed and an amount of 100 µl standard/sample was added and incubated at 37°C for 90 min. Samples were removed, 100 µl biotinylated detection antibody was then poured in and incubated for 60 min. After washing, 100 µl of SABC working solution horseradish peroxidase was put in to all wells. Following 30 min of incubation, 90 µl of TMB substrate was supplemented and when a visible color change was observed, stop solution (50 µl) was subjoined, and a yellow color formation was visualized. Optical density value was determined at 450 nm (OD450 nm) and the data were evaluated.

### Glutathion (GSH Assay)

GSH level was assessed through reaction with (1 mg/ml o-phthalaldehyde in methanol) following to the modified technique of Koyuncu et al.<sup>[8]</sup> GSH was used as a standard. GSH samples were assessed through microplate reader (Spectra max M5, USA), with excitation at 345 nm and emission at 425 nm. Results were expressed as nmol/ml and nmol/g in serum and in wet tissue, respectively.

Malondialdehyde (MDA) levels in the serum were assessed following the technique defined by Ohkawa et al.<sup>[9]</sup> ELISA plates were read by a microplate reader (Spectra max M5), at 532 nm. The results were obtained as nmol/ml in serum.

Superoxide dismutase (SOD) is an important antioxidant defense in nearly all cells exposed to oxygen. The SOD level was determined using SOD assay kit (Cayman Chemical Company, Ann Arbor, MI, USA).

## Histopathological Examination

The tissue samples were fixed in buffered neutral 10% formaldehyde for histopathological examination and embedded in paraffin blocks after standard tissue processing, and 4- $\mu$ m-thick sections were cut from each of the blocks and stained with Hematoxylin–Eosin (HE). Tissue analysis was performed using an Olympus system for image acquisition and analysis, respectively, an Olympus BX-53 microscope (Olympus, Tokyo, Japan) equipped with Olympus Cell B software. Histopathological changes were evaluated semiquantitatively corresponding to 0: None, 1: Mild, 2: Moderate, and 3: Severe.

## Immunohistochemical Procedures

Immunohistochemical staining procedures were performed according to the specified method indicated by Yumuşak ve ark. The paraffin-embedded tissue blocks were cut in 4- $\mu$ m thick sections on poly-L-lysine-coated glass slides for the immunohistochemical studies. They were stained with the streptavidin–biotin–peroxidase complex (ABC) technique after routine deparaffinization and rehydration procedures (Histostain Plus Kit; Zymed, South San Francisco, California, USA). In all stainings, caspase 3 (1: 200, PA5-16335; Invitrogen, California, USA), caspase 8 (1: 50, ab4052; Abcam, Cambridge, USA), and caspase 9 (1: 100, ab52298; Abcam, Cambridge, USA) were used as primer antibodies. The diaminobenzidine (DAB; Dako) was used as the chromogen. Cytoplasmic staining was scored as 0, 1, 2, or 3 corresponding to the presence of negative, weak, intermediate, and strong brown staining, respectively. All staining steps were carried out in humidity cabinets at 37°C. PBS solution was used as a wash-away solution during all the staining steps.

Terminal deoxynucleotidyl transferase mediated deoxyuridine triphosphate nick end labeling (TUNEL) assay procedures.

The TUNEL assay method was applied according to the catalog procedure (In situ Cell Death Detection Kit, POD; Roche, Mannheim, Germany) to determine apoptosis-related DNA breaks in liver, kidney, and testes cells. According to the specified method indicated, Yumuşak ve ark (2018) was applied to all procedures in the tissues. Finally, staining indexes were calculated as follows on the basis of the percentages of the stained nuclei for these three markers; negative: 0 (<1% positive); weak: 1 (1–25% positive); intermediate: 2 (>25–75% positive); and strong: 3 (>75% positive).

## Statistical Analysis

Statistical analysis of the data was performed using the Statistical Package for the Social Sciences (SPSS for Windows; version 22.0) package program. The suitability of the variables to normal distribution was examined using visual (histogram and probability graphs) and analytical methods (Kolmogorov–Smirnov/Shapiro–Wilk tests). Descriptive analyses were

given as mean $\pm$ standard error for normally distributed variables. Since all relevant data showed normal distribution, these were evaluated with one-way analysis of variance test. The homogeneity of variances was determined by Levene's test. In results which the p-value was calculated,  $p < 0.05$  was evaluated as statistically significant. In cases of a statistically significant difference between groups, these were compared with the *post hoc* Duncan test.

## RESULTS

The experimental study was well tolerated in all groups. No rat deaths were encountered.

### Biochemical Results

In the biochemical analysis of rat serum, 8-OH-Dehydrogenase was found to have a mean value of  $1.65 \pm 0.02$  mg/ml in Group 1,  $3.26 \pm 0.12$  mg/ml in Group 2,  $1.99 \pm 0.12$  in Group 3, and  $1.86 \pm 0.08$  mg/ml in Group 4. Intergroup serum 8OH-Dehydrogenase compared values; while the difference was determined between Group 3 versus Group 1 and Group 2 ( $p < 0.05$ ), no statistical difference was found between Group 4 versus Group 1 and 3 ( $p > 0.05$ ). While the difference was determined between Group 2 and Group 4 ( $p < 0.05$ ), there was no statistical difference between Group 3 and Group 1 ( $p > 0.05$ ). A statistical difference was observed between Group 1, Group 2, and Group 3 ( $p < 0.05$ ). There was a marked statistical difference between Group 2 versus other groups ( $p < 0.05$ ) (Table 1).

The mean GSH was  $18.93 \pm 1.11$  mg/ml in Group 1,  $9.65 \pm 0.55$  mg/ml in Group 2,  $12.27 \pm 0.67$  mg/ml in Group 3, and  $16.57 \pm 1.07$  mg/ml in Group 4. Serum GSH value between groups; while a difference was determined between Group 3 and Group 1, Group 2 and Group 4 ( $p < 0.05$ ), a difference was also determined between Group 4 and Group 1, Group 2 and group 3 ( $p < 0.05$ ) (Table 1).

The mean IL-6 level was  $200.57 \pm 9.12$  mg/ml in Group 1,  $353.71 \pm 24.81$  mg/ml in Group 2,  $241.57 \pm 10.73$  mg/ml in Group 3, and  $218.0 \pm 5.84$  mg/ml in Group 4. Intergroup serum IL-6 value; while a difference was determined between Group 2 and Group 3 ( $p < 0.05$ ), no difference was found between Group 4 and Group 1 and 3 ( $p > 0.05$ ). While a difference was determined between Group 4 and Group 2 ( $p < 0.05$ ), no difference was found between Group 3 and Group 1 ( $p > 0.05$ ). There was no difference between Group 1 and Group 4 ( $p > 0.05$ ). A difference was observed in Group 4 versus Group 1, Group 2, and Group 3 ( $p < 0.05$ ) (Table 1).

The mean MDA level was  $14.16 \pm 0.81$  mg/ml in Group 1,  $22.85 \pm 0.75$  mg/ml in Group 2,  $17.85 \pm 0.78$  mg/ml in Group 3, and  $17.19 \pm 0.54$  mg/ml in Group 4. Serum MDA value between groups; while a difference was determined between

**Table 1.** Comparison of serum values of the groups

Serum	N	8-OHdG	GSH	IL-6	MDA	MPO	NRF2	SOD
Groups		Mean±SD	Mean±SD	Mean±SD	Mean±SD	Mean±SD	Mean±SD	Mean±SD
Group 1	7	1.65±0.02 <sup>a</sup>	18.93±1.11 <sup>c</sup>	200.57±9.12 <sup>a</sup>	14.16±0.81 <sup>a</sup>	1.33±0.07 <sup>a</sup>	10.04±0.36 <sup>c</sup>	5.36±0.29 <sup>d</sup>
Group 2	7	3.26±0.12 <sup>c</sup>	9.65±0.55 <sup>a</sup>	353.71±24.81 <sup>c</sup>	22.85±0.75 <sup>c</sup>	2.78±1.18 <sup>c</sup>	6.33±0.57 <sup>a</sup>	2.03±0.15 <sup>a</sup>
Group 3	7	1.99±0.12 <sup>b</sup>	12.27±0.67 <sup>b</sup>	241.57±10.73 <sup>b</sup>	17.85±0.78 <sup>b</sup>	1.93±0.12 <sup>b</sup>	7.28±0.45 <sup>ab</sup>	3.03±0.16 <sup>b</sup>
Group 4	7	1.86±0.08 <sup>ab</sup>	16.57±1.07 <sup>c</sup>	218.0±5.84 <sup>ab</sup>	17.19±0.54 <sup>b</sup>	1.66±0.04 <sup>ab</sup>	8.27±0.4 <sup>b</sup>	4.18±0.3 <sup>c</sup>
P value (one way ANOVA)		p=0.000 <sup>***</sup>	p=0.000 <sup>***</sup>	p=0.000 <sup>***</sup>	p=0.000 <sup>***</sup>	p=0.000 <sup>***</sup>	p=0.000 <sup>***</sup>	p=0.000 <sup>***</sup>

GSH: Glutathion; IL: Interleukin; MDA: Malondialdehyde; SOD: Superoxide dismutase; NRF: Nuclear factor; Etythroid derived-2 like-2; 8-OHdG: 8-hydroxydeoxyguanosine; MPO: Myeloperoxidase; ANOVA: Analysis of variance.

Group 3 and Group 1, Group 2 and Group 4 ( $p<0.05$ ), a difference was also determined in Group 4 versus Group 1, Group 2, and Group 3 ( $p<0.05$ ) (Table 1).

Mean MPO levels were 1.33±0.07 mg/ml in Group 1, 2.78±1.18 mg/ml in Group 2, 1.93±0.12 mg/ml in Group 3, and 1.66±0.04 mg/ml in Group 4. Intergroup serum IL-6 value; while a difference was determined between Groups 1, 2, and 3 ( $p<0.05$ ), no difference was found in Group 4 ( $p>0.05$ ). A statistical difference was determined between Group 4 and Group 2 ( $p<0.05$ ) and no difference was found between Group 3 and Group 1 ( $p>0.05$ ). There was a difference between Group 1 and Group 2 and Group 3 ( $p<0.05$ ). There was no difference between Group 1 and Group 4 ( $p>0.05$ ). A difference was observed between Group 2 and Group 1, Group 3 and Group 4 ( $p<0.05$ ) (Table 1).

The mean NRF-2 levels were 10.04±0.36 mg/ml in Group 1, 6.33±0.57 mg/ml in Group 2, 7.28±0.45 mg/ml in Group 3, and 8.27±0.4 mg/ml in Group 4. Intergroup serum NRF-2; while a difference was determined between Group 4 and Group 1 and Group 2 ( $p<0.05$ ), no difference was found between Group 3 ( $p>0.05$ ) (Table 1).

Mean SOD values were 5.36±0.29 mg/ml in Group 1, 2.03±0.15 mg/ml in Group 2, 3.03±0.16 mg/ml in Group 3, and 4.18±0.3 mg/ml in Group 4. There was a significant difference between all groups ( $p<0.05$ ) (Table 1).

## Histopathological Examination

In histochemical examination with HE, it was observed that the testicular tissue in Group 1 had a normal structure characterized by the presence of transverse sections of seminiferous tubules, Leydig cells, and tubule basal lamina. While moderate staining was observed in Group 2, mild staining was observed in Groups 3 and 4 (Table 2 and Fig. 1).

## Immunohistochemical Examination

It was observed immunohistochemically immunonegative tissues in Group 1 with caspase 3, caspase 8, caspase 9, and TUNELL. Moderate immunopositive tissues were detected in Group 2 and mild immunopositive tissues were detected in Group 3 and Group 4 (Fig. 2).

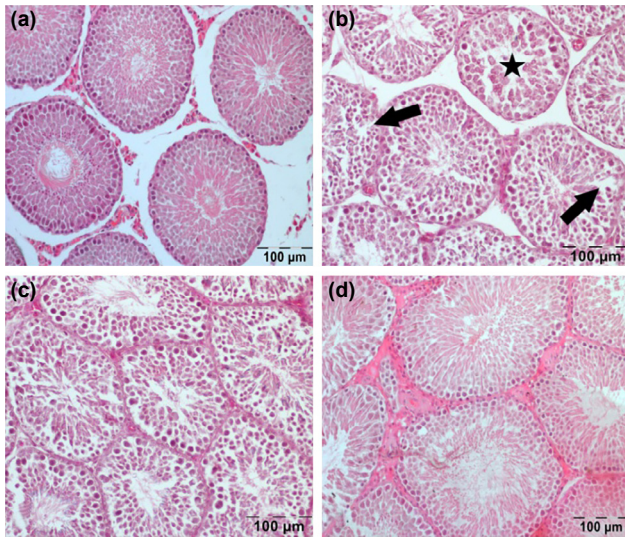
## DISCUSSION

It has been reported that even if TT is corrected within 4 h, as

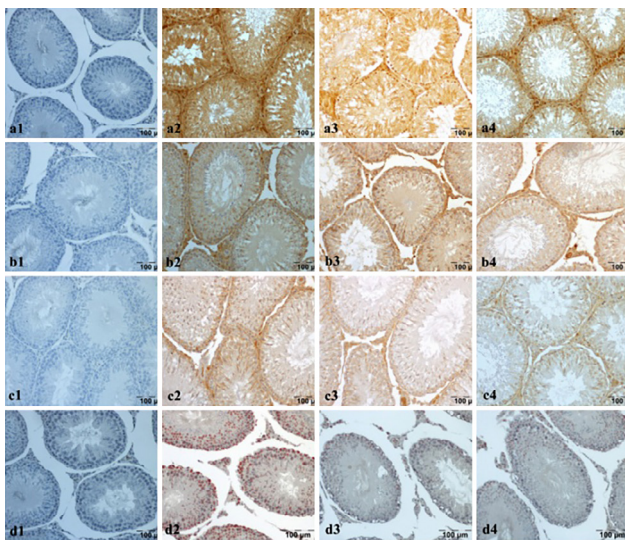
**Table 2.** Histopathological and immunohistochemical findings in groups

Variables	Group 1	Group 2	Group 3	Group 4
Absent of germ cells	–	++	+	+
Degenerated testis tubules	–	++	+	+
Germinal cells separation	–	++	+	–
Vacuolation germ cells	–	++	+	+
Disorganized germ cells	–	++	+	+
Cas-3	–	++	+	–
Cas-8	–	++	+	+
Cas-9	–	++	+	+
TUNEL	–	++	++	+

(-): No lesion, (+): Mild lesions, (++) : Moderate lesions, (+++) : Severe lesions. \*The intensity of staining was scored as – (<1% positive), + (1–25% positive), ++ (>25–75% positive), +++ (>75% positive) according to the percentage of positive staining cells.



**Figure 1.** Histopathological findings. **(a)** Group 1) normal testicular structure. **(b)** Group 2) star shows degenerative tubule whereas arrows show detachment in epithelial cells. **(c)** Group 3, **(d)** Group 4) partially healed testicular tissue.



**Figure 2.** Immunohistochemical stainings **(a)** Caspase 3 staining, **(b)** Caspase 8 staining, **(c)** Caspase 9 staining, **(d)** TUNELL staining, 1s: Group 1, immune negative normal tissues, 2's: Group 2, severe immunopositive tissues, 3s: Group 3, slightly positive tissues, 4s: Group 4, slightly positive tissues.

stated in the literature, instantaneous blood flow to the testis may result in infertility at a rate of 29–50%.<sup>[10,11]</sup> Ischemic damage resulting from TT is associated with inflammation and oxidative stress, and reperfusion and reoxygenation following detorsion are characterized by an increase in free oxygen radicals and reactive nitrogen radicals.<sup>[12]</sup> Testicular T/D is a typical I/R injury that causes testicular dysfunction, loss of spermatogenesis, permanent damage to testicular tissue, and male infertility by many different mechanisms.<sup>[13]</sup>

The previous studies have shown that osthole has beneficial effects on cerebral, intestinal, and renal I/R injury.<sup>[3,5,6]</sup> In the

English literature review so far that we could dredge up, this is the first study to show that osthole could prevent testicular I/R injury.

MDA concentration is the end product of lipid peroxidation and is directly proportional to cell damage due to free oxygen radicals.<sup>[14]</sup> SOD and GSH are two important markers that eliminate free oxygen radicals. Therefore, MDA, SOD, and GSH are used as markers of oxidative stress.<sup>[10]</sup> It is known that SOD and GSH decrease and MDA increases in testicular I/R models. It was previously shown that osthole treatment increased SOD and GSH and decreased MDA decreasing the oxidative damage.<sup>[15,16]</sup> NRF 2 is a transcription factor that induces endogenous antioxidant enzymes in response to oxidative stress. In the previous studies, osthole therapy has been shown to be an “NRF-2 upregulation” in myocardial I/R damage.<sup>[7]</sup> In our study, the significant increase in NRF2 levels after osthole treatment in both Group 3 and Group 4 compared to Group 2 caused a significant increase in endogenous antioxidants such as SOD and GSH ( $p < 0.05$ ). The increase in endogenous antioxidants, on the other hand, caused a significantly lower level of MDA, which is the end product of lipid peroxidation and is an indicator of cell damage due to free oxygen radicals ( $p < 0.05$ ). The statistically significant difference between Group 3 and Group 4 in SOD, GSH, and MDA levels ( $p < 0.05$ ) shows that repeated osthole therapy could reduce oxidative stress.

The torrid relationship between inflammation and cellular damage has much been publicized in I/R studies. The role of leukocytes in I/R model has been demonstrated quite as much. MPO is a lysosomal enzyme released from leukocytes in response to oxidative stress.<sup>[17]</sup> IL-6 is a cytokine that has an important role in hematopoiesis, host defense, inflammation, and tissue regeneration. In many studies, the increase in MPO and IL-6 after testicular I/R was associated with and elucidated by inflammation.<sup>[18,19]</sup> The previous studies have also found that osthole reduces MPO and IL-6 levels.<sup>[20,21]</sup> In our study, significantly ( $p < 0.05$ ) low MPO levels after osthole treatment in Group 3 and Group 4 may be associated with inhibition of leukocyte migration to the I/R region and/or MPO release from leukocytes. The significantly ( $p < 0.05$ ) lower IL-6 levels in Group 3 and Group 4 compared to Group 2 after osthole treatment was interpreted as suppression of the inflammatory process as a result of the release of anti-inflammatory cytokines and inhibition of proinflammatory mediators. Although the lower levels of IL-6 and MPO were observed in Group 4, no statistically significant difference was observed. We think that a statistically significant difference could be reached with repeated osthole treatment sessions.

8-OHdG is the repair byproduct of the oxidized guanine nucleotide formed through DNA hydroxylation and is therefore considered a suitable biomarker of oxidative stress and ROS-induced DNA damage.<sup>[22,23]</sup> In the previous studies, it has been shown that 8-OHdG is increased in rats who un-

derwent testicular I/R.<sup>[24,25]</sup> The previous studies with osthole did not inspect 8-OHdG. In our study, DNA damage caused by testicular I/R decreased significantly in Group 3 and Group 4 compared to Group 2.

Apoptosis is a well-known fact in I/R. Caspase 3, the end product of apoptotic cell death, is an indicator of apoptosis activation.<sup>[26,27]</sup> Caspase 3 is an indicator of the common pathway in apoptotic cell death, caspase 8 is an indicator of the intrinsic pathway, and caspase 9 is an indicator of the extrinsic pathway.<sup>[28,29]</sup> In their study, Kim et al.<sup>[29]</sup> found that caspase 3, caspase 8, and caspase 9 expressions were increased in rats who underwent testicular I/R. It has been revealed that caspase 3 and caspase 9 are reduced after osthole treatment in rats with an I/R model in different organs.<sup>[30,31]</sup> TUNELL staining, another indicator of DNA damage and apoptosis, distinguishes cleavage of genomic DNA during apoptosis, which presents in situ DNA fragmentation in germ cells.<sup>[32]</sup> TUNELL staining activity increased in rats who underwent testicular I/R.<sup>[33,34]</sup> In a cerebral and myocardial I/R model performed, osthole was found to reduce TUNELL staining activity.<sup>[35]</sup> In our study, negative staining with caspase 3, caspase 8, caspase 9 and TUNELL was detected in Group 1, while moderate immunopositive staining was found for all four parameters in Group 2. There was mild immunopositive staining with caspase 3 in Group 3 and immunonegative staining was observed in Group 4 similar to Group 1. While there was moderate immunopositive TUNELL staining in Group 3, mild immunopositive staining was detected in Group 4. This indicates that apoptosis may further be reduced with repeated doses.

Histopathological examination with HE in light microscopy showed moderate changes in Group 2, while mild changes were observed in Group 3 and Group 4. This shows us that osthole provided histopathological improvement in testicular I/R damage.

## Conclusion

In our study, we observed that osthole reduced oxidative damage by activating endogenous antioxidants through NRF2, suppressed the inflammatory process with its anti-inflammatory feature, prevented apoptosis by reducing DNA damage, and reduced cell damage. We think that with repeated doses, cellular damage would gradually decline. In further studies, we intend to examine the effect of more repeated doses of osthole on testicular I/R damage.

**Ethics Committee Approval:** This study was approved by the Harran University Animal Experiment Research Center Ethics Committee (Date: 11.01.2017, Decision No: 2017/001 01-05).

**Peer-review:** Internally peer-reviewed.

**Authorship Contributions:** Concept: O.H.K.; Design: O.H.K., T.G.; Supervision: M.E.D., M.E.B.; Resource: İ.K., N.Y., M.E.D.; Materials: N.Y., H.C.; Data: İ.K., H.C.; Analysis: H.C.,

NY, İ.K.; Literature search: O.H.K., T.G.; Writing: O.H.K., M.E.B.; Critical revision: M.E.B., M.E.D.

**Conflict of Interest:** None declared.

**Financial Disclosure:** The authors declared that this study has received no financial support.

## REFERENCES

1. Meštrović J, Pogorelić Z, Drmić-Hofman I, Vilović K, Todorčić D, Popović M. Protective effect of urapidil on testicular torsion-detorsion injury in rats. *Surg Today* 2017;47:393–8. [\[CrossRef\]](#)
2. Mogilner JG, Elenberg Y, Lurie M, Shiloni E, Coran AG, Sukhotnik I. Effect of dexamethasone on germ cell apoptosis in the contralateral testis after testicular ischemia-reperfusion injury in the rat. *Fertil Steril* 2006;85 Suppl 1:1111–7. [\[CrossRef\]](#)
3. Li K, Ding D, Zhang M. Neuroprotection of osthole against cerebral ischemia/reperfusion injury through an anti-apoptotic pathway in rats. *Biol Pharm Bull* 2016;39:336–42. [\[CrossRef\]](#)
4. Zhou YF, Li L, Feng F, Yuan H, Gao DK, Fu LA, et al. Osthole attenuates spinal cord ischemia-reperfusion injury through mitochondrial biogenesis-independent inhibition of mitochondrial dysfunction in rats. *J Surg Res* 2013;185:805–14. [\[CrossRef\]](#)
5. Zhang Z, Pan C, Wang HZ, Li YX. Protective effects of osthole on intestinal ischemia-reperfusion injury in mice. *Exp Clin Transplant* 2014;12:246–52.
6. Luo LN, Xie Q, Zhang XG, Jiang R. Osthole decreases renal ischemia-reperfusion injury by suppressing JAK2/STAT3 signaling activation. *Exp Ther Med*. 2016;12:2009–14. [\[CrossRef\]](#)
7. Cheng L, Jin Z, Zhao R, Ren K, Deng C, Yu S. Resveratrol attenuates inflammation and oxidative stress induced by myocardial ischemia-reperfusion injury: Role of Nrf2/ARE pathway. *Int J Clin Exp Med* 2015;8:10420–8.
8. Koyuncu I, Kocyigit A, Gonel A, Arslan E, Durgun M. The protective effect of naringenin-oxime on cisplatin-induced toxicity in rats. *Biochem Res Int* 2017;2017:9478958. [\[CrossRef\]](#)
9. Ohkawa H, Ohishi N, Yagi K. Assay for lipid peroxides in animal tissues by thiobarbituric acid reaction. *Anal Biochem* 1979;95:351–8. [\[CrossRef\]](#)
10. Ringdahl E, Teague L. Testicular torsion. *Am Fam Physician* 2006;74:1739–43.
11. Bartsch G, Frank S, Marberger H, Mikuz G. Testicular torsion: Late results with special regard to fertility and endocrine function. *J Urol* 1980;124:375–8. [\[CrossRef\]](#)
12. Kemahli E, Yildiz M, Firat T, Özyalvaçlı ME, Üyetürk U, Yılmaz B, et al. An experimental study on effects of pyrrolidine dithiocarbamate on ischemia-reperfusion injury in testis. *Can Urol Assoc J* 2016;10:E104–9. [\[CrossRef\]](#)
13. Meštrović J, Drmić-Hofman I, Pogorelić Z, Vilović K, ŠupeDomić D, Šešelja-Perišin A, et al. Beneficial effect of nifedipine on testicular torsion-detorsion injury in rats. *Urology* 2014;84:1194–8. [\[CrossRef\]](#)
14. Gutteridge JM, Halliwell B. The measurement and mechanism of lipid peroxidation in biological systems. *Trends Biochem Sci* 1990;15:129–35.
15. Dong W, Zhang Z, Liu Z, Liu H, Wang X, Bi S, et al. Protective effects of osthole, A natural derivative of coumarin, against intestinal ischemia-reperfusion injury in mice. *Int J Mol Med* 2013;31:1367–74. [\[CrossRef\]](#)
16. Zhou WB, Zhang XX, Cai Y, Sun W, Li H. Osthole prevents tamoxifen-induced liver injury in mice. *Acta Pharmacol Sin* 2019;40:608–19. [\[CrossRef\]](#)
17. Topaloğlu N, Memi G, Kaner T, Deniz M, Şahin Ö, Güven M, et al. Does Glp-2 have a protective effect on cerebral ischemia/reperfusion model? *Turk J Med Sci* 2015;45:467–73. [\[CrossRef\]](#)
18. Zheng N, Shao H, Wu D, Shen D, Lin X. Protective influence of rosiglitazone against testicular ischaemia-reperfusion injury in rats. *Andrologia*.

- 2018 Jan 9. doi: 10.1111/and.12947. [Epub ahead of print]. [CrossRef]
19. Kurcer Z, Oguz E, Ozbilge H, Baba F, Aksoy N, Celik N. Effect of melatonin on testicular ischemia/reperfusion injury in rats: Is this effect related to the proinflammatory cytokines? *Fertil Steril* 2008;89 Suppl 5:1468–73. [CrossRef]
  20. Mo LQ, Chen Y, Song L, Wu GM, Tang N, Zhang YY, et al. Osthole prevents intestinal ischemia-reperfusion-induced lung injury in a rodent model. *J Surg Res* 2014;189:285–94. [CrossRef]
  21. Yu HP, Liu FC, Tsai YF, Hwang TL. Osthole attenuates hepatic injury in a rodent model of trauma-hemorrhage. *PLoS One* 2013;8:e65916. [CrossRef]
  22. Martins G, Marques A, Fortunato E, Sales M. 8-hydroxy-2-deoxyguanosine (8-OHdG) biomarker detection down to picoMolar level on a plastic antibody film. *Biosens Bioelectron* 2016;86:225–34. [CrossRef]
  23. Dabrowska N, Wiczowski A. Analytics of oxidative stress markers in the early diagnosis of oxygen DNA damage. *Adv Clin Exp Med* 2017;26:155–66. [CrossRef]
  24. Aitken RJ, Whiting S, Connaughton H, Curry B, Reinheimer T, van Duin M. A novel pathway for the induction of DNA damage in human spermatozoa involving extracellular cell-free DNA. *Mutat Res* 2020;821:111722. [CrossRef]
  25. Tamer SA, Yildirim A, Koroğlu MK, Çevik Ö, Ercan F, Yeğen BÇ. Nesfatin-1 ameliorates testicular injury and supports gonadal function in rats induced with testis torsion. *Peptides* 2018;107:1–9. [CrossRef]
  26. Adamiec-Mroczek J, Zajac-Pytrus H, Misiuk-Hojfo M. Caspase-dependent apoptosis of retinal ganglion cells during the development of diabetic retinopathy. *Adv Clin Exp Med* 2015;24:531–5. [CrossRef]
  27. Sánchez-Migallón MC, Valiente-Soriano FJ, Nadal-Nicolás FM, Vidal-Sanz M, Agudo-Barruso M. Apoptotic retinal ganglion cell death after optic nerve transection or crush in mice: Delayed RGC Loss With BDNF or a caspase 3 inhibitor. *Invest Ophthalmol Vis Sci* 2016;57:81–93.
  28. Elmore S. Apoptosis: A review of programmed cell death. *Toxicol Pathol* 2007;35:495–516. [CrossRef]
  29. Kim HJ, Lee JW, Hwang BR, Lee YA, Kim JI, Cho YJ, et al. Protective effect of pterostilbene on testicular ischemia/reperfusion injury in rats. *J Pediatr Surg* 2016;51:1192–6. [CrossRef]
  30. Duan J, Yang Y, Liu H, Dou PC, Tan SY. Osthole ameliorates acute myocardial infarction in rats by decreasing the expression of inflammatory-related cytokines, diminishing MMP-2 expression and activating p-ERK. *Int J Mol Med* 2016;37:207–16. [CrossRef]
  31. Wu J, Yang Y, Xun N, Zeng L, Li Z, Yang W, et al. Osthole attenuates myocardial ischemia/reperfusion injury in rats by inhibiting apoptosis and inflammation. *Am J Transl Res* 2018;10:1109–16.
  32. Ghasemnejad-Berenji M, Ghazi-Khansari M, Yazdani I, Saravi S, Nobakht M, Abdollahi A, et al. Rapamycin protects testes against germ cell apoptosis and oxidative stress induced by testicular ischemia-reperfusion. *Iran J Basic Med Sci* 2017;20:905–911.
  33. Azarabadi M, Heidari F, Khaki AA, Kaka G, Ghadian A. Minocycline attenuates testicular damages in a rat model of ischaemia/reperfusion (I/R) injury. *Andrologia* 2020;52:e13704. [CrossRef]
  34. Tanriverdi HI, Şenel U, Gevrek F, Akbaş A. Protective effect of famotidine on ischemia-reperfusion injury following testicular torsion in rats. *J Pediatr Urol* 2020;17:167.e1–7. [CrossRef]
  35. Liu S, He Y, Shi J, Liu L, Ma H, He L, et al. Downregulation of miRNA-30a enhanced autophagy in osthole-alleviated myocardium ischemia/reperfusion injury. *J Cell Physiol*. 2019 Apr 24. doi: 10.1002/jcp.28556. [Epub ahead of print]. [CrossRef]

## DENEYSEL ÇALIŞMA - ÖZ

## Ostolün sıçanlarda testis iskemi/reperfüzyon hasarı üzerine koruyucu etkisi

Dr. Osman Hakan Kocaman,<sup>1</sup> Dr. Tansel Günendi,<sup>1</sup> Dr. Mustafa Erman Dörterler,<sup>1</sup> Dr. İsmail Koyuncu,<sup>2</sup> Dr. Hakim Celik,<sup>3</sup> Dr. Nihat Yumusak,<sup>4</sup> Dr. Mehmet Emin Boleken<sup>1</sup>

<sup>1</sup>Harran Üniversitesi Tıp Fakültesi, Çocuk Cerrahisi Anabilim Dalı, Şanlıurfa

<sup>2</sup>Harran Üniversitesi Tıp Fakültesi, Tıbbi Biyokimya Anabilim Dalı, Şanlıurfa

<sup>3</sup>Harran Üniversitesi Tıp Fakültesi, Fizyoloji Anabilim Dalı, Şanlıurfa

<sup>4</sup>Harran Üniversitesi Veteriner Fakültesi, Patoloji Anabilim Dalı, Şanlıurfa

**AMAÇ:** Testis torsiyonu, zamanında teşhis ve tedavi edilmezse testis kaybına neden olan acil cerrahi müdahale gerektiren ürolojik bir acil durumdur. Dokuya giden kan akımının azalması ile başlayan oksijen yetersizliği ile iskemik doku hasarı, reperfüzyon sağlanır sağlanmaz hasarlı dokuların yeniden oksijenlenmesi ile artarak devam eder. Çeşitli çalışmalarda ostolün beyin, omurilik, bağırsak, böbrek ve miyokardiyal iskemi/reperfüzyon (I/R) hasarını da azalttığı gösterilmiştir. Bu çalışmanın amacı, ostolün testis I/R hasarı üzerindeki etkilerini incelemektir.

**GEREÇ VE YÖNTEM:** Yirmi sekiz Wistar-albino sıçan rastgele dört deney grubuna ayrıldı (n=7). Grup 1 sham operasyon grubuydu. Grup 2'de (I/R uygulanan sıçanlar) testis saat yönünde 720° döndürülerek üç saatlik iskemi oluşturuldu. ardından üç saatlik reperfüzyon sağlandı. Grup 3'te (I/R+tek doz ostol uygulanan sıçanlar) üç saatlik torsiyonun ardından detorsiyondan yarım saat önce intraperitoneal dozda 20 mg/kg ostol uygulandı. Testis detorsiyone edildi. Üç saatlik detorsiyon uygulandı. Grup 4'te (I/R+iki doz ostol uygulanan sıçanlar) üç saatlik torsiyonu takiben detorsiyondan yarım saat önce intraperitoneal dozda 20 mg/kg ostol uygulandı. Testis serbest bırakıldı ve detorsiyon yapıldı. Detorsiyondan yarım saat sonra tekrar intraperitoneal doz olarak 20 mg/kg ostol uygulandı. Üç saatlik detorsiyon yapıldı. Tüm sıçanlar altı saatin sonuna sakrifiye edilerek biyokimyasal analiz için kan ve histopatolojik örnek için sağ orşiektomi yapıldı.

**BULGULAR:** Grup 2'de GSH, NRF2, SOD, 8-OHDOG seviyeleri azalırken, IL-6, MDA ve MPO seviyelerinde artış saptandı. Grup 2'deki sıçanlarda kaspaz 3, kaspaz 8, kaspaz 9 ve TUNEL immünhistokimyasal olarak orta düzeyde immünopozitif dokular gösterirken, grup 3 ve grup 4'te hafif immünopozitif dokular tespit edildi. Histokimyasal incelemede grup 2'de dejeneratif tübül yapısı ve epitel hücrelerinin ayrılması gözlenirken, grup 3 ve grup 4'te kısmen iyileşmiş testis dokusu tespit edildi.

**TARTIŞMA:** Çalışmamızda ostolün oksidatif hasarı azalttığını, enflamatuvar süreci baskıladığını, apoptozu önlediğini ve hücre hasarını azalttığını gözlemledik. Tekrarlanan dozlarla hücre hasarının kademeli olarak azalacağını düşünüyoruz.

**Anahtar sözcükler:** Antioksidan; apoptozis; kaspaz; osthole; testis torsiyonu.

Ulus Travma Acil Cerrahi Derg 2022;28(5):563-569 doi: 10.14744/tjtes.2021.43333