

# Isolated axillary artery injury due to blunt trauma

## Aksiller arterin künt travmaya bağlı izole hasarlanması

Mehmet ÖÇ, Murat GÜVENER, H. İbrahim UÇAR, Birkan AKBULUT,  
Mustafa YILMAZ, Ünsal ERSOY

The intimal damage of the axillary artery due to an acute, single blunt trauma is very rare without concomitant bone, brachial plexus, venous and soft tissue injuries. Early diagnosis and appropriate management of the arterial injury is essential to avoid permanent disability. The clinical signs are usually occult and do not become manifest until a long ischemic interval following injury, owing to the extensive collateral network. A twenty-year-old male patient had injured his left arm in a hyperabduction and hyperextension position while he was carrying a refrigerator with his arm. An increase in the intensity of pain and numbness reappeared in his left arm 1.5 months after the trauma. Digital subtraction angiography of the axillary artery performed after his hospitalization showed an occlusion of the axillary artery and no reconstruction of distal part of the occlusion via collateral vessels. During the operation, the axillary and brachial arteries were bypassed with a saphenous graft. As shown in this case report, in the early period after blunt trauma of the upper limb, progressive signs of vascular compromise may disappear because of collateral circulation even if the distal pulses are absent. Then an angiography of the upper limb becomes essential for correct diagnosis and treatment. This is our second experience. On the basis of our first experience that was reported, in such a chronic case, oral anticoagulation must be carried out at least six months whenever a graft thrombosis after revascularization is encountered.

**Key Words:** Axillary artery/injuries; blunt trauma; long ischemic interval.

Kemik, brakiyal pleksus, ven ve yumuşak doku hasarı olmadan ani ve tek künt travmaya bağlı olarak aksiller arterin intimal hasarı çok nadirdir. Arteriyel yaralanmanın kalıcı hasar bırakmaması için erken tanı ve uygun tedavi gereklidir. Klinik belirtiler genelde belli belirsizdir ve kollateral dolaşıma bağlı olmak üzere yaralanma sonrası, uzun iskemik dönem geçtikten sonra belirginleşmektedir. Yirmi yaşındaki erkek hasta, kolu hiperabduksiyon ve hiperekstansiyon pozisyonunda buzdolabı taşıırken sol kolunu incinme ve bundan 1,5 ay sonra sol kolundaki ağrı ve uyuşukluk şikayetleriyle başvurdu. Hastanın hastaneye yatışından sonra yapılan aksiller arter dijital substraksiyon anjiyografisinde aksiller arterin oklüzyonu izlendi ve oklüzyonun distalinde kollaterallerle dolun gözlenmedi. Ameliyatta, aksiler ve brakiyal arter safen ven ile baypas edildi. Üst ekstremitenin künt travmasının erken döneminde kollateral dolaşım nedeniyle vasküler yetersizlik distal nabızlar olsa bile tanınamayabilmekte ve üst ekstremitenin anjiyografisi doğru tanı ve tedavi için kaçınılmaz olmaktadır. Bu olgu bizim ikinci tecrübemizdir; birinci olgudaki tecrübemize dayanarak bu olguda olduğu gibi kronik durumlarda revascularizasyon sonrası greft trombozu söz konusuysa oral antikoagülasyona en az altı ay devam edilmesi gerektiğini düşünmekteyiz.

**Anahtar Sözcükler:** Aksiller arter/yaralanma; künt travma; uzun iskemik dönem.

Traumatic lesions of the axillary artery represent 15-20% of the arterial injuries of the upper limbs.<sup>[1]</sup> Ninety-four percent of the traumas are resulting from the penetrating wounds, while remaining 6% are caused by blunt traumas that follow a shoulder-fracture dislocation.<sup>[2,3]</sup> It is marked that axillary artery

damage often occurs together with the injury of the brachial plexus,<sup>[4]</sup> whose incidence ranges from 27% to 44%<sup>[5]</sup> and venous and musculoskeletal injury.<sup>[6]</sup> In current literature, isolated axillary artery injury as in this case has been reported in two papers.<sup>[7,8]</sup> One of them was reported by us.<sup>[7]</sup>

Herein we report a case of an isolated axillary artery injury, which occurred in a 20-year-old male patient due to a single blunt trauma. The patient was treated successfully with surgical intervention, although he had been admitted to the hospital following a long ischemic interval.

### CASE REPORT

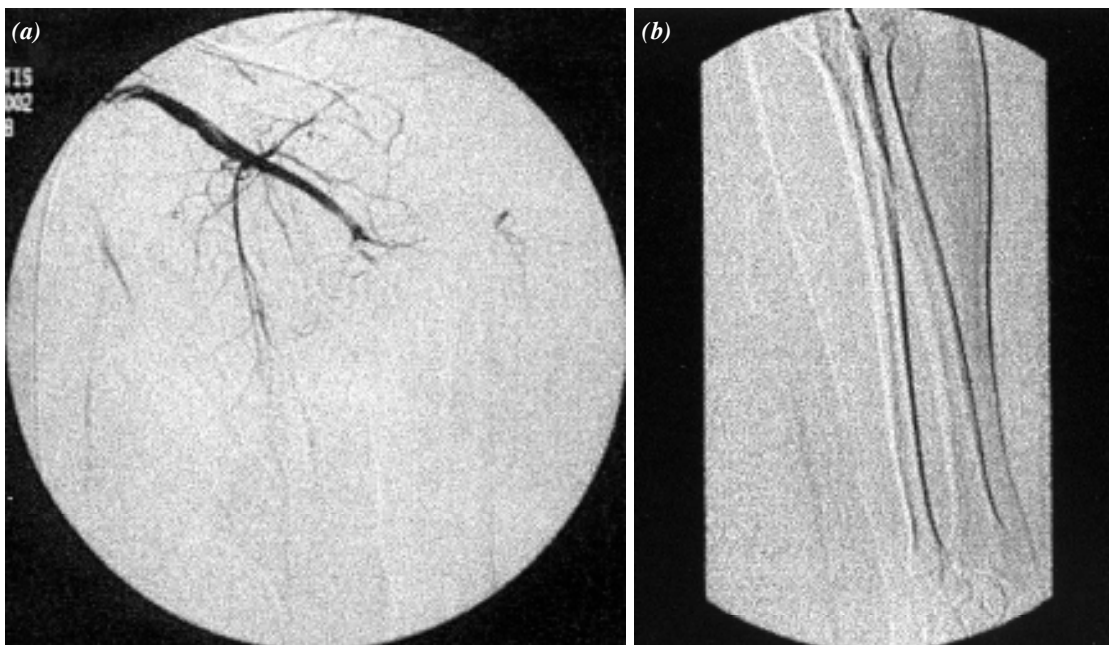
A twenty-year-old male patient was admitted to our hospital with complaints of a chronic severe burning type of pain, rapid fatigue on exertion and numbness throughout his left upper limb. Further questioning showed that he had injured his left arm one month ago while he was trying to carry a refrigerator with his arm in a hyperabduction and hyperextension position. Numbness and severe burning type of pain appeared in his left arm however after a short time the numbness faded out and the pain remained, but less prominent. An increase in the intensity of pain and numbness reappeared in his left arm 1.5 months after the trauma, so he decided to seek professional assistance. The physical examination was as following: Arterial pressure was 120/80 mmHg on the right arm and the left arm was cold and cyanotic; the pulses were absent. No limitation of the left arm movements was detectable and the sensory-motor

function was intact. The X-ray studies of the chest and left arm were assessed to be normal.

Ankle-brachial ratio index was measured as 0.25. Arterial pressure on the left arm via noninvasive method could not be measured. Selective digital subtraction angiography of the axillary artery showed an occlusion of the axillary artery and no reconstitution of distal part of the occlusion via collaterals (Fig. 1a, b).

During the operation, left axillary and brachial arteries were exposed via the incision of axillary region and the occlusion was confirmed by the absence of pulsation just distal part of to the anterior circumflex branch. Although the adventitia of the axillary artery was intact, a dark transverse line was evident, representing the transection of the deeper layers of the axillary arterial wall. On palpation, the axillary and the brachial arteries were filled with thrombus.

There was no macroscopic evidence of associating nerve injury. Two thousand five hundred units of heparin were administered systemically. Axillary, brachial, ulnar and radial arteries embolectomies were performed and highly organized thrombus was removed via repeated thrombectomies. However,



**Fig. 1.** (a) Preoperative angiogram showing an occlusion of the axillary artery and filling of the brachial artery beyond via collaterals. (b) Preoperative angiogram showing the minimal filling of radial and ulnar arteries and no filling of distal of them.

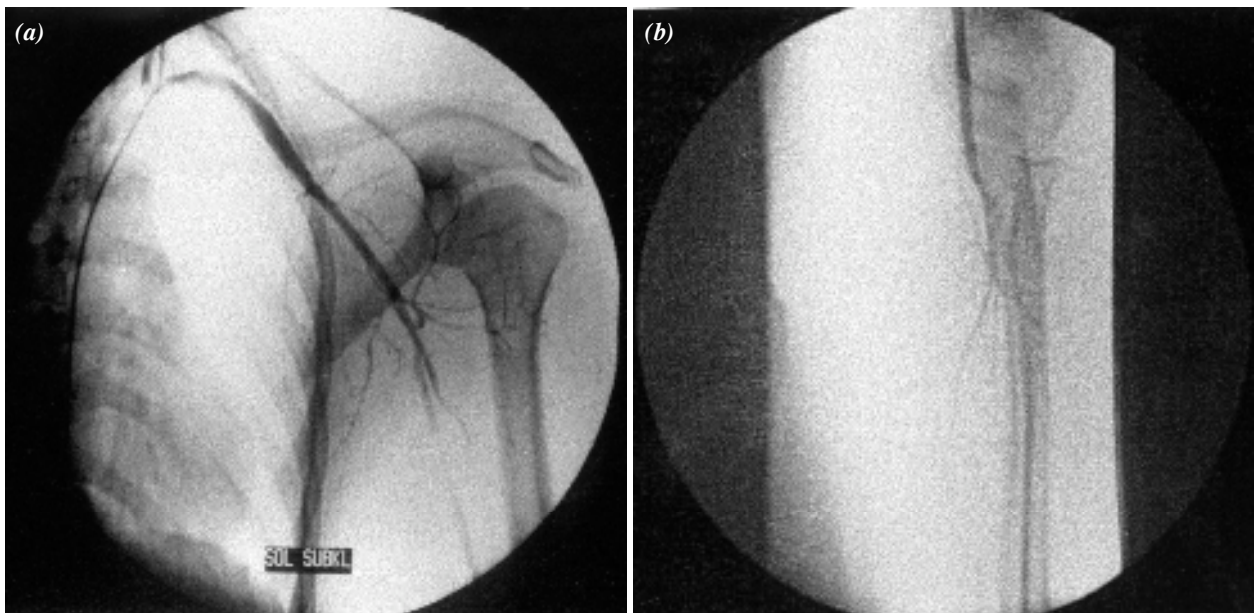
there was no flow in the axillary artery; only a very weak back-flow in the brachial artery was detected, which was contributed by the collaterals. After an adequate exploration, revascularization was re-established by a saphenous interposition graft anastomosed by end-to-side fashion from the axillary artery site and end-to-end fashion to the distal part of the brachial artery. An end-to-side fashion proximal anastomosis was preferred to preserve main collateral arising in immediate proximity of dissection. Pulses at the brachial artery reappeared and arterial perfusion of the whole arm was maintained. But the distal radial and ulnar pulses remained to be absent.

After the operation, TA on left arm was 120/70 mmHg and ankle-brachial ratio was measured as 0.50. Control angiography was done since radial and ulnar pulses became palpable 12 hours after the operation. And control angiography of the patient confirmed the patency of the saphenous graft and normal flow both in the graft and in the distal arteries (Fig. 2a, b). A course of prophylactic antibiotics was commenced. Coumadin and aspirin were given together. Postoperative anticoagulation with subcutaneous heparin was continued until international normalized ratio (INR) increased up to a level about 2 with coumadin. Radial and ulnar pulses became palpable at the first postoperative day morning.

The postoperative course lacked any complication and the patient was discharged 7 days after operation with coumadin and aspirin treatment. After a period of three months postoperatively the patient had no complaints and distal pulses were intact.

## DISCUSSION

As previously mentioned, the incidence of the axillary artery injury due to blunt trauma is very rare. Looking through the reported cases it was shown that there was always an associated lesion together with the axillary artery injury. Such as, axillary artery injury together with the shoulder fracture-dislocation following a blunt is not uncommon.<sup>[2,3,9]</sup> According to some authors, presence of advanced arteriosclerosis in the axillary artery and its diminished elastic ability to compensate for this disorganization of anatomy may play an important role in the axillary artery injury.<sup>[3,5,9]</sup> Regarding the associated lesions, axillary artery injury often occurs together with the injury of the brachial plexus which may lead to severe disability to the upper limb. Clinical evidence of nerve lesions are encountered in 27% to 44% of cases.<sup>[5]</sup> Functional recovery from neurovascular damages depends both on early revascularization and on restoration of the nerve function.<sup>[10]</sup> It is well known that the ischemic interval from injury to repair and associated nervous, venous and musculoskeletal



**Fig. 2.** (a) Postoperative angiogram showing proximal anastomoses of the saphenous graft and normal flow in the graft. (b) Postoperative angiogram showing distal anastomoses of the saphenous graft and normal flow in the distal arteries.

deficits are all factors in limb salvage after a blunt trauma.<sup>[5,10,11]</sup> Presence of extensive collateral network around shoulder joint may obscure the physical signs of the axillary artery injury and hinder early diagnosis and treatment as in this case report. The presented patient did not request any medical aid until collateral circulation became insufficient. Ankle-brachial ratio was measured as 0.25. Gold standard of the diagnosis is still angiography. Following angiography, a surgical approach should be taken into consideration as seen in our case; a good surgical result can be obtained, regardless of the length of the ischemic period. Usually the affected patients are young and in the most productive period of life.<sup>[12]</sup>

The ideal type of vascular repair depends on the nature and extent of arterial injury and the options available. Regarding the surgical treatment, arterial ligation has been abandoned completely today. In case of complete transection as seen in this case report, the choice of reconstruction is either direct end-to-end anastomosis or the vein or prosthetic interposition grafts. Most vascular surgeons would avoid using prosthetic material distal to the subclavian artery since the long-term patency rate is poor. An exploration should be made with a Fogarty catheter to remove any intraluminal thrombus in the distal arterial tree.<sup>[9]</sup> Avulsion of the collateral branch is usually treated with ligation. The important point is that, the collateral branches should not be sacrificed to allow adequate mobilization of arterial ends to perform an end-to-end anastomosis. We performed the proximal anastomosis in end-to-side fashion to preserve the collateral arising in immediate proximity of dissection. Since the synthetic arterial conduit, such as Gore-tex, carries a small but theoretical risk of infection,<sup>[5]</sup> autogenous saphenous vein grafts as employed in this case can be used preferentially as a substitute to vascular conduits, especially in the mobile regions.

### CONCLUSION

This case report demonstrates an isolated axillary artery injury due to blunt trauma, an example of the

natural history of an unrecognized, untreated intimal dissection of the axillary artery and the success even in a delayed arterial reconstruction but awarding to experience of the first case who was a 10 year-old boy with similar history and operation,<sup>[7]</sup> coumadin treatment should be continued at least 6 months after the operation because of distal endothelial chronic damage in delayed cases like this (In the first case, 6 months after the operation saphenous vein thrombectomy was performed. The reason of the saphenous graft thrombosis might be related to bad distal run off).

### REFERENCES

1. Adovasio R, Visintin E, Sgarbi G. Arterial injury of the axilla: an unusual case after blunt trauma of the shoulder. *J Trauma* 1996;41:754-6.
2. Laverick MD, D'Sa AA, Kirk SJ, Mollan RA. Management of blunt injuries of the axillary artery and the neck of the humerus: case report. *J Trauma* 1990;30:360-1.
3. Wilgis EF. *Vascular injuries and disease of the upper limb*. Boston: Little, Brown; 1983.
4. Turnbull AR. Vascular injuries to the extremities following blunt trauma: discussion paper. *J R Soc Med* 1985;78:117-8.
5. Graham JM, Mattox KL, Feliciano DV, DeBakey ME. Vascular injuries of the axilla. *Ann Surg* 1982;195:232-8.
6. McKinley AG, Carrim AT, Robbs JV. Management of proximal axillary and subclavian artery injuries. *Br J Surg* 2000;87:79-85.
7. Guvener M, Kaplan S, Demircin M, Pasaoglu I. Axillary artery injury: an isolated, delayed case after blunt trauma of the upper limb. *J Trauma* 2000;48:951-3.
8. Hodina M, Gudinchet F, Reinberg O, Schnyder P. Imaging of blunt arterial trauma of the upper extremity in children. *Pediatr Radiol* 2001;31:564-8.
9. Drury JK, Scullion JE. Vascular complications of anterior dislocation of the shoulder. *Br J Surg* 1980;67:579-81.
10. Deitch EA, Grimes WR. Experience with 112 shotgun wounds of the extremities. *J Trauma* 1984;24:600-3.
11. Hardin WD Jr, O'Connell RC, Adinolfi MF, Kerstein MD. Traumatic arterial injuries of the upper extremity: determinants of disability. *Am J Surg* 1985;150:266-70.
12. Johnson SF, Johnson SB, Strodel WE, Barker DE, Kearney PA. Brachial plexus injury: association with subclavian and axillary vascular trauma. *J Trauma* 1991;31:1546-50.