Early decompressive craniectomy for neurotrauma: an institutional experience

Nörotravmaya yönelik erken dekompresif kranyektomi: Bir merkezin deneyimi

Andrès Mariano RUBIANO,[1] Wilson VILLARREAL,[1] Enrique Jimenez HAKIM,[2] Jorge ARISTIZABAL,[3] Fernando HAKIM,[2] Juan Carlos DÌEZ,[3] Germàn PEÑA,[2] Juan Carlos PUYANA[4]

BACKGROUND

Neurotrauma centers have developed management protocols on the basis of evidence obtained from literature analysis and institutional experience. This article reviews our institutional experience in the management of severe traumatic brain injury (TBI) at Simòn Bolivar Hospital, the district trauma center for Bogotá's north zone.

METHODS

This is a case control study comparing a group of patients (n: 16) operated for severe TBI between January 2002 and July 2004 according to an institutional management protocol characterized by an early decompressive craniectomy (DC) approach versus a historical control group (n: 20) managed before the implementation of such protocol. Mortality and Glasgow Outcome Score (GOS) at 6 months were used as the main outcome variables.

RESULTS

An early DC protocol implemented within 12 hours from injury in 16 patients with severe isolated TBI and a Marshall score between III or IV was associated with a lesser mortality than the conventional approach with ventriculostomy and Intensive Care Unit (ICU) management alone. The GOS was significantly better in the DC group (p=0.0002) than in the control group.

CONCLUSION

The use of an early DC protocol for severe TBI patients (Glasgow Coma Scale <9) had a significantly improved outcome compared with the conventional approach with ventriculostomy and ICU management in Simòn Bolivar Hospital in Bogotá, Colombia.

Key Words: Decompressive craniectomy; neurotrauma; severe head trauma; traumatic brain injury.

AMAÇ

Nörotravma merkezleri, literatür analizi ve kendi deneyimlerinden elde edilen kanıt esasına göre tedavi protokolleri geliştirmiştir. Bu yazıda, Bogota'nın kuzey bölgesindeki kırsal kesime yönelik bir travma merkezi olan Simòn Bolivar Hastanesi'ndeki ciddi travmatik beyin yaralanması (TBY) tedavisi ile ilgili kendi deneyimi gözden geçirildi.

GEREÇ VE YÖNTEM

Bu çalışma, ciddi TBY'ye yönelik olarak Ocak 2002 ile Temmuz 2004 tarihleri arasında merkezin kendi protokolü gereği erken dekompresif kranyektomi (DK) uygulanan bir grup hastayı (n=16), böyle bir protokol uygulamaya sokulmadan önce tedavi edilen tarihi bir kontrol grubu (n=20) ile karşılaştıran bir olgu kontrol çalışmasıdır. Başlıca sonuç değişkenleri olarak, altıncı aydaki mortalite ve Glasgow Sonuç Skoru (GOS) kullanılmıştır.

BULGULAR

Ciddi izole TBY'si olan 16 hastada uygulanan erken bir DK protokolü ile yaralanmadan itibaren 12 saatten daha kısa bir süre içinde III ve IV arasında kalan bir Marshall skoru, tek başına ventrikülostomi ve Yoğun Bakım Ünitesi (YBÜ) tedavisi ile birlikte olan konvansiyonel yaklaşıma göre daha düşük bir mortaliteye neden olmuştur. GOS, kontrol grubuna göre DK grubunda anlamlı şekilde daha iyi olmuştur (p=0,0002).

SONUÇ

Kolombiya Simòn Bolivar Hastanesinde, şiddetli TBY hastalarına (Glasgow Koma Skalası <9) yönelik olarak erken bir DK protokolünün kullanılması, klinik sonuçları tek başına ventrikülostomi ve YBÜ tedavisi ile birlikte olan konvansiyonel yaklaşıma göre belirgin şekilde iyileştirmiştir.

Anahtar Sözcükler: Dekompresif kranyektomi; nörotravma; ciddi kafatravması; travmatik beyin yaralanması.

Neurological Surgery Services, [1]Simòn Bolivar Hospital, Bogotá, [2]Fundación Santa Fe de Bogotá, [3]Clìnica El Bosque, Bogotá, Colombia; [4]Trauma and Critical Care Department, University of Pittsburgh, Pennsylvania, USA.

[1]Simon Bolivar Hastanesi, Nöroşirürji Kliniği, [2]Bogota Vakfı, Nöroşirürji Kliniği, [3]El Bosque, Nöroşirürji Kliniği, Bogota, Kolombiya; [4]Pittsburgh Üniversitesi, Travma ve Yoğun Bakım Bölümü, Pensilvanya, ABD.

Correspondence *(İletişim):* Andrès Mariano Rubiano, M.D. Cra 5a No: 16-29 Ap 301 El Triunfo, Neiva (Huila), Colombia.
Tel: +57 - 3132514132 Fax *(Faks)*: +57 - 88723885 e-mail *(e-posta):* andresrubiano@hispavista.com

Severe traumatic brain injury (TBI) is associated with a high mortality and morbidity. Increased understanding of the pathophysiology of TBI and the concept of primary versus secondary injury has provided new insight in the early management of TBI. Key factors related to the intrinsic pathology and their clinical implications, especially in patients with severe TBI (defined as a Glasgow Coma Scale [GCS] <9) have allowed the establishment of new and more aggressive protocols across the spectrum of neurosurgical care.

It has become widely accepted that the magnitude of the secondary injury is a function of the quality of the care from the prehospital scene, continuing with the appropriate neurocritical care, until the definitive surgical management is undertaken. These concepts, originated in specialized neurotrauma centers from North America and Europe, have begun to be applied in Latin America after their diffusion facilitated by work groups such as the Brain Trauma Foundation (BTF), the Acute Brain Injury Consortium, the European Brain Injury Consortium, and the International Neurotrauma Society.[1-6]

Colombia is a country with a population of 44 million and a very high incidence of traumatic injury, with a violence-related mortality rate between 50 to 60 per 100,000 habitants in the last 20 years. The annual income per capita is under $1,924 United States dollars (USD) and 21% of the population has a daily income under $1 USD.[7] Therefore, the implementation of these guidelines and recommendations should have a significant effect on public health. Simòn Bolivar Hospital (SBH) is a designated level one trauma center for the north side of Bogotá. The SBH actively participated in the development of a severe TBI management quality program, instituted in Colombia by FUNDCOMA (a member institution of the BTF of New York since 2001). However, since 1999, the SBH was informally implementing the recommendations of the American Association of Neurological Surgeons (AANS) guidelines. Aware of the multiple factors published in several studies.[8-11] describing poor adherence to the TBI guidelines, the staff at SBH begin an aggressive campaign to ensure maximal adherence to these guidelines after 2001.

In 2004, we performed a general overview of the TBI patients who were brought to the operating room (OR) by neurological surgery service with a GCS <9,[12] and we identified 16 patients who were managed according to the SBH early decompressive craniectomy (DC) protocol. We then identified a historical control group of 20 cases, matched according to Marshall score, computed tomography (CT) findings and the GCS, who were managed with ventriculostomy and medical/critical care therapy for intracranial pressure (ICP) control without the DC. Here, we present a comparison of these two groups of patients, which showed a significant difference between them in the incidence of mortality and long-term outcome as determined by Glasgow Outcome Score (GOS).

MATERIALS AND METHODS

Historical course, development and description of early DC protocol

The 1995 AANS guidelines document was helpful for us to begin changing our approach to the management of TBI at SBH. In 1999, we standardized the use of external ventriculostomy for cerebrospinal fluid (CSF) drainage and monitored severe TBI patients according to the proposed criteria (Table 1).

Due to the elevated number of patients with severe injuries (many of them with high-velocity penetrating trauma), we instituted early cranial decompression surgery as suggested by earlier reports.[13-16] Early decompression consisted of several techniques such as bi-frontal, temporal windows and bilateral decompression. These interventions were initially performed based on individual criteria of the hospital's attending neurosurgeons. The procedure initially was done as a second-line therapy, after 24 or 48 hours of medical management in patients with a poor response to medical therapy and with an ICP threshold of 25 mmHg. In other cases, we did the procedure in the first 12 hours after trauma. By 2002, early DC was defined as an early surgical intervention usually within 12 hours from injury aimed to diminish the duration of intracranial hypertension in a group of patients who historically had very high mortality according to our experience. In 2002, we decided to standardize the protocol of early DC for the neurotrauma program in part due to the technological limitations for cerebral metabolism monitoring in the SBH intensive care unit (ICU), always striving to obtain better outcomes in this group of patients, including the pediatric population.

Our concept of early DC surgery is based on the following aspects:

Table 1. Indications for ICP monitoring used in Simòn Bolivar Hospital, according to the AANS recommendations *(Brain Trauma Foundation, AANS. J Neurotrauma 1996;13:639-734)*

Indications for ICP monitoring according to the AANS guidelines
1. ICP Monitoring is appropriate in patients with severe TBI with abnormal admission CT scan. Severe TBI is defined as a GCS of 3-8 after cardiopulmonary resuscitation. An abnormal CT scan of the head is one that reveals hematomas, contusions, edema or compressed basal cisterns.
2. ICP Monitoring is appropriate in patients with severe TBI with a normal CT scan if two or more of the following features are noted at admission: age over 40 years, unilateral or bilateral motor posturing, and systolic blood pressure <90 mmHg.
3. ICP Monitoring is not routinely indicated in patients with mild or moderate head injury. However, a physician may choose to monitor ICP in certain conscious patients with traumatic mass lesions.

Table 2. Inclusion criteria for the early decompressive craniectomy procedure (SBH. Neurological Surgery Service Protocol)

No.Description of inclusion criteria
1. Age less than 50 years.
2. Glasgow Coma Scale <9 after the emergency room resuscitation (SaO_2 >90% and systolic blood pressure >90 mmHg) and after pharmacologic sedation or paralytic agents are metabolized if they were used (short action agents in rapid sequence induction institutional protocols).
3. Isolated, non-penetrating head injury, without other associated traumas (e.g. abdominal, thoracic or extremity injuries).
4. CT findings compatible with diffuse injury III or IV of the Marshall classification (volume and width of the lesions and the midline shift were measured with the CT scan software and correlated with the ABC method for width and the [A/2] – B method for the midline shift).
5. Evolution <12 h since the event.
6. No criteria of brain death.

1st Phase: Fast and simple decompression technique with external temporary closing.

2nd Phase: Transfer to surgical critical care unit for medical management of intracranial hypertension.

3rd Phase: Elective surgery for definitive closing.

Since 2002, this protocol has been applied in patients who fulfill the following admission criteria (Table 2):

1. Age younger than 50 years.

2. GCS <9 after emergency room resuscitation (SaO_2 >90% and systolic blood pressure [SBP] >90 mm) and after pharmacologic sedation or muscle relaxants have been metabolized if they were used (short action agents in rapid sequence intubation institutional protocols).

3. Isolated, non-penetrating head injury, without other associated traumas (i.e. abdominal, thoracic or extremity injuries).

4. CT findings compatible with diffuse injury III or IV of the Marshall classification (The volume and width of the lesions and the midline shift were measured with the CT scan software and correlated with the ABC method for width and the [A/2] – B method for the midline shift).[17,18]

5. Time from injury <12 hours.

6. Absence of brain death.

Surgical procedure

The procedure performed in the 16 early DC patients of the study was a decompressive fronto-temporo-parietal craniectomy, uni - or bilaterally according to the CT findings (diffuse edema uni- or bilateral), with dural incision in "H" form (5 cm x 10 cm), auto graft dural patch. In bilateral interventions, an osseous bar was left over the transverse sinus 3 - 4 cm in width with osteotomies at the frontal and occipital level. The osseous graft was saved in the bone bank.

Table 3. Marshall's classification of TBI based on initial computed tomography findings[19]

Category	Definition
Diffuse Injury I	No visible intracranial pathology.
Diffuse Injury II	Cisterns present with midline shift 0-5 mm and/or: lesion densities present, no high or mixed density lesion >25 cc. May include bone fragments and foreign bodies.
Diffuse Injury III (Swelling)	Cisterns compressed or absent with midline shift 0-5 mm; no high or mixed density lesion >25 cc.
Diffuse Injury IV	Midline shift >5 mm. No high or mixed density lesion >25 cc.
Evacuated mass	Any lesion surgically evacuated.
Non-evacuated mass lesion	High or mixed density lesion >25 cc, not surgically evacuated.

Clinical and radiological definition of severe TBI

Severe TBI (GCS <9) with cerebral edema was defined according to the CT findings, following Marshall's classification III and IV (Fig. 1) (Table 3).[19] Neurological deterioration was characterized as progressive increment in ICP, which was confirmed in some cases with an early ventriculostomy, with a fall in the GCS of more than 2 points, as well as with abnormal motor response, pupillary asymmetry or fixed and dilated pupils.

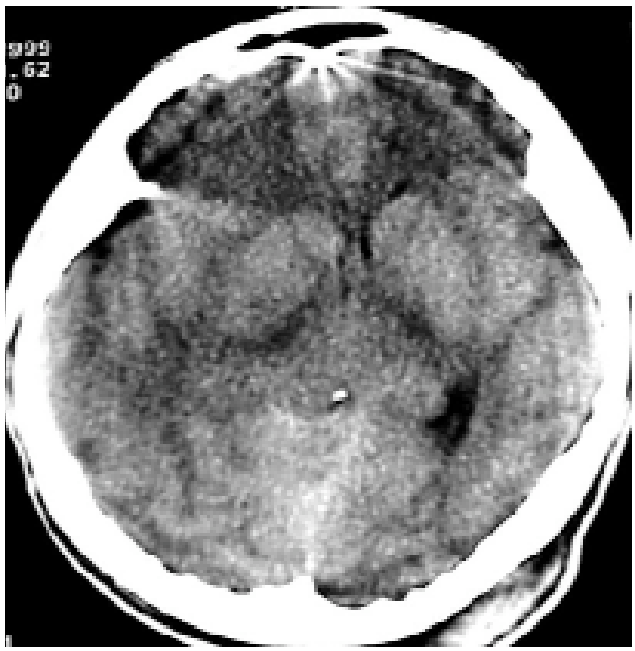

Fig. 1. Patient with compressed or absent cisterns with midline shift 0-5 mm; no high or mixed density lesion >25 cc (Marshall III). Diffuse swelling. (Photo: Author).

Matching control group

The control group was identified and matched according to the following preoperative criteria:

Age, gender, post-resuscitation pupillary response (unilateral, bilateral or non-pupillary dilatation; dilatation was considered if the size was more than 4 mm and was not reactive), GCS, SBP and heart rate (HR) after initial trauma room resuscitation (SaO_2 >90%, SBP >90 mmHg).

Outcome variables

The early DC group and control group were evaluated, and comparisons were made for ICU length of stay, total hospital length of stay, discharge status and GOS.

Statistical analyses

In order to account for the possible influence of GCS, pupils, SBP, Marshall score, age and gender, analysis of covariance models were used with GOS as the dependent variable and treatment effect (pre-versus post-2002) and the remaining variables as covariates. Due to the discreteness of the GOS response, the analysis was repeated with nonparametric rank regression technique to validate robustness of results (Table 4). All analyses were done with SAS Proc REG (SAS Institute Inc. 100 SAS Campus Dr; Cary, NC, USA).

To examine whether or not treatment groups were different from each other, we used the following

Table 4. Analysis of variance (ANOVA).•

Source	DF	Sum of squares	Mean square	F value	Pr > F
Model	7	47.39873	6.77125	6.93	<.0001
Error	28	27.35127	0.97683		
Corrected Total	35	74.75000			

•The SAS System. REG Procedure. Model 1: GOS=$\beta_0 + \beta_1$*treatment + β_2*GCS + β_3*pupil + β_4*HR + β_5*SBP + β_6*CT + β_7*age + ε [dependent variable: GOS (Glasgow Outcome Score)].

model: GOS = (β_0 + β_1*treatment + β_2*GCS + β_3*pupil + β_4*HR + β_5*SBP + β_6*CT + β_7*age + β_8*sex + ε) where, $\beta_0 \sim \beta_8$ were unknown parameters and $\varepsilon \sim N(0,\sigma^2)$. Treatment = 0 (if ventriculostomy) or 1 (if early DC), pupil = 1 (if bilateral), 2 (if unilateral), or 3 (if no dilatation) and sex = 1 (if male) or 2 (if female). According to the results of the model, we concluded that the sex variable was not significant, so we reduced the model to: GOS= (β_0 + β_1*treatment + β_2*GCS + β_3*pupil + β_4*HR + β_5*SBP + β_6*CT + β_7*age + ε).

RESULTS

Demographics

In the SBH, from the informal implementation of the guidelines in March 1999 to July 2004 (cut-off for this review), 524 patients were taken to the OR because of head trauma (Table 5). The most prevalent surgical indication was acute epidural hematoma evacuation in 139 patients (26.5%), followed by acute subdural hematoma evacuation in 104 (20%), correction of depressed skull fracture in 73 (14%), multiple lesion treatment in 70 (13.4%), chronic subdural hematoma evacuation in 60 (11.4%), treatment of gunshot wounds in 38 (7.3%), intracerebral hematoma evacuation in 20 (3.8%), treatment of skull thermal injury in 12 (2.3%), and treatment of newborn obstetrical trauma in 8 (1.3%) patients.

Of the total patient group, 204 (38.9% of the total operated) had GCS <9 (severe TBI). The most common intervention in the severe TBI group was ventriculostomy in 179 patients (88%). Of this subgroup of patients, 26 (14.5% of 179 patients) underwent some kind of cranial decompression surgery, but only 16 of them (9%) were operated according to the early DC protocol; timing of surgery was 3-10 hours (mean: 6.4 hours) (Table 6) (Fig. 2).

The baseline variables in each group were similar (Table 7). The mean age for the early DC group was 18.3 years compared with 24.3 years for the control group. The Revised Trauma Score (RTS) mean for both groups was 5.1. The mean of the post-resuscitation GCS was 4.5 for the early DC group and 4.4 for the control group. In the early DC group, 13 patients (81.2%) had a Marshall score of IV and 3 patients (18.8%) had a Marshall score of III in the CT findings. The Marshall score in the control group was IV in 17 patients (85%) and III in 3 patients (15%). Twelve patients (75%) in the early DC group were discharged alive and 4 patients (25%) died in the hospital. The mortality in the control group was 13 patients (65%); 7 patients (35%) were discharged alive.

Table 5. Distribution of 524 TBI patients brought to the operating room between March 1999 and July 2004 according to the surgical procedure

Surgical procedure	Patients	% of total patients
Epidural hematoma evacuation	139	26.5
Acute subdural hematoma evacuation	104	20
Treatment of depressed skull fracture	73	14
Treatment of multiple lesions*	70	13.4
Chronic subdural hematoma evacuation	60	11.4
Treatment of gunshot wound	38	7.3
Intracerebral hematoma evacuation	20	3.8
Treatment of thermal skull injury	12	2.3
Treatment of obstetrical trauma	8	1.3

* Multiple lesions are related to the finding of more than one injury type in the same patient (e.g. epidural + intracerebral hematoma, etc.) (Simon Bolivar Hospital, Neurosurgical Service. Patient database, 2004)

Table 6. Early DC group

No	Age (yrs)	Sex	PRP	PR SBP mmHg	PR HR bpm	CT Findings (Marshall)	PR GCS	ICU Days	In-Hospital Days	DS	GOS 6 M	DEC Type /Time(hrs)
1	23	M	U	110	75	3	8	5	10	L	5	U/3
2	40	F	B	140	56	4	4	17	35	L	2	B/6
3	45	M	U	125	60	4	4	5	5	D	1	U/5
4	20	F	B	100	58	4	4	6	6	D	1	B/10
5	1	M	U	105	126	4	8	7	19	L	5	U/6
6	15	F	N	129	53	4	4	9	21	L	4	U/9
7	1	M	B	120	99	4	4	7	7	D	1	U/9
8	2	F	U	115	121	4	4	9	25	L	5	U/5
9	9	M	U	130	64	3	4	7	21	L	4	U/4
10	20	F	B	143	54	4	4	6	6	D	1	B/6
11	25	F	U	150	50	3	4	15	57	L	3	B/6
12	24	F	B	140	60	4	4	20	43	L	3	B/9
13	5	M	U	122	78	4	4	7	29	L	5	U/7
14	21	F	B	156	63	4	4	12	39	L	2	U/6
15	8	M	U	138	68	4	4	7	21	L	5	U/6
16	34	F	B	140	64	4	4	12	31	L	3	B/6

PRP: Post-resuscitation pupils (U: Unilateral dilatation; B: Bilateral dilatation; N: No dilatation); PR SBP: Post-resuscitation systolic blood pressure (mmHg); PR HR: Post-resuscitation heart rate (beats per minute); CT: Computed tomography; PR GCS: Post-resuscitation Glasgow Coma Scale; ICU: Intensive care unit; DS: Discharge status; GOS: Glasgow Outcome Score; DEC: Decompression surgery (data from Simon Bolivar Hospital Medical Records Unit).

Outcomes

The GOS[20] was better in the early DC group than in the control group. In the early DC group, 7 of the 12 patients (43.7%) who were discharged alive had a GOS between 4 and 5 (minor deficits or disabled but independent), while none of the patients were in this range in the control group. Of the 7 living patients (35%) in the control group, all had a GOS between 2 and 3 (disabled, not independent or with minimal responsiveness). Baseline variables other than pupillary response and treatment were not significant in this model (Table 8). The mean GOS in the early DC

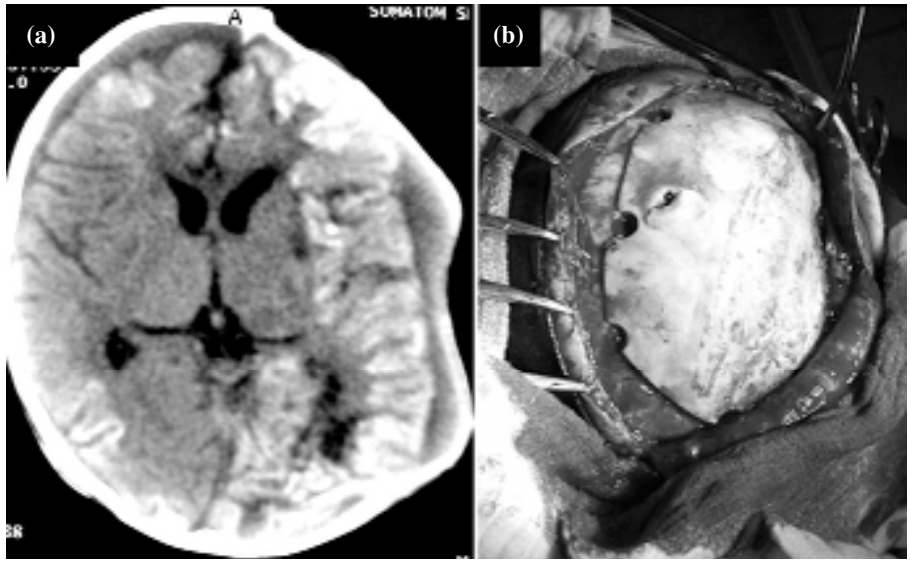

Fig. 2. Patient under early DC procedure. **(a)** Satisfactory evolution. MRI shows the skull defect and post-traumatic parenchyma changes. **(b)** Third phase of reconstruction and definitive close with the patient's osseous graft from bone bank. (Photo: Author).

Table 7. Ventriculostomy control group

No	Age (yrs)	Sex	PRP Pupils	PR SBP mmHg	PR HR bpm	CT Findings (Marshall)	PR GCS	ICU Days	In-Hospital Days	DS	GOS 6 M
1	36	M	U	140	67	4	4	3	3	D	1
2	41	M	U	153	80	3	4	6	6	D	1
3	21	F	B	127	64	4	5	2	2	D	1
4	16	M	N	120	87	4	4	6	6	D	1
5	15	F	U	135	90	4	4	13	27	L	2
6	34	M	B	130	54	4	4	3	3	D	1
7	7	M	B	110	64	4	4	2	2	D	1
8	35	F	U	127	87	3	8	7	14	L	3
9	9	M	N	100	89	4	4	6	12	L	3
10	15	F	B	140	62	4	4	4	4	D	1
11	34	F	B	130	76	4	4	2	2	D	1
12	43	M	N	143	77	4	4	10	23	L	2
13	19	M	U	120	87	4	4	9	9	D	1
14	4	M	U	99	100	4	4	8	17	L	3
15	21	M	B	137	70	4	4	4	4	D	1
16	30	M	U	140	66	4	4	2	2	D	1
17	7	M	N	100	90	4	4	11	31	L	3
18	24	F	U	120	58	4	4	12	26	L	2
19	31	M	N	141	80	3	7	7	7	D	1
20	44	M	B	129	75	4	4	2	2	D	1

PRP: Post-resuscitation pupils (U: Unilateral dilatation; B: Bilateral dilatation; N: No dilatation); PR SBP: Post-resuscitation systolic blood pressure (mmHg); PR HR: Post-resuscitation heart rate (beats per minute); CT: Computed tomography; PR GCS: Post-resuscitation Glasgow Coma Scale; ICU: Intensive care unit; DS: Discharge status; GOS: Glasgow Outcome Score (data from Simon Bolivar Hospital Medical Records Unit).

group was significantly higher than in the control group (p=0.0002, ANOVA analysis). The robustness of the result was verified using a rank regression analysis and the p value for the regression was 0.0008. The difference between mean GOS score for the early DC group and for the control group was estimated as 1.53 with a 95% confidence interval for the difference being (0.81-2.32) (Table 9).

DISCUSSION

According to the evidence, three key factors in neurosurgery have been identified as the causes of mortality, especially in the first 24 to 48 hours of the primary injury: hypoxia, hypotension and intracranial hypertension. The combination of these three factors has been recognized as a lethal combination.[21-27] The first and second factors are susceptible to prehospital management and stabilization, based on an organized emergency system, trained personnel and appropriate equipment adopted in the ambulances. However, the management of intracranial hypertension has been the critical factor, especially when considering trauma response racing against time.

Cerebral edema as a result of global and focal hypoperfusion processes and favored by ionic changes resulting from anaerobic cellular dysfunction has an important role in the increase of ICP, especially in the first 48 hours after primary injury.[28-31] This process has been appropriately determined in specialized TBI centers in North America and Europe with techniques like Xenon CT, $PtiO_2$, microdialysis, etc,[32-34] In Colombia, the access to this kind of technology is not feasible, especially in public health care institutions such as the SBH, which paradoxically, are the busiest trauma centers with the highest trauma patient volume, including low resource and indigent population groups.

Traditionally, patients with severe head injuries, without obvious surgical lesions and with significant cerebral edema (associated with midline shift and diminished basal cisterns), were managed with external ventriculostomy and transferred to the ICU for standard non-surgical management of intracranial hypertension (CSF drainage, sedation and paralysis, hyper osmolar solutions, barbiturates and hyperventilation or hypothermia). The mortality of this specific group of patients in our institution was

Table 8. Characteristics and variable averages of damage control group and control group

Variable	Early DC group	Control group
Mean age	18.3 y	24.3 y
Sex (M/F)	(7/11)	(14/6)
Post-Resuscitation GCS	4.5	4.4
Post-Resuscitation HR	71.8 bpm	76.1 bpm
Post-Resuscitation SBP	128.9 mmHg	127 mmHg
Marshall score (IV/III)	(13 / 3)	(17 / 3)
Mean ICU days	9.4 d	5.9 d
Mean In-Hospital days	23.4 d	10.1 d
Discharge status (Alive/Dead)	(12 / 4)	(7 / 13)
6-Month GOS (1/2/3/4/5)	(4/2/3/2/5)	(13/3/4/0/0)

M: Male; F: Female; GCS: Glasgow Coma Scale; HR: Heart rate; SBP: Systolic blood pressure; ICU: Intensive care unit; GOS: Glasgow Outcome Score.

high compared with the standard mortality of the Traumatic Coma Data Bank for the same Marshall group of patients (between 40% and 50%), even with all therapeutic interventions including brain monitoring measurements like Jv02, transcranial Doppler and the cerebral perfusion pressure (CPP) measurement.[35-37]

An alternative therapy emerged within management protocols based on scientific communications of specialized groups: decompressive craniectomy. Most studies made with DC before the 1980's showed poor results, having great methodological faults in their elaboration.[38-41] Between 1980 and 1990, studies that were published showed a new possibility for therapeutic intervention.[42-44] In the 1990's, classics studies like Polin's in 1997[16] and Welch Guerra's in 1999[15] allowed the creation of a methodological structure for the selection of patients who would probably benefit from the procedure. Since 2000, decompression has gained in importance. Subsequent studies by Munch in 2000[45] and Coplin in 2001[46] provided specifics on the safety and feasibility of craniectomy and duraplasty for elevated ICP management. Literature reviews by Berger, Ruf, Figaji, Hutchinson, Albanise, Jaeger, Kontopoulos, Ziai, Spagnolo, and Meier, etc, from 2002 to 2003, reported the possible benefits of the procedure and were demonstrated in specific patient populations and at specific times. Such reports also generated new questions, especially on the ethical issues, because of the important number of patient outcomes of permanent vegetative state after being submitted to emergency decompressions.[47-56] Between 2005 and 2006, there were several series showing the benefits of the procedure especially in the pediatric population. The early procedure was under consideration looking for a specific timing.[57-61] In the series reported here, we suggest that early decompression diminishes ICP and increases the volumetric capacity of expansion of the cranial vault.[62,63] Despite these encouraging findings, other studies have demonstrated that early craniectomy can increase the cerebral edema (increase the transmural gradient of hydrostatic pressure in the capil-

Table 9. Results of the ANOVA analysis for each independent variable

Variable	DF	Parameter estimate	Standard error	t value	Pr > |t|
Intercept	1	-0.07576	3.95726	-0.02	0.9849
Treatment	1	1.57130	0.36905	4.26	0.0002
GCS	1	0.23750	0.19224	1.24	0.2270
Pupil	1	0.64781	0.26390	2.45	0.0206
SBP	1	0.00004773	0.01453	0.00	0.9974
CT findings	1	-0.12298	0.59525	-0.21	0.8378
HR	1	0.00751	0.01269	0.59	0.5586
Age	1	-0.03106	0.01739	-1.79	0.0848

Pr > ItI = P value.

lary bed) and can induce infarcts with hemorrhagic transformation until cortical necrosis;[64] however, these findings were not present in our early DC population. The follow-up scans of the early DC group were more consistent with the new experimental studies that have shown different results with no edema expansion within the first 24 hours.[65] There is not enough evidence-based data in the literature at the present time to propose these interventions as the standard of care. There are several multicenter studies underway trying to answer these questions, including that of Bullock in the United States,[66] the Multicenter Cooperative Hispano-American study coordinated by the Vall d¨Hebron Hospital's neurotrauma group in Spain,[67] and the Rescue ICP group in Europe.[68]

Our experience, however, appears to indicate that in properly selected patients, a systematic approach (designated here as early DC), when instituted within the first hours after the traumatic event, had beneficial effects in our patients.

We have presented our experience with our early DC protocol and with a model that dates to 2002. Some aspects of it are different from what it is available in the literature today, but it has the same basic objective of "minimizing" the secondary brain injury through a methodical and standardized approach that rests on the three phases described above. Obviously, for it to become a reality, a neurosurgical trauma team has to be available 24 hours, 365 days a year, and synchronization between the emergency room, OR and the ICU is vitally important. We hope to continue with the evaluation of this procedure and wait for the results of studies of the scientific international associations.

In conclusion, the systematic approach of DC in neurotrauma patients can be applicable early in patients with severe TBI. Early application of this DC protocol within less than 12 hours from injury in young patients with a GCS <9, a Marshall CT finding between III or IV, and isolated TBI was associated with significantly less mortality than the conventional approach with ventriculostomy and ICU management in the SBH population. Hemispheric cranial decompression in patients with severe head injury, who otherwise may not have been previously considered as surgical candidates, may turn out to be a better alternative management when compared with simple ventriculostomy and medical therapy in the ICU. The basic principle relies on prompt intervention aimed at early control of elevated ICP. The ethical dilemma remains, as there may be a number of patients with poor functional outcomes. Further evaluation of quality of life and long-term results will be necessary to understand the full extent of such interventions.

REFERENCES

1. The Brain Trauma Foundation. The American Association of Neurological Surgeons. The Joint Section on Neurotrauma and Critical Care. Trauma systems. J Neurotrauma 2000;17:457-62.
2. Guidelines for the management of severe head injury. Introduction. J Neurotrauma 1996;13:643-5.
3. Brain Trauma Foundation: Guidelines for surgical management of traumatic brain injury. BTF (New York), Neurosurgery 2006;58:S2-S120.
4. Gabriel EJ, Ghajar J, Jagoda A, Pons PT, Scalea T, Walters BC; Brain Trauma Foundation. Guidelines for prehospital management of traumatic brain injury. J Neurotrauma 2002;19:111-74.
5. Brain Trauma Foundation, Society of Critical Care Medicine, American Association of Neurological Surgeons, Join Sections of Pediatrics and Neurotrauma, American Academy of Pediatrics, World Federation of Pediatric Intensive and Critical Care Societies, American College of Emergency Physicians, Congress of Neurological Surgeons: Guidelines for the acute medical management of severe traumatic brain injury in infants, children, and adolescents. Pediatr Crit Care Med 2003;4:1-72.
6. European Brain Injury Consortium: Guidelines for Management of Severe Head Injury in Adults. Acta Neurochir (Wien) 1997;139:286-94.
7. Paredes Zapata GD. Terrorism in Colombia. Prehosp Disaster Med 2003;18:80-7.
8. Hesdorffer DC, Ghajar J, Iacono L. Predictors of compliance with the evidence-based guidelines for traumatic brain injury care: a survey of United States trauma centers. J Trauma 2002;52:1202-9.
9. Murray GD, Teasdale GM, Braakman R, Cohadon F, Dearden M, Iannotti F, et al. The European Brain Injury Consortium survey of head injuries. Acta Neurochir (Wien) 1999;141:223-36.
10. Palmer S, Bader MK, Qureshi A, Palmer J, Shaver T, Borzatta M, et al. The impact on outcomes in a community hospital setting of using the AANS traumatic brain injury guidelines. Americans Associations for Neurologic Surgeons. J Trauma 2001;50:657-64.
11. Vukic M, Negovetic L, Kovac D, Ghajar J, Glavic Z, Gopcevic A. The effect of implementation of guidelines for the management of severe head injury on patient treatment and outcome. Acta Neurochir (Wien) 1999;141:1203-8.
12. Rubiano A. Surgical Management of Head Trauma in Simon Bolivar Hospital. Neurological Surgery Program Reviews. El Bosque University (Bogotá), 1-80. 2004.
13. Alexander E, Ball MR, Laster DW. Subtemporal decompression: radiological observations and current surgical experi-

ence. Br J Neurosurg 1987;1:427-33.
14. Gaab MR, Rittierodt M, Lorenz M, Heissler HE. Traumatic brain swelling and operative decompression: a prospective investigation. Acta Neurochir Suppl (Wien) 1990;51:326-8.
15. Guerra WK, Gaab MR, Dietz H, Mueller JU, Piek J, Fritsch MJ. Surgical decompression for traumatic brain swelling: indications and results. J Neurosurg 1999;90:187-96.
16. Polin RS, Shaffrey ME, Bogaev CA, Tisdale N, Germanson T, Bocchicchio B, et al. Decompressive bifrontal craniectomy in the treatment of severe refractory posttraumatic cerebral edema. Neurosurgery 1997;41:84-94.
17. Chesnut RM, Ghajar J, Maas AIR, Marion DW, Servadei F, et al. Early indicators of prognosis in severe traumatic brain injury. J Neurotrauma 2000;17:614-9.
18. Stocchetti N, Croci M, Spagnoli D, Gilardoni F, Resta F, Colombo A. Mass volume measurement in severe head injury: accuracy and feasibility of two pragmatic methods. J Neurol Neurosurg Psychiatry 2000;68:14-7.
19. Marshall L, Gautille T, Klauver M, et al. A new classification of head injury based on computerized tomography. J Neurosurg 1991;75:s28-s35.
20. Jennett B, Bond M. Assessment of outcome after severe brain damage. Lancet 1975;1(7905):480-4.
21. Andrews PJ, Piper IR, Dearden NM, Miller JD. Secondary insults during intrahospital transport of head-injured patients. Lancet 1990;335(8685):327-30.
22. Chesnut RM. Avoidance of hypotension: conditio sine qua non of successful severe head-injury management. J Trauma 1997;42(5 Suppl):S4-9.
23. Chesnut RM, Marshall LF, Klauber MR, Blunt BA, Baldwin N, Eisenberg HM, et al. The role of secondary brain injury in determining outcome from severe head injury. J Trauma 1993;34:216-22.
24. Chesnut RM, Marshall SB, Piek J, Blunt BA, Klauber MR, Marshall LF. Early and late systemic hypotension as a frequent and fundamental source of cerebral ischemia following severe brain injury in the Traumatic Coma Data Bank. Acta Neurochir Suppl (Wien) 1993;59:121-5.
25. Jeremitsky E, Omert L, Dunham CM, Protetch J, Rodriguez A. Harbingers of poor outcome the day after severe brain injury: hypothermia, hypoxia, and hypoperfusion. J Trauma 2003;54:312-9.
26. Marmarou A, Anderson R, Ward J, et al. Impact of ICP instability and hypotension on outcome in patients with severe head trauma. J Neurosurg 1991;75:s59-s66.
27. Wald SL, Shackford SR, Fenwick J. The effect of secondary insults on mortality and long-term disability after severe head injury in a rural region without a trauma system. J Trauma 1993;34:377-81.
28. Hlatky R, Valadka AB, Robertson CS. Intracranial hypertension and cerebral ischemia after severe traumatic brain injury. Neurosurg Focus 2003;14(4):e2.
29. Marion DW, Darby J, Yonas H. Acute regional cerebral blood flow changes caused by severe head injuries. J Neurosurg 1991;74:407-14.
30. Ray SK, Dixon CE, Banik NL. Molecular mechanisms in the pathogenesis of traumatic brain injury. Histol Histopathol 2002;17:1137-52.
31. Xi G, Keep RF, Hoff JT. Pathophysiology of brain edema formation. Neurosurg Clin N Am 2002;13:371-83.
32. Bouma GJ, Muizelaar JP, Stringer WA, Choi SC, Fatouros P, Young HF. Ultra-early evaluation of regional cerebral blood flow in severely head-injured patients using xenon-enhanced computerized tomography. J Neurosurg 1992;77:360-8.
33. Haitsma IK, Maas AI. Advanced monitoring in the intensive care unit: brain tissue oxygen tension. Curr Opin Crit Care 2002;8:115-20.
34. Johnston AJ, Gupta AK. Advanced monitoring in the neurology intensive care unit: microdialysis. Curr Opin Crit Care 2002;8:121-7.
35. Cormio M, Valadka AB, Robertson CS. Elevated jugular venous oxygen saturation after severe head injury. J Neurosurg 1999;90:9-15.
36. Rosner MJ, Rosner SD, Johnson AH. Cerebral perfusion pressure: management protocol and clinical results. J Neurosurg 1995;83:949-62.
37. van Santbrink H, Schouten JW, Steyerberg EW, Avezaat CJ, Maas AI. Serial transcranial Doppler measurements in traumatic brain injury with special focus on the early posttraumatic period. Acta Neurochir (Wien) 2002;144:1141-9.
38. Clark K, Nash TM, Hutchison GC. The failure of circumferential craniotomy in acute traumatic cerebral swelling. J Neurosurg 1968;29:367-71.
39. Cooper PR, Hagler H, Clark WK, Barnett P. Enhancement of experimental cerebral edema after decompressive craniectomy: implications for the management of severe head injuries. Neurosurgery 1979;4:296-300.
40. Kerr FW. Radical decompression and dural grafting in severe cerebral edema. Mayo Clin Proc 1968;43:852-64.
41. Venes JL, Collins WF. Bifrontal decompressive craniectomy in the management of head trauma. J Neurosurg 1975;42:429-33.
42. Crone KR, Kelly DL Jr. Subtemporal decompression in the management of refractory intracranial hypertension in severe closed head injury. Neurosurgery 1985;16:726-8.
43. Gower DJ, Lee KS, McWhorter JM. Role of subtemporal decompression in severe closed head injury. Neurosurgery 1988;23:417-22.
44. Karlen J, Stula D. Decompressive craniotomy in severe craniocerebral trauma following unsuccessful treatment with barbiturates. [Article in German] Neurochirurgia (Stuttg) 1987;30:35-9.
45. Münch E, Horn P, Schürer L, Piepgras A, Paul T, Schmiedek P. Management of severe traumatic brain injury by decompressive craniectomy. Neurosurgery 2000;47:315-23.
46. Coplin WM, Cullen NK, Policherla PN, Vinas FC, Wilseck JM, Zafonte RD, et al. Safety and feasibility of craniectomy with duraplasty as the initial surgical intervention for severe traumatic brain injury. J Trauma 2001;50:1050-9.
47. Albanèse J, Leone M, Alliez JR, Kaya JM, Antonini F, Alliez B, et al. Decompressive craniectomy for severe traumatic brain injury: Evaluation of the effects at one year. Crit Care Med 2003;31:2535-8.
48. Berger S, Schwarz M, Huth R. Hypertonic saline solution and decompressive craniectomy for treatment of intracranial hypertension in pediatric severe traumatic brain injury. J Trauma 2002;53:558-63.
49. Figaji AA, Fieggen AG, Peter JC. Early decompressive craniotomy in children with severe traumatic brain injury. Childs Nerv Syst 2003;19:666-73.

50. Hutchinson PJ, Kirkpatrick PJ. Decompressive craniectomy in head injury. Curr Opin Crit Care 2004;10:101-4.
51. Jaeger M, Soehle M, Meixensberger J. Effects of decompressive craniectomy on brain tissue oxygen in patients with intracranial hypertension. J Neurol Neurosurg Psychiatry 2003;74:513-5.
52. Kontopoulos V, Foroglou N, Patsalas J, Magras J, Foroglou G, Yiannakou-Pephtoulidou M, et al. Decompressive craniectomy for the management of patients with refractory hypertension: should it be reconsidered? Acta Neurochir (Wien) 2002;144:791-6.
53. Meier U, Gräwe A, König A. The importance of major extracranial injuries by the decompressive craniectomy in severe head injuries. Acta Neurochir Suppl 2005;95:55-7.
54. Ruf B, Heckmann M, Schroth I, Hügens-Penzel M, Reiss I, Borkhardt A, et al. Early decompressive craniectomy and duraplasty for refractory intracranial hypertension in children: results of a pilot study. Crit Care 2003;7:R133-8.
55. Spagnuolo E, Costa G, Calvo A, Johnston E, Tarigo A. Descompresive craniectomy in head injury. Intractable I.C.P. [Article in Spanish] Neurocirugia (Astur) 2004;15:36-42.
56. Ziai WC, Port JD, Cowan JA, Garonzik IM, Bhardwaj A, Rigamonti D. Decompressive craniectomy for intractable cerebral edema: experience of a single center. J Neurosurg Anesthesiol 2003;15:25-32.
57. Josan VA, Sgouros S. Early decompressive craniectomy may be effective in the treatment of refractory intracranial hypertension after traumatic brain injury. hilds Nerv Syst 2006;22:1268-74.
58. Reithmeier T, Speder B, Pakos P, Brinker G, Löhr M, Klug N, Ernestus RI. Delayed bilateral craniectomy for treatment of traumatic brain swelling in children: case report and review of the literature. Childs Nerv Syst 2005;21:249-53.
59. Jagannathan J, Okonkwo DO, Dumont AS, Ahmed H, Bahari A, Prevedello DM, et al. Outcome following decompressive craniectomy in children with severe traumatic brain injury: a 10-year single-center experience with long-term follow up. J Neurosurg 2007;106(4 Suppl):268-75.
60. Figaji AA, Fieggen AG, Argent A, Peter JC. Surgical treatment for “brain compartment syndrome” in children with severe head injury. S Afr Med J 2006;96(9 Pt 2):969-75.
61. Kan P, Amini A, Hansen K, White GL Jr, Brockmeyer DL, Walker ML, et al. Outcomes after decompressive craniectomy for severe traumatic brain injury in children. J Neurosurg 2006;105(5 Suppl):337-42.
62. Burkert W, Plaumann H. The value of large pressure-relieving trepanation in treatment of refractory brain edema. Animal experiment studies, initial clinical results. [Article in German] Zentralbl Neurochir 1989;50:106-8.
63. Hatashita S, Hoff JT. The effect of craniectomy on the biomechanics of normal brain. J Neurosurg 1987;67:573-8.
64. Moody RA, Ruamsuke S, Mullan SF. An evaluation of decompression in experimental head injury. J Neurosurg 1968;29:586-90.
65. Zweckberger K, Erös C, Zimmermann R, Kim SW, Engel D, Plesnila N. Effect of early and delayed decompressive craniectomy on secondary brain damage after controlled cortical impact in mice. J Neurotrauma 2006;23:1083-93.
66. Bullock R. Management of brain injury by decompressive craniectomy (Comment). Neurosurgery 2000;47:322-3.
67. Ibanez J. Tienen alguna indicacion las craniectomias descompresivas en el tratamiento de la hipertension endocraneana refractaria? Presentacion de un estudio multicentrico multinacional sobre la eficacia de las craniectomias descompresivas en las lesiones difusas tipo III y IV del Traumatic Coma Data Bank. PIC 2000. 2000;1:179-93.
68. Compagnone C, Murray GD, Teasdale GM, Maas AI, Esposito D, Princi P, et al. The management of patients with intradural post-traumatic mass lesions: a multicenter survey of current approaches to surgical management in 729 patients coordinated by the European Brain Injury Consortium. Neurosurgery 2005;57:1183-92.