



## Reconstruction of complex groin defects with inferior epigastric artery-based rectus abdominis muscle flaps: report of two cases

Kompleks inguinal defektlerin inferior epigastrik arterden kanlanan rektus abdominis kas flepleri ile rekonstrüksiyonu: İki olgu sunumu

Samet Vasfi KUVAT,<sup>1,3</sup> Hakan YANAR,<sup>2</sup> Ahmet BİÇER,<sup>3</sup> Serdar TUNÇER,<sup>4</sup>  
Burhan ÖZALP,<sup>3</sup> Murat TOPALAN<sup>3</sup>

Because the extremities are dependent on a single vascular supply, namely the brachial and femoral arteries, injuries around the girdles are challenging, and may contribute to high morbidity rates such as extremity loss, or even mortality due to bleeding, sepsis or vascular compromise. The reconstruction or aided closure of these regions may present additional technical difficulties in the presence of a vascular injury that complicates the use of a microvascular-free transfer, which sometimes may be needed to cover the exposed vessels, bones, tendons, and cartilages whenever the neighboring skin and subcutaneous tissue are inadequate or demised. In these circumstances, pedicled regional flaps of muscular or musculocutaneous consistency (especially if a bulk or rich vascular tissue is needed) would be an alternative. In this report, we present two cases that underwent femoral artery repair via saphenous vein grafting in the vascular surgery clinic followed by our inferiorly based pedicled rectus abdominis muscle flap coverage procedure.

**Key Words:** Groin defect; rectus abdominis muscle flap; vascular injury.

Brakiyal ve femoral arterler gibi tek vasküler kaynağı olan ekstremitelerin damar ve çevresi yaralanmalarında, ekstremitte kaybı gibi morbidite ya da kanama, sepsis ve vasküler uyumsuzluğa bağlı mortalite riski yüksektir. Ekspozite damar, kemik, tendon ve kırıkdağları kapatacak komşu deri ve subkütan doku yetersizliği durumunda, bu bölgele- rin rekonstrüksiyonunda ihtiyaç duyulabilen serbest mikrovasküler doku transferi, vasküler yaralanma sebebi ile beraberinde ek teknik zorlukları da ortaya çıkarabilir. Bu koşullarda, pediküllü kas ve kas-deri flebi gibi reyonel flepler (özellikle dolaşımı iyi hacimli dokuya ihtiyaç varsa) alternatif olabilir. Bu yazıda, vasküler cerrahi kliniğince safen ven grefti ile femoral arter onarımı sonrası inferi- ora baze pediküllü rektus abdominis kası ile rekonstrüksiyon uyguladığımız iki olgu sunuldu.

**Anahtar Sözcükler:** İnguinal defekt; rektus abdominis kas flebi; vasküler yaralanma.

The last decades have witnessed a gain in popularity of the concept "limb salvage surgery", especially concerning trauma or oncologic surgery. Providing reliable soft tissue coverage to the girdle regions can be considered to be a limb salvage reconstructive surgery.<sup>[1]</sup> Wound healing in the groin region is somehow defective owing to a thin and relatively avascular soft tissue coverage.<sup>[2]</sup> Moreover, complications like wound infection and wound dehiscence are often encountered following

primary closure of defects in this region.<sup>[1,3]</sup> When all these factors are taken into account, reconstruction confined to these regions may need pedicled or free muscle flaps, which provide adequate blood supply.<sup>[1]</sup>

Inferiorly based rectus abdominis muscle/muscle-skin (RAMs) flaps are among the valid emerging alternatives in reconstruction of inguinal region soft tissue defects. Adequate soft tissue volume, wide arc

<sup>1</sup>Department of Plastic and Reconstructive Surgery, Istanbul Training and Research Hospital, Istanbul; Departments of <sup>2</sup>Surgery, <sup>3</sup>Plastic and Reconstructive Surgery, Istanbul University Istanbul Faculty of Medicine, Istanbul; <sup>4</sup>Department of Plastic and Reconstructive Surgery, Bilim University Faculty of Medicine, Istanbul, Turkey.

<sup>1</sup>Istanbul Eğitim ve Araştırma Hastanesi, Plastik, Rekonstrüktif ve Cerrahi Kliniği, İstanbul; <sup>2</sup>İÜ İstanbul Tıp Fakültesi, Genel Cerrahi Anabilim Dalı,

<sup>3</sup>Plastik, Rekonstrüktif ve Cerrahi Anabilim Dalı, İstanbul;

<sup>4</sup>Bilim Üniversitesi, Tıp Fakültesi, Plastik, Rekonstrüktif ve Cerrahi Anabilim Dalı, İstanbul.

rotation, no repositioning required during surgery, and relatively rapid and straightforward flap harvesting render these flaps advantageous.<sup>[1-3]</sup>

Two cases that underwent vascular repair in the femoral region followed by our inferiorly based pedicled RAM flap coverage procedure are presented herein.

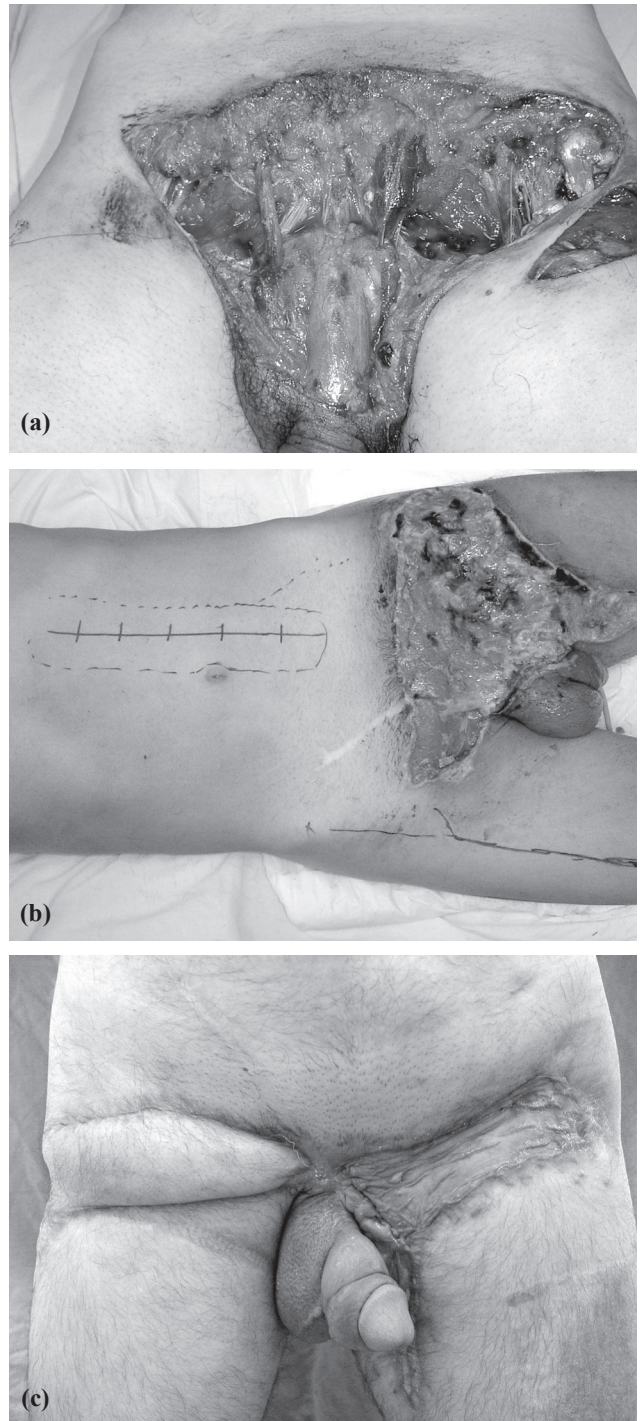
### CASE REPORTS

**Surgical anatomy:** The RAM is nourished by the inferior epigastric artery, which is a branch of the external iliac artery, and the superior epigastric artery, which is the continuity of internal thoracic artery. The RAM/musculocutaneous flap based on its superior pedicle is commonly used to close defects of the superior and anterior thoracic wall, whereas defects of the inferior abdominal wall and the inguinal region are covered by the same muscle based on its inferior pedicle.<sup>[2,4]</sup>

**Case 1-** A 45-year-old male presented to our emergency department following an occupational injury. Physical examination revealed a complex crush injury in the suprapubic and both inguinal regions with bilateral femoral artery and vein disruption. The right femoral artery was repaired with a reversed great saphenous vein graft interposition, whereas the left was repaired using the ipsilateral superficial femoral vein as a graft. The demised, degloved skin was primarily closed. On the 3rd postoperative day, the infected and necrotized skin due to the type of injury and subsequent contamination was debrided. The radical debridement resulted in exposition of both vascular repairs. This necessitated extensive closure of the defects. A pedicled tensor fascia lata (TFL) musculofasciocutaneous flap for the fairly smaller right-side defect and an inferiorly pedicled RAM flap for the generously larger left-side defect were planned.

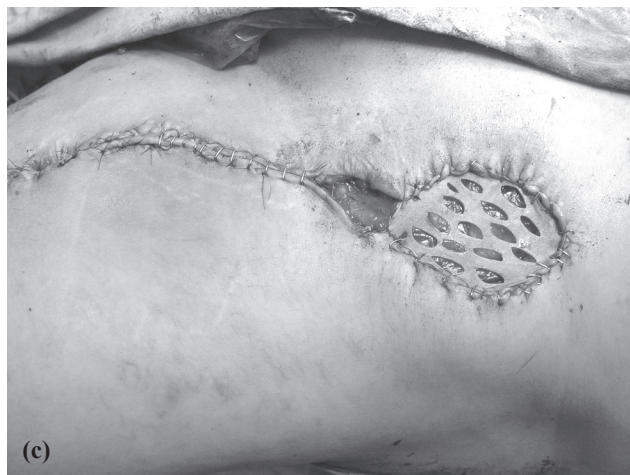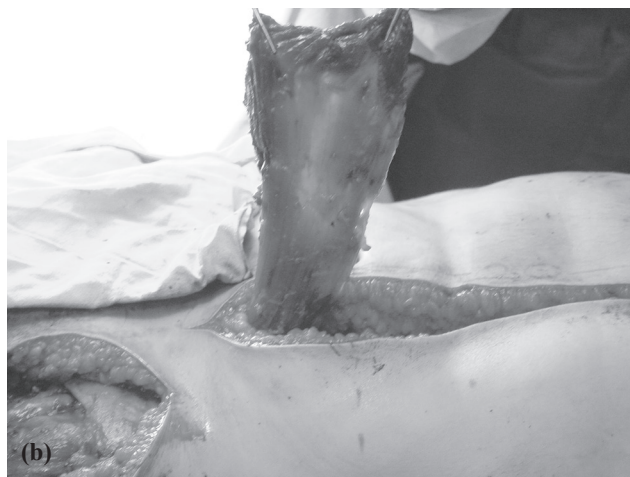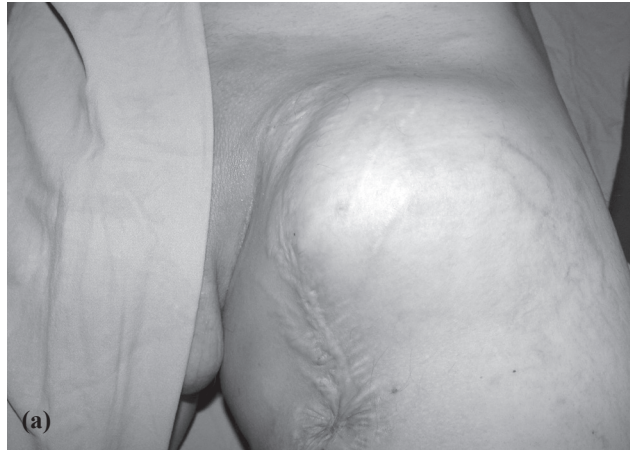**Surgical technique:** The rectus sheath was opened on its lateral border using a paramedian anterior abdominal incision. The deep inferior epigastric artery was identified while the rectus muscle was being dissected from its sheath beneath the arcuate line. After dividing the superior epigastric artery and separation of the superior portion from its insertions, the muscle was transposed upon the wound inferiorly. The divided anterior rectus sheath was repaired with nonabsorbable sutures in the donor site in an effort to minimize any resultant weakness around the anterior abdomen consequently. The portion of the defect outstretching the right inguinal region where the defect was comparably smaller was repaired with a 15x8 cm TFL musculocutaneous flap. The rectus muscle was left bare on the wound to exclude any possible skin graft failure due to the past skin infection. The open wound was treated with local wound care for seven

days, after which it had been confirmed that the local infection was under control; a split thickness skin graft was used to ensure skin protection. Total healing of the skin was observed following a three-week period of local wound care postoperatively, after which the patient was discharged (Fig. 1).



**Fig. 1.** (a) Complex inguinal and suprapubic defect in a patient with bilateral femoral vascular repair. (b) Design of RAM and TFL flaps. (c) Long-term results of left-sided RAM and right-sided TFL musculocutaneous flap coverage.

**Case 2-** A 26-year-old male patient was admitted to our general surgery clinic with a palpable soft tissue mass in his left thigh region. The biopsy was reported as soft tissue sarcoma, after which a wide resection of the tumor was performed subsequently after a neo-adjuvant treatment protocol. In the clinical and radio-



**Fig. 2.** (a) Recurrent sarcoma in the left inguinal region. (b) Inferiorly based RAM flap, being prepared to address the dead space. (c) The definitive repair is made with a split thickness skin graft overlying the muscle flap transposed to the defect, perioperative view.

logical follow-ups, a relapse with an invasion of the femoral artery and vein was seen. A surgical therapy was planned, which included a wide resection, followed by resection of the femoral artery and vein 15 cm along its course down the inguinal ligament, and revascularization with a 20 cm graft obtained from the great saphenous vein. In order to address the vast dead space occurring after the oncologic resection and to cover the exposed femoral vascular repair with an abundant soft tissue mass, an inferiorly based RAM flap was planned.

**Surgical technique:** A left paramedian abdominal incision was made to expose the rectus muscle and its sheath. After visualization of its inferior pedicle, the muscle was harvested with sharp and blunt dissections along its borders. The inguinal ligament was divided and a subcutaneous tunnel was formed through which the muscle was propelled. The exposed vascular graft was conveniently covered with this flap. The paramedian incisions and the inguinal region were closed primarily, while the skin coverage of the muscle was done by a split thickness skin graft harvested from the contralateral anterolateral thigh (Fig. 2).

## DISCUSSION

Surgical infections following vascular surgery around the inguinal region, particularly if some sort of prosthetic graft is used, may result in arterial occlusion or emboli leading to drastic consequences such as extremity loss.<sup>[3,5,6]</sup> Therefore, complex inguinal defects with an underlying vascular surgery should be addressed promptly and radically by flaps with adequate vascularity and volume.<sup>[3]</sup> In order to obtain vascularity and volume, a pedicled or a free muscle flap can be chosen. With regards to complications, these options were found to be comparable.<sup>[1,7]</sup> However, because of the scarcity of recipient vessels, free flaps are generally not preferred for this region.<sup>[3]</sup>

Other viable alternative flaps for the inguinal region include TFL,<sup>[3,8]</sup> gracilis,<sup>[3,5]</sup> sartorius,<sup>[3,9]</sup> rectus femoris,<sup>[3,10]</sup> gluteus medius, and vastus lateralis<sup>[2]</sup> regional muscle flaps.<sup>[3]</sup> However, adequate tissue volume needed for a viable reconstruction in this region may not be obtained with these options.<sup>[3]</sup> Another shortcoming of these flaps is their relatively short arc of rotation.<sup>[2]</sup> One of the most viable alternatives for the region is, therefore, a RAM flap with its abundant vascularity, more than adequate volume, and an arc of rotation long enough to ensure a tension-free closure.<sup>[1]</sup>

A RAM flap harvested in an inferiorly based fashion, which depends on the inferior epigastric artery, may be used to address defects in the chest wall and lower abdominal, femoral,<sup>[11]</sup> vaginal,<sup>[12,13]</sup> penile,<sup>[11]</sup> ischial-trochanteric,<sup>[4]</sup> pelvic,<sup>[1,14]</sup> and sacral<sup>[15]</sup> regions. An inferiorly based RAM flap can either be harvested

as a muscular unit only or with a skin paddle that may be planned as extended, oblique or vertical at the anterior abdomen.<sup>[1,16]</sup> In our first case, the skin defect was too large to be covered with a skin island. Additionally, the defect was horizontal so as to extend to the suprapubic region. Our primary goal was to address the dead space in our second case so a skin component was not regarded necessary.

The relative contraindications for choosing a RAM flap include previous injury to the abdomen with obscure history of depth, inferior epigastric artery ligation, obesity (fat necrosis), or presence of a median or paramedian extensive scar in the abdomen.<sup>[11,15]</sup> Potential donor site morbidities include anterior abdominal wall weakness (bulge) or herniations. Herniation can be possibly eliminated by tight closure of the rectus sheath either with a mesh or nonabsorbable sutures.<sup>[15]</sup> The motive behind using a TFL graft for the opposite side in Case 1 was to prevent further abdominal weakness by using the rectus muscle bilaterally. On the other hand, the right-sided defect was small enough to let us conveniently use the TFL flap in spite of its weak arc of rotation.

Defects in the inguinal region are to be assessed promptly, preferably immediately with generation of the defect, as Parrett et al.<sup>[1]</sup> reported marked differences with regards to complications using delayed versus immediate reconstructions (47% and 9.4%, respectively). In our first case, the delayed reconstruction was planned in order to observe the ultimate extent of soft tissue loss caused by the crush injury. It is often difficult to assess the total damage following a crush injury before it manifests later with a necrosis demarcation line. In any case, it is imperative to intervene immediately since, as a general rule, signs of necrosis and infection are settled following these types of injuries.

In conclusion, complex inguinal region defects with subsequent vascular surgery can be reliably and effectively addressed with an inferiorly based rectus abdominal muscle/musculocutaneous flap.

## REFERENCES

1. Parrett BM, Winograd JM, Garfein ES, Lee WP, Homicek FJ, Austen WG Jr. The vertical and extended rectus abdominis myocutaneous flap for irradiated thigh and groin defects. *Plast Reconstr Surg* 2008;122:171-7.
2. Ikeda K, Matsuda M, Yamauchi D, Tomita K. Infection of the inguinal region treated by musculocutaneous flaps. *J Orthop Surg (Hong Kong)* 2001;9:51-56.
3. Qi F, Zhang Y, Gu J. Repairs of complex groin wounds with contralateral rectus abdominis myocutaneous flaps. *Microsurgery* 2009;29:199-204.
4. Kierney PC, Cardenas DD, Engrav LH, Grant JH, Rand RP. Limb-salvage in reconstruction of recalcitrant pressure sores using the inferiorly based rectus abdominis myocutaneous flap. *Plast Reconstr Surg* 1998;102:111-6.
5. Morasch MD, Sam AD 2nd, Kibbe MR, Hijawi J, Dumanian GA. Early results with use of gracilis muscle flap coverage of infected groin wounds after vascular surgery. *J Vasc Surg* 2004;39:1277-83.
6. Chao A, Lai CH, Chen HC, Hsieh HC, Yeow KM. Limb preservation by Gore-Tex vascular graft for groin recurrence after postoperative adjuvant radiation in vulvar cancer. *Gynecol Oncol* 2001;82:559-62.
7. Hoy E, Granick M, Benevenia J, Patterson F, Datiashvili R, Bille B. Reconstruction of musculoskeletal defects following oncologic resection in 76 patients. *Ann Plast Surg* 2006;57(2):190-4.
8. Illig KA, Alkon JE, Smith A, Rhodes JM, Keefer A, Doyle A, et al. Rotational muscle flap closure for acute groin wound infections following vascular surgery. *Ann Vasc Surg* 2004;18:661-8.
9. Perez-Burkhardt JL, Gonzalez-Fajardo JA, Carpintero LA, Mateo AM. Sartorius myoplasty for the treatment of infected groins with vascular grafts. *J Cardiovasc Surg (Torino)* 1995;36:581-5.
10. Alkon JD, Smith A, Losee JE, Illig KA, Green RM, Serletti JM. Management of complex groin wounds: preferred use of the rectus femoris muscle flap. *Plast Reconstr Surg* 2005;115:776-85.
11. Kayes OJ, Durrant CA, Ralph D, Floyd D, Withey S, Minhas S. Vertical rectus abdominis flap reconstruction in patients with advanced penile squamous cell carcinoma. *BJU Int* 2007;99:37-40.
12. Sevin BU, Abendstein B, Oldenburg WA, O'Connor M, Waldorf J, Klingler JP, et al. Limb sparing surgery for vulvar groin recurrence: a case report and review of the literature. *Int J Gynecol Cancer* 2001;11:32-8.
13. Weiwei L, Zhifei L, Ang Z, Lin Z, Dan L, Qun Q. Vaginal reconstruction with the muscle-sparing vertical rectus abdominis myocutaneous flap. *J Plast Reconstr Aesthet Surg* 2009;62:335-40.
14. Tobin GR, Day TG. Vaginal and pelvic reconstruction with distally based rectus abdominis myocutaneous flaps. *Plast Reconstr Surg* 1988;81:62-73.
15. Cheong YW, Sulaiman WA, Halim AS. Reconstruction of large sacral defects following tumour resection: a report of two cases. *J Orthop Surg (Hong Kong)* 2008;16:351-4.
16. Taylor GI, Corlett R, Boyd JB. The extended deep inferior epigastric flap: a clinical technique. *Plast Reconstr Surg* 1983;72:751-65.