

# Comparison of clinical outcomes with three different intramedullary nailing devices in the treatment of unstable trochanteric fractures

Sinan Zehir, M.D.,<sup>1</sup> Ercan Şahin, M.D.,<sup>2</sup> Regayip Zehir, M.D.<sup>3</sup>

<sup>1</sup>Department of Orthopedics and Traumatology, Hitit University Faculty of Medicine, Çorum

<sup>2</sup>Department of Orthopedics and Traumatology, Bülent Ecevit University Faculty of Medicine, Zonguldak

<sup>3</sup>Department of Cardiology, Carsamba State Hospital, Samsun

## ABSTRACT

**BACKGROUND:** The aim of this study was to report our experience regarding the use of three different methods for intramedullary nailing in the treatment of intertrochanteric fractures.

**METHODS:** Patients with A2 and A3 type fractures operated on for unstable trochanteric fractures were included into this retrospective cohort study. Patients were divided into three groups based on the technique used; Talon distal fix nail/lag screw (n=78; mean age, 78.5±6.6), PFNA nail (n=96; mean age, 77.2±6.8) or InterTan nails (n=102; mean age, 76.8±6.7). Harris hip scores were recorded at the last outpatient visit and survival information was obtained by phone interview and civil registry database.

**RESULTS:** Baseline characteristics were similar among groups. Operation time, fluoroscopy time and blood loss were significantly higher in InterTan group. Screw cut-out occurred in eight patients in PFNA group. In-hospital mortality occurred in nine (3.2%) patients. Length of hospital stay and postoperative tip-apex distance was not different among groups. At follow-up, healing time and Harris hip scores were also similar among groups. One-year survival rate was 83.1±4.5% in Talon distal fix nail/lag screw, 84.0±3.8% in PFNA group and 84.4±3.7% in InterTan group (p=0.33).

**CONCLUSION:** New Talon distal fix nail/lag screw was associated with lower cut-out rates than PFNA and shorter operative times than InterTan. Further study is warranted to clearly establish the potential advantages of Talon distal fix over any other technique described herein.

**Key words:** Complications; intramedullary nailing; survival; trochanteric fractures.

## INTRODUCTION

Hip fractures constitute a major health problem in the elderly, and their incidence is increasing as the population worldwide continues to age.<sup>[1]</sup> Fractures of the intertrochanteric region and femoral neck account for a great majority of hip fractures and, particularly in females, the proportion of intertrochanteric fractures have been reported to rise with advancing age.

<sup>[2]</sup> Patients with trochanteric fractures tend to have a thinner cortical bone of the femur and have more severe osteoporosis than those having femoral neck fractures.<sup>[3]</sup> Moreover, presence of a trochanteric fracture was further shown to be associated with higher mortality after hip fracture.<sup>[5]</sup>

Surgery is the mainstay of treatment in fractures of the trochanteric region, and operation should be undertaken as early as possible to allow early mobilization of the patient.<sup>[6]</sup> However, although there have been many options to achieve satisfactory functional outcomes in the reconstruction of proximal femoral fractures, each technique has its own specific disadvantages in terms of postoperative complications. Extramedullary implants and intramedullary nails have been used for the internal fixation of trochanteric fractures. Sliding hip screws had been the most commonly used devices as they allowed for extramedullary fixation of the fracture while assuring fracture collapse. However, for the last two decades, intramedullary nailing has increasingly gained interest owing

Address for correspondence: Sinan Zehir, M.D.

Hitit Üniversitesi Tıp Fakültesi, Ortopedi ve Travmatoloji  
Anabilim Dalı, 19100 Çorum, Turkey

Tel: +90 364 - 222 11 00/01 E-mail: sinanzehir@yahoo.com

Quick Response Code



Ulus Travma Acil Cerrahi Derg  
2015;21(6):469-476  
doi: 10.5505/tjtes.2015.28227

Copyright 2015  
TJTES

to its biomechanical advantages such as allowing more central placement of the implant to assure smaller bending moment and being several times stronger than sliding hip screws which is of importance in enabling better mobilization and resistance after surgery.<sup>[7]</sup>

Talon distal fix nail/lag screw (ODI, Florida, USA) system provided an innovative method for distal femoral fixation. Distal talons on the nail deploy from within the femoral canal and this feature eliminates the need for using cortical screws. Talon Lag screws used in conjunction with the nails feature the same method to improve rotational stability within the femoral head/neck junction. It is still controversial whether intramedullary nailing devices will replace extramedullary fixation because biomechanical tests still awaits confirmation by clinical studies. We herein report our institutional experience regarding the use of Talon distal fix nail/lag screw device in comparison with results we obtained using two other common techniques for intramedullary nailing; proximal femur anti-rotation (PFNA, Synthes, Oberdorf, Switzerland) and InterTan nail (Smith & Nephew, Memphis, Tennessee).

## MATERIALS AND METHODS

The study was approved by local ethics committee. All patients consented to the use of their records for research purposes. The study was undertaken in a tertiary university

hospital. This was a retrospective cohort study and was made up of patients operated on for unstable trochanteric fractures between January 2010 and September 2013. Baseline data were collected by reviewing patients' charts and medical records. Patients with A2 and A3 type fractures were included and those with pathological fractures, intracapsular fractures, and high-velocity fractures were excluded. Patients who were bedridden or wheel-chair bound before the injury and those having history of previous hip surgery were also excluded. All of the operations were performed by surgeons who had independently performed several operations with either technique. Patients were divided into three groups based on the technique used; Talon distal fix nail/lag screw (since September 2012), PFNA nail (since January 2010) or InterTan nails (since January 2010). Baseline characteristics of patients were given in Table I.

Operations were performed under spinal or general anesthesia. Prophylactic antibiotics were given 30 minutes before the skin incision was made. Operations were performed according to the standard protocols of each device as instructed by the manufacturer.

## Surgical Technique

### Talon Distal Fix Nail/Lag Screw

The patient was placed in supine position on a fracture table

**Table I.** Baseline characteristics

Variable	Talon Lag screw			PFNA			InterTan			p*
	n	%	Mean±SD	n	%	Mean±SD	n	%	Mean±SD	
Number of patients	78	28.3		96	34.8		102	37.0		
Age (Years)			78.49±6.64			77.22±6.82			76.86±6.74	0.25
Gender (Males)	32	41		37	38.5		39	38.2		0.92
Fracture side (Right)	33	42.3		53	55.2		57	55.9		0.13
Diabetes	25	32.1		33	34.4		24	23.5		0.21
Hypertension	25	32.1		35	36.5		37	36.3		0.79
Chronic pulmonary disease	14	17.9		22	22.9		18	17.6		0.59
Heart failure	12	15.4		18	18.8		7	6.9		0.04
Coronary artery disease	1	1.3		3	3.1		12	11.8		0.04
Multiple disease	17	21.8		22	22.9		22	21.6		0.97
Fracture type										
A2.1	15	19.2		24	25.0		21	20.6		0.61
A2.2	34	43.6		40	41.7		44	43.1		0.96
A2.3	22	28.2		28	29.2		28	27.5		0.96
A3.1	4	5.1		2	2.1		4	3.9		0.55
A3.2	1	1.3		1	1.0		3	2.9		0.55
A3.3	2	2.6		1	1.0		2	2.0		0.74
Time until operation (weeks)			3.49±1.71			3.29±1.89			3.35±2.01	0.43

\*According to the Bonferroni correction, p value of  $<0.05/3=0.017$  was considered as limit of statistical significance when comparing ratios among three groups.

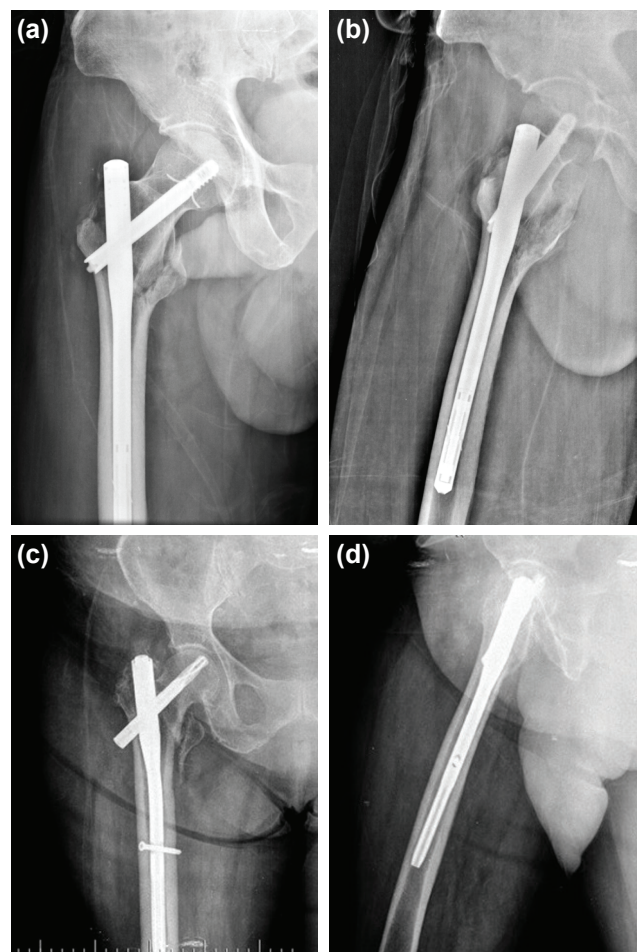
with the affected leg fixed in slight adduction. Prior to draping the patient, a closed reduction was made under fluoroscopy. A longitudinal incision was made proximal to the greater trochanter. Proximal femur was reamed over a guidewire to an appropriate length for the given patient. Nail length was measured using a template. A guide assembly composed of an arm and a handle was loaded with a nail of desired length and secured. Lag guide sleeve was inserted through the guide arm and proper alignment of the nail was verified. Lag guide sleeve was removed prior to nail insertion. The nail was passed over the guidewire and advanced down the femur. A lag guide pin obturator was inserted into the lag guide pin sleeve and introduced through the hole in the guide arm. A small skin incision was made and the obturator and the sleeve were advanced until the tip contacts the lateral cortex of the femur. The position was radiographically verified and guide arm was tightly secured. An appropriate sized lag guide pin was advanced until it reached the ultimate position of the lag screw within the femoral head. Guide pin depth was measured and the canal for lag screw was drilled to the desired depth based on this measurement. A lag alignment plug was passed over the guidewire passing through the hole in the nail to maintain the nail's position during deployment of the nail Talons. Using a talon deployment driver and turning it clockwise for several times, nail talons were deployed. Then, lag screw attached to a driver assembly was passed over the guidewire and through the sleeve. The lag screw was fully inserted by turning the driver clockwise and applying pressure. Final screw positioning was verified radiographically. Using the lag talon driver the talons on the screw were deployed. The lag sleeve and guide arm were removed and the final positioning was verified radiographically (Fig. 1a, b).

### PFNA (Proximal Femoral Nail Antirotation)

Patient positioning and closed reduction were made, as described above. Nail length was determined. A 5 cm incision was made over the greater trochanter. A guidewire was drilled and the medullary canal was reamed 0.5 to 1.5 mm greater than the nail diameter. Using an insertion handle assembly, PFNA was manually inserted into the femoral canal until it reached the appropriate depth. Sleeve assembly for PFNA was advanced through an appropriate angled aiming arm to the skin. A small incision was made and the sleeve assembly was inserted as far as the lateral cortex. A new guidewire was inserted into the bone with its tip positioned at the exact center of the femoral head. Using a measuring device, PFNA blade length was determined. A cannulated drill bit was drilled over the guidewire and the lateral cortex was opened. Fixing the fixation sleeve, hole for PFNA was reamed. PFNA blade was attached to the impactor and inserted over the guidewire. The PFNA blade was inserted advancing as far as possible into the femoral head. The blade was locked by turning the impactor clockwise. Distal locking was performed using static or dynamic screws. Final positioning was verified radiographically (Fig. 1c, d).

### InterTan Intertrochanteric Antegrade Nail

Patient positioning and closed reduction was made, as described above. A longitudinal incision was made proximal to the greater trochanter. A guidewire was inserted 2–3 cm into the trochanteric region by the aid of an entry portal assembly. An entry reamer was inserted into a channel reamer and reamed to the level of lesser trochanter. A reducer was introduced into the intramedullary canal while maintaining fracture reduction. The reducer was removed and intramedullary canal was reamed 1–1.5 mm larger than the selected nail size. By the aid of a drill guide handle, the nail was advanced into the proximal femur. An incision was made at the site of lag screw entry. The lateral cortex of the femur was drilled through a drill sleeve and a trocar. A threaded guide pin was inserted through the guide pin sleeve until it reached the appropriate position in the femoral neck and head. Guide pin position was verified radiographically. Tri-gen InterTan nail was inserted with single subtrochanteric lag screw. Guidepin sleeve was replaced with lag screw sleeve. Lag screw drill was drilled to the depth measured for the lag screw. By the aid of a T-handle, the lag screw driver was



**Figure 1.** (a) Anteroposterior view of Talon distal fix nail application. (b) Lateral view of Talon distal fix nail application. (c) Anteroposterior view of proximal femoral nail antirotation application. (d) Lateral view of proximal femoral nail antirotation application.

**Table 2.** Surgical data

Variable	Talon Lag Screw			PFNA			InterTan			p*
	n	%	Mean±SD	n	%	Mean±SD	n	%	Mean±SD	
General	15	19.2		16	16.7		19	18.6		0.89
Spinal	43	55.1		56	58.3		61	59.8		0.81
Epidural	5	6.4		12	12.5		11	10.8		0.40
Combined	1	1.3		5	5.2		7	6.9		0.20
Nerve Block	14	17.9		7	7.3		4	3.9		0.004
Time of operation (min)			42.05±6.24			44.41±5.17			55.35±5.8	<0.001
Blood loss (ml)			126.47±40.93			139.69±39.69			211.42±31.56	<0.001
Time of fluoroscopy			1.40±0.11			1.50±0.18			2.0±0.22	<0.001

\*According to the Bonferroni correction, p value of  $<0.05/3=0.017$  was considered as limit of statistical significance when comparing ratios among three groups.

manually advanced without compression through the hole within the nail. Distal locking was performed using appropriate sized locking screws. Final positioning was verified radiographically (Fig. 2a, b).

### Postoperative Care and Follow-Up

After surgery, patients were mobilized out of bed on the first postoperative day and allowed weight bearing, as tolerated. Low molecular weight heparin was given for three days and intravenous antibiotics were used during the time until discharge. Patients were discharged home when they began to walk with little assistance. Patients were invited to follow-up at 4 weeks and at every three months thereafter. Harris hip scores were measured at the most recent follow-up and were put into evaluation. Survival information was obtained either by making phone interviews or searching patient data from social security registry network.

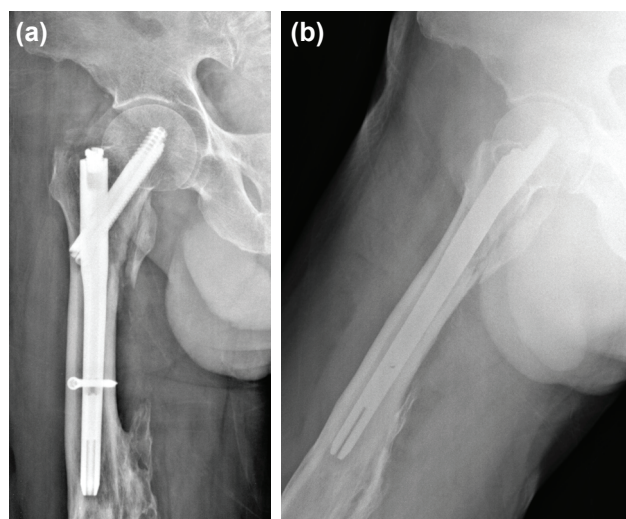
### Statistical Analysis

Statistical analyses were performed using SPSS 19.0 packaged software. Distribution of variables was tested using visual histograms and Kolmogorov-Smirnov test to determine normality. Descriptive statistics for continuous variables were reported as mean±SD and descriptive statistics for categorical variables were reported as frequency and percentage. One-way ANOVA was used to compare continuous variables among three groups. Levene test was used to assess the homogeneity of variances. Post-hoc tests were performed using Tukey's test. Categorical variables were compared using chi-square test or Fisher's exact test, where appropriate. Kaplan-Meier survival estimates were calculated. Log rank test was used to identify the independent effect of type of device used on survival. Since time to follow-up variables did not show homogeneity, Welch ANOVA test was used for comparison. A Bonferroni correction was made and p value of less than  $0.05/3=0.017$  was considered to be statistically significant.

## RESULTS

Three groups were similar in terms of baseline characteristics except that heart failure was slightly more common and coronary artery disease was slightly less common in InterTan group (non-significant). Baseline patient characteristics and distribution of fracture types among groups were given in Table 1.

Operations were performed under general anesthesia in fifty patients (18.1%) and under spinal/epidural anesthesia in one hundred and eighty-eight patients (68.1%). Thirteen patients (4.8%) received a combination of general and spinal/epidural anesthesia and twenty-five patients (9.0%) received nerve blockade (Table 2). Operation took significantly longer in InterTan group than in PFNA and Talon distal fix nail/lag screw groups. Patients receiving InterTan nails had significantly more blood loss and significantly longer fluoroscopy times than those receiving other two techniques (Table 2).



**Figure 2.** (a) Anteroposterior view of InterTan intertrochanteric antegrade nail application. (b) Lateral view of InterTan intertrochanteric antegrade nail application.

**Table 3.** Early postoperative complications and morbidities

Variable	Talon Lag Screw		PFNA		InterTan		p*
	n	%	n	%	n	%	
Superficial wound infection	2	2.6	4	4.2	7	6.9	0.38
Deep wound infection	1	1.3	0	0.0	2	2.0	0.40
Hematoma	1	1.3	2	2.1	4	3.9	0.50
Cut-out	0	0.0	8	8.3	0	0.0	<0.001
Screw migration	0	0.0	5	5.2	0	0.0	0.008
Pain at hip	3	3.8	3	3.1	3	2.9	0.94
Pain at thigh	4	5.1	7	7.3	2	2.0	0.20
Reoperation	3	3.8	9	9.4	5	4.9	0.25
Deep venous thrombosis	5	6.4	7	7.3	6	5.9	0.92
Pulmonary embolism	0	0.0	1	1.0	1	1.0	0.67
Decompensated heart failure	2	2.6	3	3.1	3	2.9	0.97
Urinary tract infection	6	7.7	9	9.4	9	8.8	0.92
Pneumonia	2	2.6	4	4.2	4	3.9	0.83
Pressure ulcer	7	9.0	9	9.4	10	9.8	0.98
In-hospital mortality	2	2.6	2	2.1	5	4.9	0.49

**Table 4.** Comparison of time to fracture healing and Harris scores among patients surviving at least 6 months after the operation

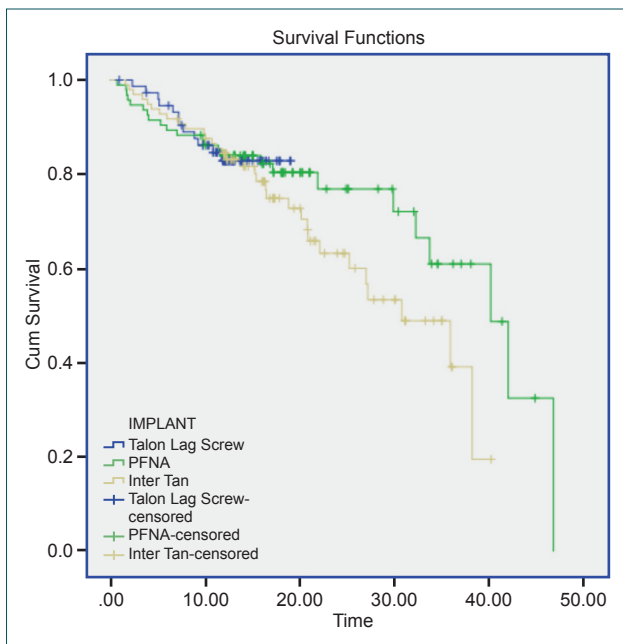
Variable	Talon Lag Screw (n=70)	PFNA (n=85)	InterTan (n=88)	p*
	Mean±SD	Mean±SD	Mean±SD	
Time to healing* (weeks)	22.11±2.32	22.86±2.22	22.93±2.39	0.06
Harris scores	75.84±17.79	75.87±22.23	71.26±26.55	0.32

Mean length of postoperative stay was similar among groups (7.01±1.61 days, 7.14±2.13 days and 7.45±1.94 days in Talon distal fix nail/lag screw, PFNA and InterTan groups, respectively, p=0.28). Mean tip apex distance (TAD) was also similar among groups (21.25±4.5 mm, 22.70±3.01 mm, 24.02±18.87 mm in Talon distal fix nail/lag screw, PFNA and InterTan groups, respectively, p=0.30).

Postoperative complications and morbidities were given in Table 3. A total of thirteen patients (4.7%) had superficial wound infections and were totally cured with wound care and antibiotics without requiring tissue debridement. Deep wound infection occurred in three patients; one patient in Talon distal fix nail/lag screw group and one of two patients in InterTan group received a single-step tissue debridement for deep wound infection whereas the other patient was cured with conservative treatment alone. None required hardware removal. *Staphylococcus aureus* was the causative agent in all three patients. Hematomas occurred in seven patients. Three out of these underwent surgical drainage while hematomas resolved spontaneously in the remaining.

Screw cut-out occurred in eight patients in PFNA group with five of these having screw migration. There were no instances of screw cut-out in the other two groups. Three out of these patients had A2.1 type fracture, 4 had A2.2 type fracture and 1 had A2.3 type fracture. In five patients, femoral neck screws were too short and replaced with longer screws. The other three patients underwent revision for hip arthroplasty. Overall, reoperation rates were similar among the groups. Several morbidities occurred in the minority of patients and were listed in Table 3. A total of nine patients (3.2%) aging from 72 to 91 years died within 30 days after the operation; eight died of decompensated heart failure and one died of pneumonia.

Follow-up information was complete in all patients who were discharged home (n=265, 96.8%). Time to healing and Harris scores were similar among the groups (Table 4). Median time to follow-up was 12.17 months (1–19 months) in Talon distal fix nail/lag screw group, 16.06 months (1–46 months) in PFNA group, and 16.00 months (1–40 months) in InterTan group. Follow-up was significantly shorter in patients receiving Talon distal fix nail/lag screw (p<0.01) indicating that the



**Figure 3.** Survival graph of study patients (Log rank  $p=0.33$ , among groups).

device has been in use for a relatively shorter time (since September 2012) than other two devices. During follow-up, twelve patients (16.0%) in Talon distal fix nail/lag screw, 24 patients (25.5%) in PFNA group and 32 patients (33.0%) in InterTan group died of various causes. Mean time of survival was not significantly different among three groups;  $17.06 \pm 0.53$  months in Talon distal fix nail/lag screw,  $34.24 \pm 2.10$  months in PFNA group,  $27.69 \pm 1.58$  months in InterTan group (overall Log Rank  $p$  value=0.33), (Figure 3). One-year survival rate was  $83.1 \pm 4.5\%$  in Talon distal fix nail/lag screw,  $84.0 \pm 3.8\%$  in PFNA group and  $84.4 \pm 3.7\%$  in InterTan group. Three-year survival rate was  $61.0 \pm 9.3\%$  in PFNA group and  $49.0 \pm 8.1\%$  in InterTan group ( $p=0.14$ ). More than one-year survival could not be given in Talon distal fix nail/lag screw group since there were less than five patients remained at 18th month of follow-up.

## DISCUSSION

In the present study, results with the Talon distal fix nail/lag screw system was comparable to PFNA and InterTan screws in treatment of unstable proximal femoral fractures in patients older than 65 years of age. Operation and fluoroscopy times were shorter in Talon distal fix nail/lag screw group and PFNA group than those in InterTan group. We achieved satisfactory results even though during our earlier attempts in implanting the Talon distal fix nail/lag screw, indicating that the system offers a steep learning curve as long as the surgeon performing the procedure has adequate experience in intramedullary device implantation.

A recent Cochrane review demonstrated no superiority of intramedullary nailing over sliding hip screws in terms of

preventing complications and reoperations<sup>[8]</sup> and concluded that further studies are required to establish the assumed advantages of recently developed designs. In Sweden, it was reported that, within the last decade, surgeons have become more commonly using intramedullary nailing than sliding hip screws in treatment of pertrochanteric fractures.<sup>[9]</sup> Moreover, a large Finnish database study showed that patients operated on using intramedullary nails had significantly higher reoperation rates (11.1% vs. 8.9%;  $p<0.0001$ ) and also, higher one-year mortality (26.6% vs. 24.9%;  $p=0.011$ ) than those receiving conventional techniques.<sup>[10]</sup>

However, these data seem to exacerbate rather than restrict the use of intramedullary nailing, especially during the few years. Surgeons are likely to be convinced getting rid of known disadvantages of hip screws including excessive collapse, femoral shortening<sup>[11]</sup> and late recovery of normal mobility,<sup>[12]</sup> at the expense of increasing cost.<sup>[13]</sup> Type of the fracture should be regarded as an important factor in designing future studies since more unstable fractures of the femoral head (i.e having an extending component through the femoral shaft, AO-A3) may require a distinct approach in the given patient.<sup>[14]</sup> Data from this perspective may change the view on intramedullary nailing in particular instances.

Complication rates were similar among Talon distal fix nail/lag screw, PFNA and InterTan groups except for cut-out which occurred only in patients receiving PFNA device. The earlier PFN system which was designed to overcome the shortcomings of well-known Gamma nail was further modified in 2003 by adding a lateral locking head to the blade to prevent rotation and micro-motion. Supporting this was a large multicenter study suggesting that PFNA was an optimal implant for unstable trochanteric fractures in osteoporotic patients due its capability of limiting early rotation of head/neck fragment.<sup>[15]</sup> In another comparative study, Gardenbroek et al.<sup>[16]</sup> have reported that patients receiving PFNA or PFN device have similar positioning of the device whereas late reoperations less frequently occurred in PFNA group than in PFN group. A recent model based study has demonstrated that helical blade of the PFNA nail provides better compaction within bone in case of lower femoral head bone density, indicating the device has potential of decreasing cut out in osteoporotic patients.<sup>[17]</sup>

Nevertheless, risk of cut-out has not totally be eliminated in patients receiving PFNA device and benefits of the modification have not always been reflected in recent studies. Takigami et al.<sup>[18]</sup> reported that cut out occurred in one patient and lateral sliding of the blade occurred in four patients in their series of fifty patients receiving Asian modification of PFNA device. In a more recent study, cut out occurred in three patients from PFNA group; whereas, in none receiving Gamma3 nail.<sup>[19]</sup> Gavaskar et al.<sup>[20]</sup> have made a stratification based on the AO classification and reported that complication rates are significantly higher in patients with unstable fractures than

those having A1 type fractures. Eight patients in our study underwent a second operation to fix cut-out problem; three out of them had A2.1 type fracture, four had A2.2 type fracture and one had A2.3 type fracture. Six of these patients were over 80 with one being 96 years of age. We are of the opinion that design of the screw - PFNA or not - is not the only concern regarding the risk of failure, but the risk may also be related with patient related factors.

InterTan nail is similar to PFNA both by means of design and technique. Featuring one or two cephalocervical screws integrated within a distal nail, the system allows for further rotational stability of the fragmented segments at femoral head or neck. Biomechanical tests have shown that InterTan nail is superior to dynamic hip screws, demonstrating a longer survival under cycling loading and less head displacement.<sup>[21]</sup> In a clinical comparative study, Zhang et al.<sup>[22]</sup> have reported that patients receiving InterTan experience less pain than those receiving PFNA asia system with postoperative complications occurred in similar rates between groups. In InterTan group, we achieved slightly shorter operative and fluoroscopy times than reported in this series while it took significantly longer than implanting PFNA or Talon distal fix nail/lag screw. These authors, similar to us, reported that there were no cut-out lesions in patients receiving InterTan nails at follow-up. We think that low rate of complications is due the advantage of implanting two screws in InterTan technique which eliminates the risk of rotational instability produced by a single screw which may fail to resist the excess amount of load during weight bearing.

Talon distal fix nail/lag screw had four deployable talons both in the femoral shaft part and femoral head part which allow it to gain advanced purchase within bone. Biomechanical testing showed improved intrafragmenter compression about one decade ago.<sup>[23]</sup> To our knowledge, there has been no clinical study reporting outcomes using the device. Our experiences regarding the device's benefits are as follows; it engaged into the femoral head and the talons deployed and it anchored into the cortex of the bone and provided good pullout force. The talons are likely to provided resistance against rotation about the axis of the screw although these feature was not tested during the operation. Overall, the technique allowed an easy implantation provided that medullary canal was reamed down to the level that is measured before beginning with the nail insertion. Deployment of the Talons was not distressing and did not require additional effort during the operation. Given that it provided shorter operative times, possibly by eliminating the need for a second screw, this technique may be preferred over InterTan technique since it caused similar rates in terms of postoperative outcomes.

Risk factors for higher mortality after hip fracture have been reported to be related with various factors including, trochanteric fracture, low body mass index, poor health status and poor pulmonary function.<sup>[5]</sup> However, data is limited about

mortality rates after receiving different treatment strategies in the literature. In our study, one and three-year survival rates were similar than those previously reported, and survival was not different among patients operated on using different techniques, indicating that this study had a near-equal patient distribution among groups not only in baseline characteristics but also in terms of life expectancy.

Main limitations of our study was its retrospective design and non-randomization of the patients into treatment arms. Since the number of patients were not equally distributed by type of fracture, we could not draw a conclusion based on which technique fits better to a more complicated fracture.

## Conclusion

Our experiences showed that Talon distal fix nail/lag screw, PFNA and InterTan systems provided similar satisfactory outcomes and acceptable complication rates in treatment of intertrochanteric fractures. New Talon distal fix nail/lag screw was associated with lower cut-out when compared to PFNA and shorter operative times when compared with InterTan. Retrospective and non-randomized design of the study precluded drawing a definitive conclusion to postulate the superiority of any device over another. Thus, further study is warranted to clearly establish these potential advantages distal Talon fix in treatment of severely fragmented pertrochanteric fractures.

Conflict of interest: None declared.

## REFERENCES

1. Cooper C, Cole ZA, Holroyd CR, Earl SC, Harvey NC, Dennison EM, et al. Secular trends in the incidence of hip and other osteoporotic fractures. *Osteoporos Int* 2011;22:1277–88. [CrossRef](#)
2. Tanner DA, Kloseck M, Crilly RG, Chesworth B, Gilliland J. Hip fracture types in men and women change differently with age. *BMC Geriatr* 2010;10:12. [CrossRef](#)
3. Maeda Y, Sugano N, Saito M, Yonenobu K. Comparison of femoral morphology and bone mineral density between femoral neck fractures and trochanteric fractures. *Clin Orthop Relat Res* 2011;469:884–9. [CrossRef](#)
4. Frost SA, Nguyen ND, Center JR, Eisman JA, Nguyen TV. Excess mortality attributable to hip-fracture: a relative survival analysis. *Bone* 2013;56:23–9. [CrossRef](#)
5. Lin WP, Wen CJ, Jiang CC, Hou SM, Chen CY, Lin J. Risk factors for hip fracture sites and mortality in older adults. *J Trauma* 2011;71:191–7.
6. Daugaard CL, Jørgensen HL, Riis T, Lauritzen JB, Duus BR, van der Mark S. Is mortality after hip fracture associated with surgical delay or admission during weekends and public holidays? A retrospective study of 38,020 patients. *Acta Orthop* 2012;83:609–13. [CrossRef](#)
7. Schipper IB, Marti RK, van der Werken C. Unstable trochanteric femoral fractures: extramedullary or intramedullary fixation. Review of literature. *Injury* 2004;35:142–51. [CrossRef](#)
8. Parker MJ1, Handoll HH. Gamma and other cephalocondylic intramedullary nails versus extramedullary implants for extracapsular hip fractures in adults. *Cochrane Database Syst Rev* 2010;9:CD000093.
9. Rogmark C, Spetz CL, Garellick G. More intramedullary nails and

- arthroplasties for treatment of hip fractures in Sweden. *Acta Orthop* 2010;81:588–92. [CrossRef](#)
10. Yli-Kyyny TT, Sund R, Juntunen M, Salo JJ, Kröger HP. Extra- and intramedullary implants for the treatment of pertrochanteric fractures -- results from a Finnish National Database Study of 14,915 patients. *Injury* 2012;43:2156–60. [CrossRef](#)
  11. Platzer P, Thalhammer G, Wozasek GE, Vécsei V. Femoral shortening after surgical treatment of trochanteric fractures in nongeriatric patients. *J Trauma* 2008;64:982–9. [CrossRef](#)
  12. Parker MJ, Bowers TR, Pryor GA. Sliding hip screw versus the Targon PF nail in the treatment of trochanteric fractures of the hip: a randomised trial of 600 fractures. *J Bone Joint Surg Br* 2012;94:391–7. [CrossRef](#)
  13. Lüthje P, Helkama T, Nurmi-Lüthje I, Kaukonen JP, Kataja M. An 8-year follow-up study of 221 consecutive hip fracture patients in Finland: analysis of reoperations and their direct medical costs. *Scand J Surg* 2014;103:46–53. [CrossRef](#)
  14. Kregor PJ, Obremesky WT, Kreder HJ, Swionkowski MF; Evidence-Based Orthopaedic Trauma Working Group. Unstable pertrochanteric femoral fractures. *J Orthop Trauma* 2005;19:63–6. [CrossRef](#)
  15. Simmermacher RK, Ljungqvist J, Bail H, Hockertz T, Vochteloo AJ, Ochs U, et al. The new proximal femoral nail antirotation (PFNA) in daily practice: results of a multicentre clinical study. *Injury* 2008;39:932–9. [CrossRef](#)
  16. Gardenbroek TJ, Segers MJ, Simmermacher RK, Hammacher ER. The proximal femur nail antirotation: an identifiable improvement in the treatment of unstable pertrochanteric fractures? *J Trauma* 2011;71:169–74.
  17. Goffin JM, Pankaj P, Simpson AH, Seil R, Gerich TG. Does bone compaction around the helical blade of a proximal femoral nail anti-rotation (PFNA) decrease the risk of cut-out?: A subject-specific computational study. *Bone Joint Res* 2013;2:79–83. [CrossRef](#)
  18. Takigami I, Matsumoto K, Ohara A, Yamanaka K, Naganawa T, Ohashi M, et al. Treatment of trochanteric fractures with the PFNA (proximal femoral nail antirotation) nail system - report of early results. *Bull NYU Hosp Jt Dis* 2008;66:276–9.
  19. Vaquero J, Munoz J, Prat S, Ramirez C, Aguado HJ, Moreno E, et al. Proximal Femoral Nail Antirotation versus Gamma3 nail for intramedullary nailing of unstable trochanteric fractures. A randomised comparative study. *Injury* 2012;43 Suppl 2:S47–54. [CrossRef](#)
  20. Gavaskar AS, Subramanian M, Tummala NC. Results of proximal femur nail antirotation for low velocity trochanteric fractures in elderly. *Indian J Orthop* 2012;46:556–60. [CrossRef](#)
  21. Rupperecht M, Grossterlinden L, Ruecker AH, de Oliveira AN, Sellenschloh K, Nüchtern J, et al. A comparative biomechanical analysis of fixation devices for unstable femoral neck fractures: the Intertan versus cannulated screws or a dynamic hip screw. *J Trauma* 2011;71:625–34.
  22. Zhang S, Zhang K, Jia Y, Yu B, Feng W. InterTan nail versus Proximal Femoral Nail Antirotation-Asia in the treatment of unstable trochanteric fractures. *Orthopedics* 2013;36:288–94. [CrossRef](#)
  23. Bramlet DG, Wheeler D. Biomechanical evaluation of a new type of hip compression screw with retractable talons. *J Orthop Trauma* 2003;17:618–24. [CrossRef](#)

## ORIJİNAL ÇALIŞMA - ÖZET

### İnstabil trokanterik kırık tedavisinde kullanılan üç farklı intramedüller çivinin klinik sonuçlarının karşılaştırılması

Dr. Sinan Zehir,<sup>1</sup> Dr. Ercan Şahin,<sup>2</sup> Dr. Regayip Zehir<sup>3</sup>

<sup>1</sup>Hittit Üniversitesi Tıp Fakültesi, Ortopedi ve Travmatoloji Anabilim Dalı, Çorum

<sup>2</sup>Bülent Ecevit Üniversitesi Tıp Fakültesi, Ortopedi ve Travmatoloji Anabilim Dalı, Zonguldak

<sup>3</sup>Çarşamba Devlet Hastanesi, Kardiyoloji Kliniği, Samsun

**AMAÇ:** İntertrokanterik kırıkların tedavisinde kullanılan üç farklı intramedüller çivileme yöntemiyle ilişkili sonuçların değerlendirilmesi amaçlandı.

**GEREÇ VE YÖNTEM:** Bu geriye dönük kohort çalışmasına A2 ve A3 tip stabil olmayan trokanterik kırık nedeniyle opere edilen hastalar dahil edildi. Kullanılan tekniğe göre hastalar üç gruba ayrıldı: Talon distal sabit çivi/lag screw (n=78, ortalama yaş: 78.5±6.6), PFNA çivi (n=96, ortalama yaş: 77.2±6.8) ve İnterTan çivisi (n=102, ortalama yaş: 76.8±6.7). Son kontrolde Harris kalça skoru kaydedildi, sağkalım telefon görüşmesi ve vatandaşlık bilgi bankası kayıtlarından elde edildi.

**BULGULAR:** Grupların temel özellikleri benzerdi. İnterTan grubunda ameliyat süresi, floroskopi zamanı ve kan kaybı anlamlı olarak fazlaydı. PFNA grubunda sekiz hastada cut-out oluştu. Hastane içi mortalite %3.2 idi (dokuz hasta). Hastanede yatış süresi ve ameliyat sonrası tip-apex mesafesi gruplar arasında farklı değildi. İyileşme süresi ve Harris kalça skoru gruplar arasında benzerdi. Bir yıllık sağ kalım Talon distal sabit çivi/lag screw grubunda %83.1±4.5, PFNA grubunda %84.0±3.8 ve İnterTan grubunda 84.4±3.7 bulundu (p=0.33).

**TARTIŞMA:** Talon distal sabit çivi/lag screw yöntemi daha az cut-out oranıyla PFNA tekniğinden ve daha kısa ameliyat süresiyle İnterTan yönteminde daha iyi olarak bulunmuştur.

**Anahtar sözcükler:** İntermedüller çivi; komplikasyon; sağkalım; trokanterik kırık.

*Ulus Travma Acil Cerrahi Derg* 2015;21(6):469–476 doi: 10.5505/tjtes.2015.28227