

The efficacy of continuous lumbar drainage in post-traumatic cerebrospinal fluid fistulas

Alparslan Kırık, M.D., Soner Yaşar, M.D.

Department of Neurosurgery, Health Sciences University, Gülhane Training and Research Hospital, Ankara-Turkey

ABSTRACT

BACKGROUND: This study aims to investigate the clinical outcomes of patients who underwent closed continuous lumbar drainage (CLD) for post-traumatic cerebrospinal fluid (CSF) fistula and to compare with those of non-traumatic patients.

METHODS: The data of patients who were treated in the department of neurosurgery between January 2018 and December 2019 and underwent CLD were analyzed. The diagnosis, demographic characteristics, CSF results and clinical outcomes of these patients were evaluated. The outcomes of the patients with dura defect and CSF fistula due to trauma were compared with patients who underwent CLD for other diagnoses.

RESULTS: In this study, 45 patients underwent CLD for 51 times. The mean age was 38.84 years, and 27 (60%) of the patients were male. Seven (15.55%) patients underwent CLD due to post-traumatic CSF fistula and 38 patients after tumor or malformation surgery. While five patients developed CSF fistula due to dura defect after gunshot injury, two patients developed CSF fistula secondary to motor vehicle accident. Staphylococcus Epidermidis was isolated in one patient among post-traumatic CSF fistula patients while Serratia Marcescens was isolated in patients with CSF fistula secondary to posterior fossa tumor surgery. While none of the seven patients died during the follow-up period in post-traumatic group, one of the 38 patients with CLD secondary to tumor surgery was lost due to sepsis in the follow-up period.

CONCLUSION: CLD in post-traumatic CSF fistulas is a safe and effective treatment method. Especially in patients with gunshot wounds, CLD should be performed before revision surgery in the treatment of CSF fistula. Studies with different parameters are needed in larger trauma populations.

Keywords: Cerebrospinal fluid fistula; continuous lumbar drainage; trauma; tumor.

INTRODUCTION

Cerebrospinal fluid (CSF) fistula is a troublesome but a well-known complication of post-traumatic skull fractures, skull base surgery, and spinal surgeries.^[1,2] CSF may cause significant morbidity and mortality due to meningitis, as well as sepsis.^[1,3] The treatment is mostly surgical repair of the site of CSF leakage. However, this is a challenging surgical procedure, especially in deeply located skull base dura defects. In patients with unidentified fistula site, diversion of CSF with closed continuous lumbar drainage (CLD) is the first choice of treatment and has been widely used.^[1]

CLD systems are devices placed in the subarachnoid space from the lumbar region when there is a CSF fistula in anywhere of the central nervous system (CNS). The aims of the CLD are to remove the CSF with this drainage, to reduce the CSF pressure, and to close the CSF fistula site in the upper CNS.^[1,4]

Although CLD is used in patients of all ages and all types of diagnosis, it is commonly used in cases with rhinorrhea or otorrhea that occurs after surgery in the sellar region or after skull traumas. However, it may also occur following spinal traumas. Although the average CLD duration is seven days, the patient can stay for three to five days.^[1,3-5]

Cite this article as: Kırık A, Yaşar S. The efficacy of continuous lumbar drainage in post-traumatic CSF fistulas. *Ulus Travma Acil Cerrahi Derg* 2020;26:784-788.

Address for correspondence: Alparslan Kırık, M.D.

SBÜ Gülhane Eğitim ve Araştırma Hastanesi, Beyin ve Sinir Cerrahisi Anabilim Dalı, 06018 Etlik, Ankara, Turkey

Tel: +90 312 - 304 53 07 E-mail: dr_alper@hotmail.com

Ulus Travma Acil Cerrahi Derg 2020;26(5):784-788 DOI: 10.14744/tjtes.2020.26446 Submitted: 09.03.2020 Accepted: 19.07.2020 Online: 15.09.2020
Copyright 2020 Turkish Association of Trauma and Emergency Surgery



The most significant complications are excessive CSF drainage and subdural effusion, occlusion and continuation of CSF fistula, pneumocephalus and infection (meningitis).^[1,5,6] Headache and blindness may be observed after pneumocephalus and overdrainage. Rarely, the roots that form the cauda equina can also be damaged. Especially the infection has been reported between 3–5% and the most important risk factor for infection is the duration of drainage.^[1,6] CSF culture, CSF protein and glucose values are the most significant parameters of infection.

In this study, the data of patients who had a CLD system between 2018 and 2019 at the Gülhane Training and Research Hospital Neurosurgery Clinic was analyzed retrospectively. Patients' ages, genders, diagnoses, CSF protein and glucose results, surgical methods, CSF culture results and treatment results of patients were examined.

MATERIALS AND METHODS

This is a retrospective clinical study and the approval of the ethics committee of our institution was obtained for this study.

The data of 45 patients who underwent CLD (Argifix® External lumbar drainage catheter, ArgiGroup, Ankara, Turkey) between 2018 and 2019 were retrospectively reviewed. The age, gender, cause of CSF fistula, culture results, and clinical outcomes were documented. CSF analysis was performed in all patients and CSF was obtained from the reservoir of the lumbar drainage. The radiological and neurological conditions of the patients were also analyzed. Computed tomography (CT) scan was obtained from all patients to rule out any pneumocephalus or CNS lesion before the CLD. Particular attention was paid for lumbar drainage, which was performed in post-traumatic CSF fistula cases.

The CLD catheter was placed in the lumbar subarachnoid place with a Tuohy needle through the lumbar 4–5 interspinous space when the patient was in a lateral decubitus position (Argifix® External lumbar drainage catheter, ArgiGroup, Ankara, Turkey). The remaining part of the drainage kit coursed transversely across the back of the patient. The catheter insertion site was sutured and treated with povidone-iodine ointment. Steril drape was used to cover the entire external part of the CLD. The CSF was collected within the closed beg. The patients underwent an absolute bed rest after the insertion of CLD. The drainage rate was approximately 5–10 ml/hour or 150–250 ml/day. The system was left in place for 5–12 days (mean 8.3 days).

CSF samples were obtained from the collection beg on the 3rd day of drainage for biochemical and microbiological analysis. CSF glucose and protein levels were measured, and CSF culture was performed.

RESULTS

A total of 51 CLD was inserted in 45 patients between 2018 and 2019. Among them, 27 (60%) were male and 18 were female with a mean age of 38.84 years (ranged between 13 and 72 years). The diagnosis was pituitary adenoma in 16 patients, craniopharyngioma in six patients, skull base meningioma in five patients, trauma in seven (15.5%) patients, Chiari malformation in four patients, posterior fossa tumor in five patients, and spinal tumor in three patients (Fig. 1). Trauma was the second common cause of CSF fistula after the pituitary adenoma and five of seven patients had gunshot injuries. Other two patients had blunt head injury secondary to the motor vehicle accidents. Four of five patients had cranial gunshot wounds, and one had a lumbar spinal gunshot wounds. These patients underwent debridement of the necrotic tissue and repair of dura mater before the CLD, but CSF leak persisted after surgery. Two patients with motor vehicle accidents also underwent craniotomy for a skull fracture and intracranial hematoma, but CSF leak occurred after the surgery despite the meticulous closure of the dura mater.

Headache was the main complication and observed in 25 (55.5%) patients during the drainage. Pneumocephalus was detected in CT scan in three patients and the drainage was immediately stopped. Pneumocephalus was spontaneously disappeared after a few days (Fig. 2).

The microorganism was isolated in two (3.92%) of 51 CSF samples obtained from all of CLD procedures. One of them was Staphylococcus Epidermidis and the other was Serratia Marcescens. Staphylococcus Epidermidis was isolated in case of right occipital trauma case secondary to the motor vehicle accident, and Serratia Marcescens was isolated in a CSF

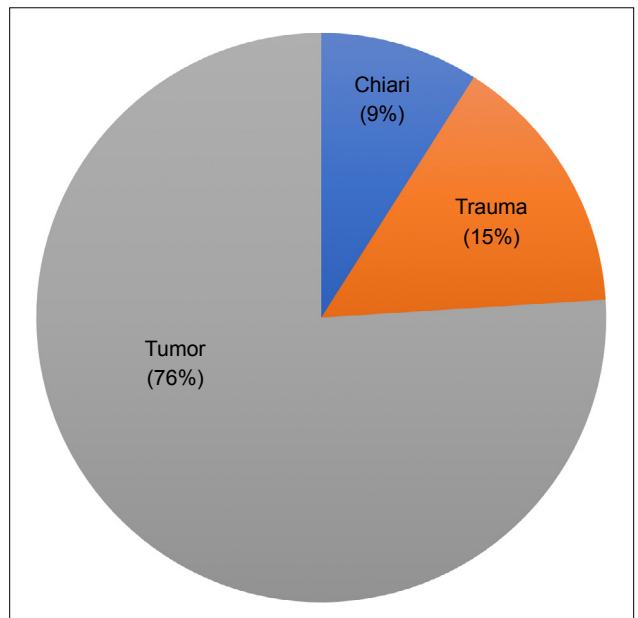


Figure 1. The distributions of patients based on the cause of CSF fistula.

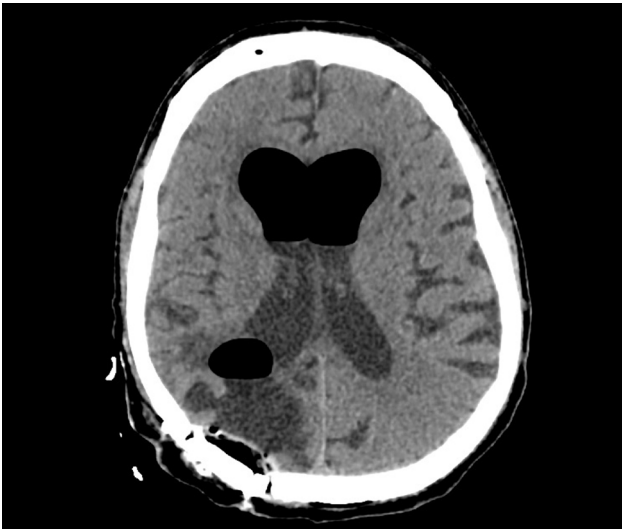

Figure 2. Axial CT scan of a patient who underwent CLD for post-traumatic CSF fistula and pneumocephalus in the lateral ventricles and post-traumatic encephalomalacia in the right occipital region are apparent.

fistula secondary to posterior fossa tumor surgery. Thus, the infection rate was 14.28% in CLD cases secondary to post-traumatic CSF fistula. In addition, the mean CSF glucose was 50.7 mg/dl, and the mean CSF protein was 146.14 mg/dl in post-traumatic CSF fistula cases (Table 1).

DISCUSSION

Cranial and spinal traumas may cause CSF fistula secondary to dura mater defects.^[7,8] Post-traumatic CSF fistulas are severe complications of gunshot wounds, which may cause significant mortality and morbidity.^[9,10] They may usually present with rhinorrhea or otorrhea, but sometimes CSF leaks may observe at the wound site after the surgical repair of the head or spinal injuries. The first choice is to repair the dural defect by surgical procedure. However, CLD may also be used to decrease the CSF pressure, to allow healing to occur at the fistula site.^[3,7,9] Ziyal et al.^[3] presented their series of 48 patients with post-traumatic CSF fistula and they performed CLD between seven and 12 days in 17 (35.4%) cases that were unresponsive to bed rest and antibiotics.

Vourc'h first introduced continuous spinal CSF drainage in 1963.^[11] Since then, this method has been used in neurosur-

gical practice. The success rate of this system has been reported as 85–94% by different publications.^[1,12–15] Fishman et al.^[16] demonstrated that CLD is a highly effective technique to treat CSF leak following acoustic neuroma surgery. CLD may be used after post-traumatic CSF fistula or after anterior skull base operations that may pose a CSF leak risk. Routine CLD placement is intended to decrease CSF leaks and CNS complications.^[5] In our series, 38 (84.4%) of 45 patients underwent CLD because of CSF fistula secondary to CNS tumor surgery and Chiari malformation. The most common tumor in our series was pituitary adenoma, followed by craniopharyngioma.

Açıkbaş et al.^[1] reported their experience with CLD in nine years and they performed CLD in 63 patients. Nine (14.28%) of them had post-traumatic CSF fistula, and they lost one patient due to hepatic failure and meningitis. They performed CLD for 5–10 days. They determined the duration of CLD based on the success of the system. Alagöz et al.^[17] reported 22 patients with traumatic CSF fistula and they performed conservative treatment or CLD in all patients before the surgical repair of the dural defect. In our series, post-traumatic CSF fistula was the cause of CLD in 15.55% of our patients, and the mean duration of CLD was 8.3 days (ranged between five and 12 days). We used CLD after the surgical repair of trauma patients. In case of infection, we immediately removed the catheter. Silver- and antibiotic-impregnated catheters were previously recommended for infected hydrocephalus, but we did not use these catheters for CSF fistulas because these catheters were not commercially available for CLD cases.^[18,19,20]

Ren et al.^[6] evaluated the efficacy of CLD in the treatment of post-craniotomy meningitis, and they found that intravenous antibiotic and steroid therapies combined with CLD may be an effective and safe treatment for post-craniotomy meningitis. They performed continuous drainage or episodic CSF drainage at 2–3 hour or 6-hour intervals, draining 300–350 ml CSF per day. This is the largest study in the literature, which was performed on 1062 patients over 16 years. In our study, the CSF drainage was 150–250 ml/day, and none of our patients had meningitis before the drainage. Ten of 45 patients had the previous craniotomy for trauma, tumor or Chiari malformation surgery. Twenty-five patients had transphenoidal surgery before the CLD and high-flow CSF leak

Table 1. The demographic features and laboratory results of the patients with CLD

Cause of CSF fistula	Number of patients	Mean age (years)	Male/Female	Mean CSF glucose (mg/dl)	Mean CSF protein (mg/dl)	Positive CSF culture
Trauma	7	26.29	6/1	50.7	146.14	1
Tumor	34	42.18	18/16	36.43	102.23	1
Chiari malformation	4	36	3/1	38.23	86.46	0

CSF: Cerebrospinal fluid; CLD: Continuous lumbar drainage.

was observed during surgery and then lumbar drainage was inserted just after the surgery.

Recently, Hussein and Abdellatif reported their series of 20 patients who underwent CLD for CSF fistula. In this series, all patients showed successful cessation of CSF leakage at different durations of CLD. Minimal pneumocephalus and headache were the most common complications in this series and they concluded that CLD is simple, safe, and effective on the treatment of CSF fistulas.^[4] We observed headache in 25 of 45 patients during CLD and pneumocephalus was seen in the CT scan in three patients. The CLD was stopped immediately in these patients.

Vourc'h^[11] and Açıkbaş et al.^[1] advised to avoid excessive CSF withdrawal because this may lead to headaches, nausea and vomiting. We also avoided draining more than 250 ml CSF a day because of the risk of overdrainage which may cause severe headache. We also did not leave in place the CLD for more than 12 days because of the risk of meningitis. We observed CSF infection in one of seven patients with post-traumatic CSF fistula and this case was treated using antibiotics. None of these seven patients died after CLD during the follow-up period.

Conclusion

Continuous lumbar drainage is a safe, simple and effective treatment method in the treatment of post-traumatic CSF fistula. It should be the first choice if surgical repair is not feasible. More clinical studies with larger trauma populations are needed to elucidate the risk factors for CLD.

Ethics Committee Approval: Approved by the local ethics committee.

Peer-review: Internally peer-reviewed.

Authorship Contributions: Concept: A.K., S.Y.; Design: A.K.; Supervision: S.Y.; Materials: A.K.; Data: A.K.; Analysis: A.K.; Literature search: S.Y.; Writing: A.K.; Critical revision: S.Y.

Conflict of Interest: None declared.

Financial Disclosure: The authors declared that this study has received no financial support.

REFERENCES

- Açıkbaş SC, Akyüz M, Kazan S, Tuncer R. Complications of closed continuous lumbar drainage of cerebrospinal fluid. *Acta Neurochir (Wien)* 2002;144:475–80. [\[CrossRef\]](#)
- Izci Y, Kayali H, Daneyemez M, Koksel T, Cerrahoglu K. The clinical, radiological and surgical characteristics of supratentorial penetrating craniocerebral injuries: a retrospective clinical study. *Tohoku J Exp Med* 2003;201:39–46. [\[CrossRef\]](#)
- Ziyal IM, Kılınçoğlu BF, Şahin Y, Aydın Y. Evaluation of posttraumatic cerebrospinal fluid fistula. *Ulus Travma Acil Cerrahi Derg* 1999;5:86–9.
- Hussein M, Abdellatif M. Continuous lumbar drainage for the prevention and management of perioperative cerebrospinal fluid leakage. *Asian J Neurosurg* 2019;14:473–8. [\[CrossRef\]](#)
- Ringel B, Carmel-Neiderman NN, Peri A, Ben Ner D, Safadi A, Abergel A, et al. Continuous lumbar drainage and the postoperative complication rate of open anterior skull base surgery. *Laryngoscope* 2018;128:2702–6.
- Ren Y, Liu X, You C, Zhang Y, Du L, Hui X, et al. Efficacy of closed continuous lumbar drainage on the treatment of postcraniotomy meningitis: A retrospective analysis of 1062 cases. *World Neurosurg* 2017;106:925–31. [\[CrossRef\]](#)
- Solmaz I, Kural C, Temiz C, Seçer HI, Düz B, Gönül E, et al. Traumatic brain injury due to gunshot wounds: a single institution's experience with 442 consecutive patients. *Türk Neurosurg* 2009;19:216–23.
- Izci Y, Tehli O. Cranial and spinal cord injuries in terror and war. *Eur Arc Med Res* 2017;33:21–39. [\[CrossRef\]](#)
- Izci Y, Kayali H, Daneyemez M, Koksel T. Comparison of clinical outcomes between anteroposterior and lateral penetrating craniocerebral gunshot wounds. *Emerg Med J* 2005;22:409–10. [\[CrossRef\]](#)
- Gönül E, Akbörü M, Izci Y, Timurkaynak E. Orbital foreign bodies after penetrating gunshot wounds: retrospective analysis of 22 cases and clinical review. *Minim Invasive Neurosurg* 1999;42:207–11. [\[CrossRef\]](#)
- Vourc'h G. Continuous cerebrospinal fluid drainage by indwelling spinal catheter. *Br J Anaesth* 1963;35:118–20. [\[CrossRef\]](#)
- Graf CJ, Gross CE, Beck DW. Complications of spinal drainage in the management of cerebrospinal fluid fistula. *J Neurosurg* 1981;54:392–5.
- Kitchel SH, Eismont FJ, Green BA. Closed subarachnoid drainage for management of cerebrospinal fluid leakage after an operation on the spine. *J Bone Joint Surg Am* 1989;71:984–7. [\[CrossRef\]](#)
- Roland PS, Marple BF, Meyerhoff WL, Mickey B. Complications of lumbar spinal fluid drainage. *Otolaryngol Head Neck Surg* 1992;107:564–9.
- Shapiro SA, Scully T. Closed continuous drainage of cerebrospinal fluid via a lumbar subarachnoid catheter for treatment or prevention of cranial/spinal cerebrospinal fluid fistula. *Neurosurgery* 1992;30:241–5.
- Fishman AJ, Hoffman RA, Roland JT Jr, Lebowitz RA, Cohen NL. Cerebrospinal fluid drainage in the management of CSF leak following acoustic neuroma surgery. *Laryngoscope* 1996;106:1002–4. [\[CrossRef\]](#)
- Alagöz F, Dağlıoğlu E, Korkmaz M, Yıldırım AE, Uçkun ÖM, Divanlioğlu D, et al. Surgical management of traumatic cerebrospinal fluid fistulas with associated lesions. *Ulus Travma Acil Cerrahi Derg* 2015;21:450–6.
- Secer HI, Kural C, Kaplan M, Kilic A, Duz B, Gonul E, et al. Comparison of the efficacies of antibiotic-impregnated and silver-impregnated ventricular catheters on the prevention of infections. An in vitro laboratory study. *Pediatr Neurosurg* 2008;44:444–7. [\[CrossRef\]](#)
- Izci Y, Secer H, Akay C, Gonul E. Initial experience with silver-impregnated polyurethane ventricular catheter for shunting of cerebrospinal fluid in patients with infected hydrocephalus. *Neurol Res* 2009;31:234–7.
- Baysallar M, Izci Y, Kilic A, Avci IY, Senses Z, Doganci L. A case of ventricular drainage infection with a rare pathogen in cerebrospinal fluid: vancomycin-resistant *Enterococcus faecium*. *Microb Drug Resist* 2006;12:59–62. [\[CrossRef\]](#)

ORJİNAL ÇALIŞMA - ÖZET

Posttravmatik beyin omurilik sıvısı fistüllerinde kontinü lomber drenajın etkinliği

Dr. Alparslan Kırık, Dr. Soner Yaşar

Sağlık Bilimleri Üniversitesi, Gülhane Eğitim ve Araştırma Hastanesi, Beyin ve Sinir Cerrahisi Anabilim Dalı, Ankara

AMAÇ: Kliniğimizde yatırılarak kontinü lomber drenaj (KLD) uygulanan posttravmatik beyin omurilik sıvısı (BOS) fistülü olan hastaların klinik sonuçlarını araştırmak ve bunu non-travmatik nedenlerle KLD uygulanan hastalarla karşılaştırmaktır.

GEREÇ VE YÖNTEM: Ocak 2018–Aralık 2019 tarihleri arasında beyin ve sinir cerrahisi kliniğine yatırılan ve KLD takılan hastaların dosyası incelendi. Bu hastaların tanısı, demografik özellikleri, BOS sonuçları ve klinik sonuçları değerlendirildi. Travma nedeniyle dura defekti ve BOS fistülü olan hastaların sonuçları diğer sebeplerle BOS fistülü olan ve lomber drenaja alınan hastalarla karşılaştırıldı.

BULGULAR: Toplam 45 hastaya 51 kez KLD uygulandı. Hastalardaki yaş ortalaması 38.84 yıl olup hastaların 27'si (%60) erkek idi. Yedi (%15.55) hastaya posttravmatik BOS fistülü nedeniyle, 38 hastaya ise tümör veya malformasyon cerrahisi sonrası KLD uygulandı. Beş hastada ateşli silah yaralanması (ASY) sonrası dura defektine bağlı BOS fistülü gelişmiş iken iki hastada trafik kazası sonrası BOS fistülü gözlenmiştir. *Staphylococcus epidermidis* posttravmatik BOS fistülü olan bir hastada, *Serratia marcescens* ise posterior fossa tümörüne sekonder BOS fistülü olan hastada üremiştir. Posttravmatik KLD uygulan yedi hastadan hiçbirisi takip sürecinde ölmüş iken tümörlere bağlı KLD uygulan hastalarda bir tanesi takip sürecinde sepsisten dolayı kaybedilmiştir.

TARTIŞMA: Posttravmatik BOS fistüllerinde KLD uygulaması güvenli ve etkili bir tedavi yöntemidir. Özellikle ateşli silah yaralanmalı hastalarda BOS fistülünün tedavisinde revizyon cerrahisi yapılmadan önce mutlaka KLD uygulanmalıdır. Daha geniş travma gruplarında daha farklı parametreler ile yapılacak çalışmalara ihtiyaç vardır.

Anahtar sözcükler: Beyin omurilik sıvısı kaçağı; kontinü lomber drenaj; travma; tümör.

Ulus Travma Acil Cerrahi Derg 2020;26(5):784-788 doi: 10.14744/tjtes.2020.26446