

# The effects of sildenafil and N-acetylcysteine the zone of stasis in burns

Meriç Emre Bostancı, M.D.,<sup>1</sup> Ceylan Hepokur, M.D.,<sup>2</sup> Erol Kisli, M.D.<sup>3</sup>

<sup>1</sup>Department of Surgical Oncology, Sivas Cumhuriyet University Faculty of Medicine, Sivas-Turkey

<sup>2</sup>Department of Biochemistry, Sivas Cumhuriyet University Faculty of Pharmacy, Sivas-Turkey

<sup>3</sup>Department of General Surgery, Sivas Cumhuriyet University Faculty of Medicine, Sivas-Turkey

## ABSTRACT

**BACKGROUND:** In burn wound healing, zones of burn, namely zone of hyperemia, the zone of stasis, and zone of coagulation, have crucial importance. These zones have been identified based on the pathophysiology of the burn, and treatment of burn has been improved. The zone of necrosis is treated by excision and repair through grafting. Zone of stasis fully recovers in 24–48 h if the burn treatment is managed well. Otherwise, it may convert to a zone of coagulation. Hyperemia zone is a zone that recovers itself. Recovery of the zone of stasis is very critical in burn treatment. Active oxygen radicals produced due to the hypermetabolism due to burn wounds are known to speed to the process of the zone of stasis converting into the zone of coagulation. The present experimental study aims to evaluate the effects of sildenafil and N-acetylcysteine on the zone of stasis and to establish whether they had any contribution to wound healing in burns.

**METHODS:** In the present study, 32 four months old female Wistar Albino rats with 200±20 gr body weights were used. The rats were divided into four groups as the sham group (Group 1), the intraperitoneal group (Group 2), Sildenafil group (Group 3, intraperitoneal 10 mg/kg for 10 days), N-acetylcysteine (Group 4, intraperitoneal 100 mg/kg for 10 days). Tissue samples were collected for serum and cytopathology studies of the Malondialdehyde level, glutathione peroxidase, superoxide dismutase, and catalyze enzyme activity. All the rats were sacrificed on the 10<sup>th</sup> day of the tests edema, hyperemia, epithelial degeneration, necrosis, inflammatory infiltration and fibrosis measurements were made.

**RESULTS:** When compared with the controls, both of the treatment groups had lower tissue damage scores. MDA level was lower in Group 3 and 4 compared to Group 2 and lower in Group 3 compared to Group 4. SOD, catalase and GPH-Px levels were higher in Group 3 and Group 4 compared to Group 2 and higher in Group 3 compared to Group 4.

**CONCLUSION:** The results of our study conducted on an experimental burn model created by rats support that Sildenafil and N-acetylcysteine have positive effects, such as decreasing oxidative stress level and increasing wound healing in burns. Further experimental studies are required on this subject.

**Keywords:** N-acetylcysteine; sildenafil; zone of stasis in burns; wound healing.

## INTRODUCTION

Burn is one of the most important physical and psychological traumas that mankind may face all over the world. Morbidity and mortality due to burns remain an important health problem. Jackson described that each other surrounding sites of three injuries in the first 24 hours of acute burns.<sup>[1]</sup> The first zone is the coagulation zone, which is directly exposed

to heat. The coagulation zone that is present at the center of the damage is not self-renewing. The second zone is the stasis zone surrounding the coagulation zone. The third zone is the hyperemia zone without dermal damage located outside the area of the injury. The zone of hyperemia with increased blood circulation and metabolism is a region that can be completely healed. Stasis zone between coagulation and hyperemia zones is a region where blood flow is reduced due

Cite this article as: Bostancı ME, Hepokur C, Kisli E. The effects of sildenafil and N-acetylcysteine the zone of stasis in burns. *Ulus Travma Acil Cerrahi Derg* 2021;27:9-16.

Address for correspondence: Meriç Emre Bostancı, M.D.

Sivas Cumhuriyet Üniversitesi Tıp Fakültesi, Cerrahi Onkoloji Bilim Dalı, Sivas, Turkey

Tel: +90 346 - 219 11 56 E-mail: drmericembostanci@gmail.com



*Ulus Travma Acil Cerrahi Derg* 2021;27(1):9-16 DOI: 10.14744/tjtes.2020.25679 Submitted: 25.11.2019 Accepted: 16.03.2020 Online: 16.12.2020

Copyright 2021 Turkish Association of Trauma and Emergency Surgery

to ischemia.<sup>[2,3]</sup> This area is exposed to oxidative stress due to ischemia-reperfusion injury in the stasis zone.<sup>[3]</sup> Reperfusion injury predominantly causes apoptotic cell death and increased apoptosis in the stasis zone results in progressive tissue loss.<sup>[4]</sup> Damage characterized by inflammation and edema is less in the stasis zone. Circulation progressively deteriorates in this region and this leads to the development of ischemia and death of the cells. In some cases, the stasis zone can be completely transformed into scar tissue. To prevent the vitality of the cells in the zone of stasis, supportive treatment of the patient should not be delayed. If appropriate conditions are provided, cells in the zone of stasis regain viability within a week.<sup>[5]</sup> However, even if healing occurs, epithelial cell loss is high in this zone. During recovery, cells are hypersensitive to damage. When the stasis zone that is healing potential is not treated, blood circulation stops completely in time and necrosis develops.<sup>[6]</sup> Recovery of the burn stasis zone is the basis of the researches about burn treatment.<sup>[2,7]</sup> Rescue of the zone of stasis prevents the increase in depth and width of the damage in the burn area.<sup>[8]</sup>

N-Acetylcysteine (NAC), which is a thiol molecule, is a precursor of L- cysteine and reduced glutathione. NAC is the source of sulfhydryl groups in cells and removes free radicals by interacting with reactive oxygen radicals, such as OH<sup>-</sup>. The various diseases in which NCA is used include cancer, cardiovascular diseases, metal toxicity and paracetamol toxicity of the liver.<sup>[9]</sup> NAC can prevent apoptosis, regulate the activity of various proteins and so prolong cell survival. NAC; Reduces endothelial dysfunction, delays inflammation, fibrosis, invasion, cartilage erosion, acetaminophen detoxification and transplantation requirement.<sup>[10]</sup> Possible antitoxicity mechanisms include increased liver blood flow, increased glutathione and free radical scavenging.<sup>[11]</sup> With its currently known efficacy, NAC may play a therapeutic role in transplantation damage, alcoholism and metal toxicity with its therapeutic effect against oxidative stress in the liver.<sup>[9]</sup> Many animal models have been proposed to investigate the pathology, local, systemic treatment of burn wound and the effect of burn trauma on the whole organism.<sup>[12]</sup> In experimental models, the implementation of oxygen radical scavengers before or after sepsis has been shown to increase survival.<sup>[13]</sup> NAC is an antioxidant that is a sulfhydryl donor and promotes glutathione regeneration. Many studies show that NAC is important in micro circular blood flow and tissue oxygenation.<sup>[13]</sup>

Sildenafil citrate is a selective inhibitory. Phosphodiesterase enzyme type 5 (PDE5) effectively inactivates cyclic guanosine monophosphate (cGMP). Sildenafil is a phosphodiesterase inhibitor and used in vasodilatation. Sildenafil accelerates blood flow by relaxing smooth muscles and stimulating cellular and endothelial nitric oxide (NO) release. NO has a positive effect on angiogenesis, inflammation, endothelial and epithelial cell proliferation mechanisms on wound healing.<sup>[14]</sup> The present study aims to compare the efficacy of the phospho-

diesterase inhibitor (sildenafil) and N-acetylcysteine on the stasis zone and its biochemical/pathological findings after treatment.

## MATERIALS AND METHODS

### Materials

This research was conducted in the Sivas Cumhuriyet University Animal Laboratory in accordance with the guidelines of Sivas Cumhuriyet University Animal Experiments Local Ethics Committee. This research was conducted in accordance with ethical rules with the decision of Sivas Cumhuriyet University Animal Experiments Local Ethics Committee dated 02.07.2015 and numbered 65202830-050.04/04/58.

Female healthy rats (200±20 g) (n=32) that were 16-18 weeks were used in this study. Rats were fed with a standard laboratory diet. The rats were kept in such a way that they could always drink according to their drinking water requirements. Rats were housed with eight animals in each cage. Rats capable of normal activities in cages were kept in rooms set at 22±20°C, humidity (P-70) and 12 h day/night. All rats were kept under observation for a few days before the study to see if they were healthy. Rats were divided into four equal groups. Group 1; sham group, group 2; control group, group 3; sildenafil treated group, group 4; N-acetylcysteine.

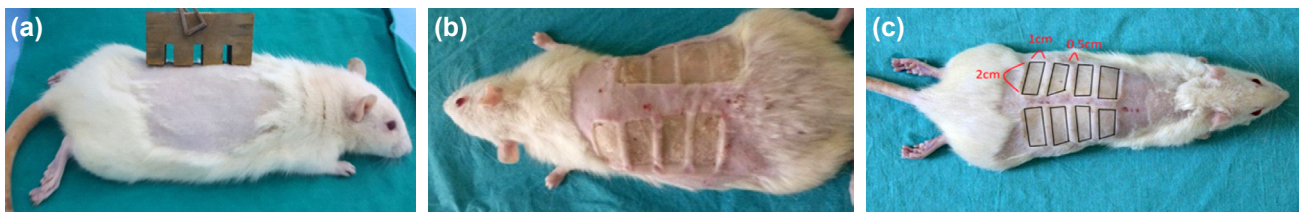### Animal Model

The skin on the back of the rats was shaved it hairless. The rats were subjected to an experimental burn model described by Regas and Ehrlich under anesthesia. Specially made of brass plate with four handles 10x20 mm and three cavities 5x20 mm between them. It was kept in boiling water at 100°C for three min and contacted with its own weight without creating pressure for 30 s in the middle line of the animals in the dorsal region. After the procedure, second degree burns of 10x20 mm in four and stasis zones of 5x20 mm in three were formed in the hairless back of rats (Fig. 1a-c).<sup>[15]</sup>

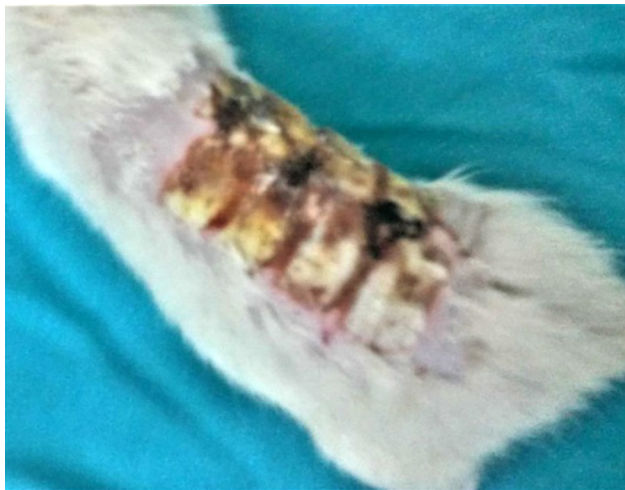Sildenafil at a dose of 10 mg/kg, N-acetylcysteine at a dose of 100 mg/kg were administered intraperitoneal once daily for 10 days.

At the end of the 10-day treatment program, 5 cc cardiac blood was collected from the rats by Waynforth H.B. and Flecknell method using a closed puncture method and a green tip injector under the xiphoid. Then, as soon as the neck was sacrificed by dislocation, 6 mm diameter full-thickness skin tissue samples were taken from the wound site (Fig. 2).

Half of the skin tissue samples were divided into half for biochemical analysis and a half for histopathological examination and kept at -20°C until the day of analysis. Blood samples were centrifuged at 4000 rpm for 10 min and they were stored at -20°C until the day of analysis.



**Figure 1.** (a-c) The probe that was used in the comb model and the dorsum of a rat after burn. (a) The probe that was used in the comb model. (b) The burn-injured areas. (c) Size of burn areas.



**Figure 2.** The final burn scars at the time of the sacrifice.

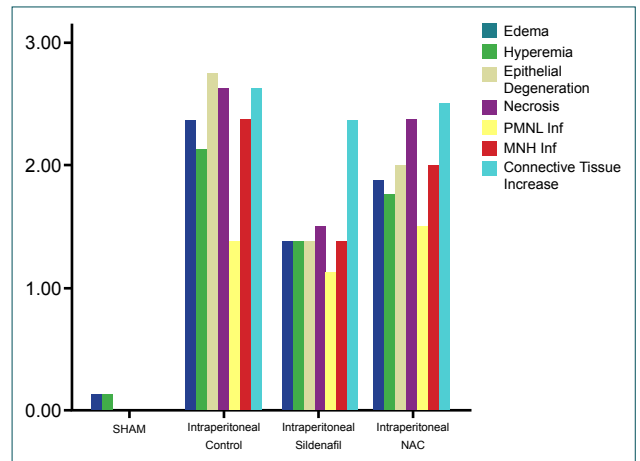
Tissue samples were homogenized with a tissue homogenizer (Bioprep24, Allsheng). Homogenized samples were first centrifuged at 2500 g at + 4°C for 10 min (Hermle Z326K). After centrifugation, the supernatant was centrifuged again at 20000g for 20 min at + 4°C to obtain samples.

MDA levels and SOD, GPx and CAT enzyme activity were studied in serum and tissue samples. MDA Janero (1998),<sup>[16]</sup> SOD Sun et al. (1988),<sup>[17]</sup> GPx Paglia and Valentine (1967)<sup>[18]</sup> and catalase Aebi (1984)<sup>[19]</sup> were investigated by the methods.

At the end of this study, wound tissue samples from each group were placed in 10% buffered formalin solution. Tissues were blocked in paraffin and 6 micron thick sections were taken. Sections were stained with Hematoxylin-eosin (HE). Epidermis and dermis were evaluated histopathologically using optical microscope (Leica, DM 4000B) for each group. The lesions were scored according to the Modified Greenhalgh's Wound Healing Scoring System (Abramov et al., 2007)<sup>[20]</sup> (0 = none, 1 = mild, 2 = moderate, 3 = intensive).

### Statistical Analysis

The data obtained from our study were evaluated with SPSS (Ver: 22.0) program. Since the parametric test assumptions could not be fulfilled (Kolmogorov-Smirnov test), the Kruskal Wallis test and Mann-Whitney U test were used and the error level was taken as 0.05.



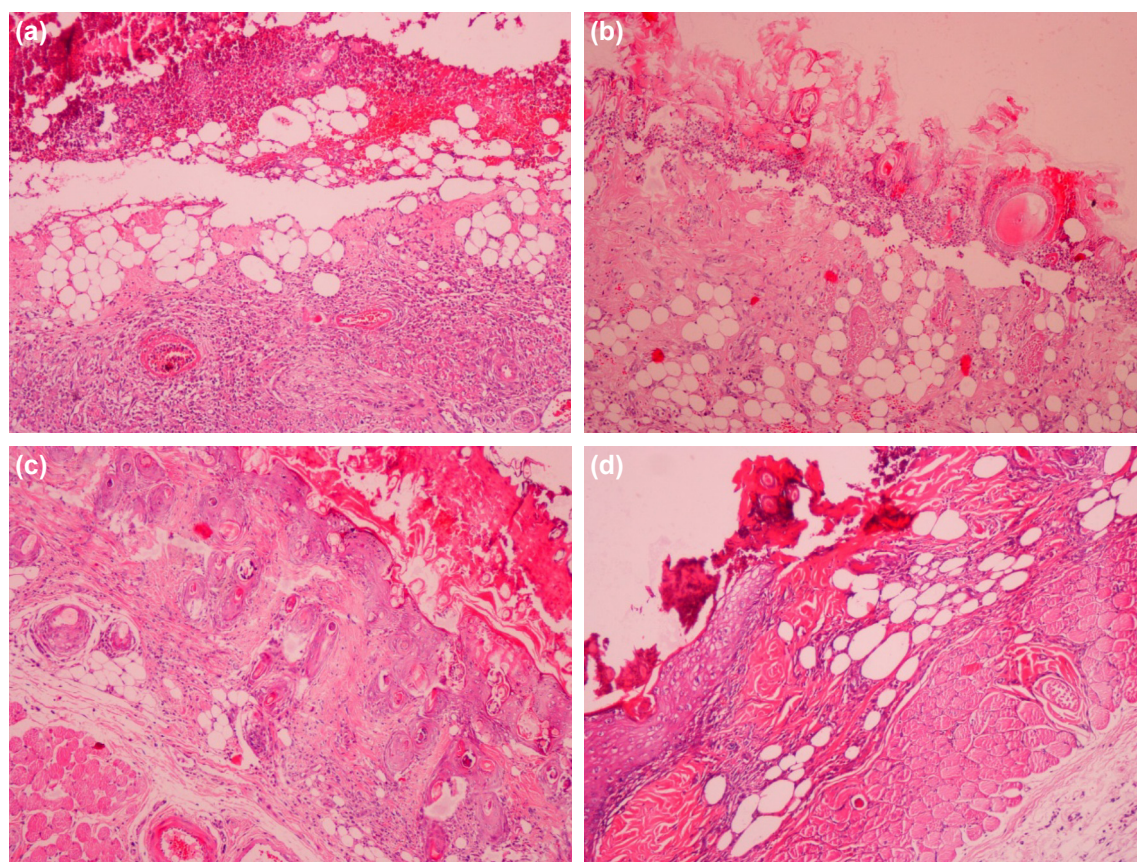
**Figure 3.** Comparison of the histopathological damage score between groups.

## RESULTS

In the study groups, histopathological parameters, such as edema, hyperemia, epithelial degeneration, necrosis, mononuclear cell (MNC) infiltration, polymorphonuclear leukocyte (PMNL) infiltration and increased connective tissue, were scored between 0 and 3. The comparison of the histopathological damage score between the groups is shown in Figure 3. Histopathological images of the groups are given in Figure 4.

In the NAC and Sildenafil groups, less vascular proliferation, fibrosis, necrosis, edema, and inflammatory infiltration were examined under the epithelium.

There was a statistically significant difference between the groups concerning edema, hyperemia, epithelial degeneration, necrosis, PMNL infiltration, and MNC infiltration intensity ( $p < 0.05$ ). The reason for this difference may be the concentration of the sildenafil group in mild edema, the NAC group is concentrated in moderate edema, and the control group is concentrated in moderate and intensive edema. When all groups were compared concerning connective tissue increase, amatory infiltration more statistically significant difference was observed ( $p < 0.05$ ). The reason for this difference is that the sildenafil group has moderate and dense distribution while the control and NAC groups have mild, moderate and intense connective tissue increase.



**Figure 4.** (a-c) Under the epithelium vascular proliferation, fibrosis, necrosis, edema, and inflammatory infiltration were more significant in the control and sham groups. (a) Sham Group, (b) Control Group, (c) NAC Group, (d) Sildenafil Group.

MDA level, SOD, Cat, and Gpx enzyme activity were studied in tissue samples taken from rats. The values obtained were compared with sham and control and given in Tables I-4.

Serum samples between sham and control groups; MDA, SOD, Cat, and GPx values were compared with the Mann-Whitney U test and a statistically significant difference was found ( $p < 0.05$ ).

In serum samples of the control group and intraperitoneal sildenafil treated rats, MDA, SOD, Cat, GPx values were

compared with the Mann-Whitney U test and statistically significant difference was found ( $p < 0.05$ ).

In the control group and intraperitoneal NAC treated rats, MDA, SOD, Cat, GPx values were compared with the Mann-Whitney U test and a statistically significant difference was found ( $p < 0.05$ ).

In the intraperitoneal sildenafil treated group and intraperitoneal NAC treated rats; MDA, SOD, Cat, and GPx values were compared with the Mann-Whitney U test and statistically significant difference was found ( $p < 0.05$ ).

**Table I.** Comparison of MDA level, SOD, Cat and GPX enzyme activities in Sham and control groups

Groups	MDA ( $\mu\pm SD$ )	SOD ( $\mu\pm SD$ )	Cat ( $\mu\pm SD$ )	GPx ( $\mu\pm SD$ )
Sham (min-max)	2.86 $\pm$ 0.52 1.90-3.44	14.60 $\pm$ 16.12 4.50-50.28	6.23 $\pm$ 3.09 2.49-10.72	93.59 $\pm$ 35.29 40.63-136.27
Control (min-max)	8.90 $\pm$ 1.81 6.73-11.98	9.88 $\pm$ 2.52 7.44-13.91	10.16 $\pm$ 5.13 5.06-19.23	35.11 $\pm$ 15.71 15.57-58.28
Result	MW=28.000 $p=0.001$	MW=50.000 $p=0.805$	MW=40.000 $p=0.128$	MW=31.000 $p=0.004$

MDA: Formaldehyde; SOD: Superoxide dismutase; Cat: Catalase; Gpx: Glutathione peroxidase; MW: Molecular weight; SD: Standard deviation.

**Table 2.** Comparison of MDA, SOD, Cat, and GPx values in the post-burn control group and intraperitoneal sildenafil group

Groups	MDA ( $\mu\pm SD$ )	SOD ( $\mu\pm SD$ )	Cat ( $\mu\pm SD$ )	GPx ( $\mu\pm SD$ )
i.p. Control (min-max)	8.90 $\pm$ 1.81 6.73–11.98	9.88 $\pm$ 2.52 7.44–13.91	10.16 $\pm$ 5.13 5.06–19.23	35.11 $\pm$ 15.71 15.57–58.28
i.p. Sildenafil (min-max)	3.63 $\pm$ 0.92 2.79–5.51	23.60 $\pm$ 8.72 13.29–39.87	47.07 $\pm$ 29.81 12.54–89.97	204.87 $\pm$ 142.32 62.93–461.47
Result	MW=28.000 p=0.002	MW=29.000 p=0.003	MW=30.000 p=0.004	MW=28.000 p=0.002

MDA: Formaldehyde; SOD: Superoxide dismutase; Cat: Catalase; Gpx: Glutathione peroxidase; MW: Molecular weight; SD: Standard deviation.

**Table 3.** Comparison of MDA, SOD, Cat, and GPx values in the post-burn control group and intraperitoneal N-acetylcysteine group

Groups	MDA ( $\mu\pm SD$ )	SOD ( $\mu\pm SD$ )	Cat ( $\mu\pm SD$ )	GPx ( $\mu\pm SD$ )
i.p. Control (min-max)	8.90 $\pm$ 1.81 6.73–11.98	9.88 $\pm$ 2.52 7.44–13.91	10.16 $\pm$ 5.13 5.06–19.23	35.11 $\pm$ 15.71 15.57–58.28
i.p. N-acetyl cysteine (min-max)	6.00 $\pm$ 0.64 5.04–6.79	14.29 $\pm$ 2.75 10.86–17.72	31.66 $\pm$ 13.81 11.58–54.81	65.65 $\pm$ 26.85 38.46–118.86
Result	MW=29.000 p=0.003	MW=34.000 p=0.018	MW=31.000 p=0.006	MW=35.000 p=0.025

MDA: Formaldehyde; SOD: Superoxide dismutase; Cat: Catalase; Gpx: Glutathione peroxidase; MW: Molecular weight; SD: Standard deviation.

**Table 4.** Comparison of the MDA, SOD, Cat, and GPx values in the post-burn intraperitoneal sildenafil group and intraperitoneal N-acetylcysteine group

Groups	MDA ( $\mu\pm SD$ )	SOD ( $\mu\pm SD$ )	Cat ( $\mu\pm SD$ )	GPx ( $\mu\pm SD$ )
i.p. Sildenafil (min-max)	3.63 $\pm$ 0.92 2.79–5.51	23.60 $\pm$ 8.72 13.29–39.87	47.07 $\pm$ 29.81 12.54–89.97	204.87 $\pm$ 142.32 62.93–461.47
i.p. N-acetyl cysteine (min-max)	6.00 $\pm$ 0.64 5.04–6.79	14.29 $\pm$ 2.75 10.86–17.72	31.66 $\pm$ 13.81 11.58–54.81	65.65 $\pm$ 26.85 38.46–118.86
Result	MW=30.000 p=0.004	MW=33.000 p=0.011	MW=45.000 p=0.338	MW=32.500 p=0.011

MDA: Formaldehyde; SOD: Superoxide dismutase; Cat: Catalase; Gpx: Glutathione peroxidase; MW: Molecular weight; SD: Standard deviation.

## DISCUSSION

It has been shown in an experimental study that activating protein C on the burn stasis zone increases blood flow rates.<sup>[21]</sup> Melatonin, a pineal hormone, is a potent liberator of oxygen radicals and activates endogenous antioxidant defense proteins. Wound healing and burn stasis zone healing by eliminating the negative effect of oxygen radicals have been shown to have a positive effect on burn wound healing.<sup>[22]</sup> NAC is a commonly used mucolytic in the clinic and its effects on burn injury as a GSH precursor have been studied in the literature. NAC can prevent apoptosis, regulate the activity of various proteins and prolong cell survival. NAC reduces endothelial dysfunction and provides inflammation, fibrosis, cartilage ero-

sion, acetaminophen detoxification, and delayed transplantation needs.<sup>[10]</sup> Possible mechanisms of antitoxicity include increased liver blood flow, increased glutathione, and clearing free radicals.<sup>[11]</sup> NAC is an antioxidant that is a sulfhydryl donor and promotes glutathione regeneration. Many studies suggest that NAC is important in micro-circular blood flow and tissue oxygenation.<sup>[13]</sup> It has been shown that the use of NAC in animals with burn injury improves cellular immunity and reduces mucosal damage by decreasing the increased level of MDA in small bowel tissue.<sup>[23,24]</sup> Similarly, after 24-hour burn, NAC treatment decreases the increased MDA level in lung tissue, increases GSH level and thus reduces oxidative stress.<sup>[25]</sup> In a study, the effect of NAC on preventing necrosis

in the stasis zone was investigated. It was observed that stasis zone necrosis was very low in the NAC treatment group compared to the control group. To show the antioxidant effect of NAC, malondialdehyde levels measured in tissue did not show any abnormal difference between the treated groups and the control group.<sup>[26]</sup> Zor et al. have shown that glutathione has a liberating effect on the stasis zone by nuclear imaging and autoradiography.<sup>[11]</sup> In another study, it was shown that superoxide dismutase, which is an antioxidant, has an effect on the recovery of stasis zone in burned rats.<sup>[27]</sup> Sildenafil is an agent that supports NO activity of cyclic guanosine monophosphate (cGMP) and was initially used as an antihypertensive agent.<sup>[28]</sup> In wound healing of nitric oxide; strengthening of the coagulation process,<sup>[29]</sup> removal of oxidative stress components,<sup>[30]</sup> angiogenesis improvement,<sup>[31]</sup> endothelial cell proliferation support,<sup>[32,33]</sup> and in tissue remodeling,<sup>[34]</sup> beneficial effects have been shown. The role of NO in vasodilatation regulation,<sup>[35]</sup> cell cycle and apoptosis control,<sup>[36]</sup> cell proliferation and differentiation,<sup>[37]</sup> oxygen distribution enhancement<sup>[38]</sup> and antimicrobial<sup>[39]</sup> mechanisms have been described. In our study, edema, hyperemia, epithelial degeneration, necrosis, inflammatory infiltration and fibrosis were measured pathologically. Compared with the control group, the tissue damage score was lower in the intraperitoneal NAC group. MDA levels were lower in the intraperitoneal NAC group compared to the control group. SOD, Catalase, and GSH-Px enzyme activities were higher in intraperitoneal NAC group than control group. MDA levels were lower in intraperitoneal sildenafil group than the intraperitoneal NAC group. SOD, catalase, GSH-Px enzyme activities were higher in intraperitoneal sildenafil group than the intraperitoneal NAC group.

Jamshidzadeh et al.<sup>[40]</sup> reported that the use of topical sildenafil increased macrophage and fibroblast migration, revascularization, collagen regeneration and epithelialization. They also observed increased subcutaneous fibroblast infiltration on day 7<sup>th</sup>, collagen regeneration from the subscriber on day 14<sup>th</sup>, and increased epithelialization, especially on days 14–21<sup>th</sup>. Therefore, they stated that topical sildenafil use is effective in wound healing. Salcido et al.<sup>[41]</sup> Reported that sildenafil increases NO secretion that makes vasodilatation in the cellular and endovascular space and thus increases blood flow. They stated that increased NO release has multiple positive effects on wound healing, such as angiogenesis, inflammation, endothelial and epithelial cell proliferation, and remodeling. Sarifakioglu et al.<sup>[42]</sup> reported that NO and cGMP are the ideal biomechanical balance to support wound healing with increased blood flow and stated that sildenafil improves postoperative skin flap survival. Derici et al.<sup>[43]</sup> expressed that sildenafil can be used as a supporting factor in wound healing due to their experimental study. In their study, Farsaei et al.<sup>[44]</sup> stated that the effectiveness of sildenafil alone or in combination with other agents should be investigated in different wound types. They have reported that sildenafil can be used as a salvage treatment in patients whose contraindications

are contraindicated in patients who do not respond to conventional treatment. When the control group and intraperitoneal sildenafil group were compared, the tissue damage score was lower in the intraperitoneal sildenafil group. MDA levels in the intraperitoneal sildenafil group were lower than the control group. SOD, catalase, and GSH-Px levels were higher in the intraperitoneal sildenafil group compared to control group. MDA levels were lower in the intraperitoneal sildenafil group than the intraperitoneal NAC group. SOD, catalase, GSH-Px levels were higher in the intraperitoneal sildenafil group than the intraperitoneal NAC group.

When the sildenafil and N-acetylcysteine groups were compared, it was observed that the histopathological healing findings were better in the sildenafil group. When sildenafil and N-acetylcysteine groups were compared, the positive effects of sildenafil on reducing oxidative stress and wound healing were more pronounced than N-acetylcysteine. In this study, intraperitoneal sildenafil administration was superior to intraperitoneal N-acetylcysteine administration on wound healing in an experimental wound model.

## Conclusion

The effects of sildenafil on the stasis zone should be investigated by experimental studies and considered as a molecule that can be used for active clinical use.

**Acknowledge:** Nil.

**Ethics Committee Approval:** Approved by the local ethics committee (date: 02.07.2015, no: 65202830-050.04.04/58).

**Peer-review:** Internally peer-reviewed.

**Authorship Contributions:** Concept: M.E.B., E.K., C.H.; Design: M.E.B., E.K., C.H.; Supervision: M.E.B., E.K., C.H.; Resource: M.E.B., E.K., C.H.; Materials: M.E.B., E.K., C.H.; Data: M.E.B., C.H.; Analysis: M.E.B., C.H.; Literature search: M.E.B., E.K., C.H.; Writing: M.E.B., C.H.; Critical revision: M.E.B., E.K.

**Conflict of Interest:** None declared.

**Financial Disclosure:** The authors declared that this study has received no financial support.

## REFERENCES

1. Jackson DM. The diagnosis of the depth of burning. *Br J Surg* 1953;40:588–96. [\[CrossRef\]](#)
2. Mahajan AL, Tenorio X, Pepper MS, Baetens D, Montandon D, Schlaudraff KU, et.al. Progressive tissue injury in burns is reduced by rNAPc2. *Burns* 2006;32:957–63. [\[CrossRef\]](#)
3. Jackson DM. Second thoughts on the burn wound. *J Trauma* 1969;9:839–62. [\[CrossRef\]](#)
4. Evers LH, Bhavsar D, Mailänder P. The biology of burn injury. *Exp Dermatol* 2010; 19:777–83. [\[CrossRef\]](#)
5. Sparkes BG. Immunological responses to thermal injury. *Burns* 1997;23:106–13. [\[CrossRef\]](#)
6. Singer AJ, McClain SA, Taira BR, Rooney J, Steinhaff N, Rosenberg L. Rapid and selective enzymatic debridement of porcine comb burns with bromelain-derived Debrase: acute-phase preservation of noninjured tis-

- sue and zone of stasis. *J Burn Care Res* 2010;31:304–9. [\[CrossRef\]](#)
7. Zor F, Ozturk S, Devci M, Karacalioglu O, Sengezer M. Saving the zone of stasis: is glutathione effective?. *Burns* 2005;31:972–6. [\[CrossRef\]](#)
  8. Holmes JC, Heimbach DM, Brunicardi FC, Andersen DK, et al. In: Brunicardi FC, Andersen DK, Billiar TR, Dunn D, Hunter J, Pollock RE, editors. *Schwartz's Principles of Surgery*. 8th edition. McGraw-Hill Medical Publishing Division; 2005.p.189–221.
  9. Zafarullah M, Li WQ, Sylvester J, Ahmad M. Molecular mechanisms of N-acetylcysteine actions. *Cell Mol Life Sci* 2003;60:6–20. [\[CrossRef\]](#)
  10. Foresti R, Sarathchandra P, Clark JE, Green CJ, Motterlini R. Peroxynitrite induces haem oxygenase-1 in vascular endothelial cells: a link to apoptosis. *Biochem J* 1999;339:729–36. [\[CrossRef\]](#)
  11. Jones AL. Mechanism of action and value of N-acetylcysteine in the treatment of early and late acetaminophen poisoning: a critical review. *J Toxicol Clin Toxicol* 1998;36:277–85. [\[CrossRef\]](#)
  12. Campelo AP, Campelo MW, Britto GA, Ayala AP, Guimarães SB, Vasconcelos PR. An optimized animal model for partial and total skin thickness burns studies. *Acta Cir Bras* 2011;26:38–42. [\[CrossRef\]](#)
  13. Cuzzocrea S, Mazzon E, Costantino G, Serraino I, Dugo L, Calabrò G, et al. Beneficial effects of n-acetylcysteine on ischaemic brain injury. *Br J Pharmacol* 2000;130:1219–26. [\[CrossRef\]](#)
  14. Iseri SO, Ersoy Y, Ercan F, Yuksel M, Atukeren P, Gumustas K, et al. The effect of sildenafil, a phosphodiesterase-5 inhibitor, on acetic acid-induced colonic inflammation in the rat. *J Gastroenterol Hepatol* 2009;24:1142–8. [\[CrossRef\]](#)
  15. Regas FC, Ehrlich HP. Elucidating the vascular response to burns with a new rat model. *J Trauma* 1992;32:557–63. [\[CrossRef\]](#)
  16. Janero DR. Malondialdehyde and thiobarbituric acid-reactivity as diagnostic indices of lipid peroxidation and oxidativative tissue injury. *Free Radic Biol Med* 1990;9:515–40. [\[CrossRef\]](#)
  17. Sun Y, Oberley LW, Li Y. A simple method for clinical assay of superoxide dismutase. *Clin Chem* 1988;34:497–500. [\[CrossRef\]](#)
  18. Paglia DE, Valentine WN. Studies on the quantitative and qualitative characterization of erythrocyte glutathione peroxidase. *J Lab Clin Med* 1967;70:158–69.
  19. Aebi H. Catalase in vitro. *Methods Enzymol* 1984;105:121–6. [\[CrossRef\]](#)
  20. Abramov Y, Golden B, Sullivan M, Botros SM, Miller JJ, Alshahrour A, et al. Histologic characterization of vaginal vs. abdominal surgical wound healing in a rabbit model. *Wound Repair Regen* 2007;15:80–6. [\[CrossRef\]](#)
  21. Nisanci M, Eski M, Sahin I, Ilgan S, Isik S. Saving the zone of stasis in burns with activated protein C: an experimental study in rats. *Burns* 2010;36:397–402. [\[CrossRef\]](#)
  22. Fujimoto T, Nakamura T, Ikeda T, Takagi K. Potent protective effects of melatonin on experimental spinal cord injury. *Spine (Phila Pa 1976)* 2000;25:769–75. [\[CrossRef\]](#)
  23. Ocal K, Avlan D, Cinel I, Unlu A, Ozturk C, Yaylak F, et al. The effect of N-acetylcysteine on oxidative stress in intestine and bacterial translocation after thermal injury. *Burns* 2004;30:778–84. [\[CrossRef\]](#)
  24. Cetinkale O, Senel O, Bulan R. The effect of antioxidant therapy on cell-mediated immunity following burn injury in an animal model. *Burns* 1999;25:113–8. [\[CrossRef\]](#)
  25. Konukoğlu D, Cetinkale O, Bulan R. Effects of N-acetylcysteine on lung glutathione levels in rats after burn injury. *Burns* 1997;23:541–4. [\[CrossRef\]](#)
  26. Deniz M, Borman H, Seyhan T, Haberal M. An effective antioxidant drug on prevention of the necrosis of zone of stasis: N-acetylcysteine. *Burns* 2013;39:320–5. [\[CrossRef\]](#)
  27. Shalom A, Kramer E, Westreich M. Protective effect of human recombinant copper-zinc superoxide dismutase (hr-cuznsod) on intermediate burn survival in rats. *Ann Burns Fire Disasters* 2008;21:16–9.
  28. Webb DJ, Freestone S, Allen MJ, Muirhead GJ. Sildenafil citrate and blood-pressure-lowering drugs: results of drug interaction studies with an organic nitrate and a calcium antagonist. *Am J Cardiol* 1999;83:21C–8C.
  29. Chung AW, Radomski A, Alonso-Escolano D, Jurasz P, Stewart MW, Malinski T, et al. Platelet-leukocyte aggregation induced by PAR agonists: regulation by nitric oxide and matrix metalloproteinases. *Br J Pharmacol* 2004;143:845–55. [\[CrossRef\]](#)
  30. Soneja A, Drews M, Malinski T. Role of nitric oxide, nitrooxidative and oxidative stress in wound healing. *Pharmacol Rep* 2005;57:108–19.
  31. Cooke JP, Losordo DW. Nitric oxide and angiogenesis. *Circulation* 2002;105:2133–5. [\[CrossRef\]](#)
  32. Schwentker A, Vodovotz Y, Weller R, Billiar TR. Nitric oxide and wound repair: role of cytokines?. *Nitric Oxide* 2002;7:1–10. [\[CrossRef\]](#)
  33. Stallmeyer B, Kämpfer H, Kolb N, Pfeilschifter J, Frank S. The function of nitric oxide in wound repair: inhibition of inducible nitric oxide-synthase severely impairs wound reepithelialization. *J Invest Dermatol* 1999;113:1090–8. [\[CrossRef\]](#)
  34. Nakamura H, Herzenberg LA, Bai J, Araya S, Kondo N, Nishinaka Y, et al. Circulating thioredoxin suppresses lipopolysaccharide-induced neutrophil chemotaxis. *Proc Natl Acad Sci U S A* 2001;98:15143–8. [\[CrossRef\]](#)
  35. Furchgott RF. The discovery of endothelium-derived relaxing factor and its importance in the identification of nitric oxide. *JAMA* 1996;276:1186–8. [\[CrossRef\]](#)
  36. Weller R, Schwentker A, Billiar TR, Vodovotz Y. Autologous nitric oxide protects mouse and human keratinocytes from ultraviolet B radiation-induced apoptosis. *Am J Physiol Cell Physiol* 2003;284:C1140–8. [\[CrossRef\]](#)
  37. Krischel V, Bruch-Gerharz D, Suschek C, Kröncke KD, Ruzicka T, Kolb-Bachofen V. Biphasic effect of exogenous nitric oxide on proliferation and differentiation in skin derived keratinocytes but not fibroblasts. *J Invest Dermatol* 1998;111:286–91. [\[CrossRef\]](#)
  38. Stamler JS, Jia L, Eu JP, McMahon TJ, Demchenko IT, Bonaventura J, et al. Blood flow regulation by S-nitrosohemoglobin in the physiological oxygen gradient. *Science* 1997;276:2034–7. [\[CrossRef\]](#)
  39. Weller R, Ormerod AD, Hobson RP, Benjamin NJ. A randomized trial of acidified nitrite cream in the treatment of tinea pedis. *J Am Acad Dermatol* 1998;38:559–63. [\[CrossRef\]](#)
  40. Jamshidzadeh A, Azarpira N. The effects of topical sildenafil on wound healing in rat. *Iranian J Pharmaceutical Scie* 2011;7:43–8.
  41. Salcido RS. Viagra and wound healing: the NO connection. *Adv Skin Wound Care* 2008;21:106–9. [\[CrossRef\]](#)
  42. Sarifakioglu N, Gokrem S, Ates L, Akbuga UB, Aslan G. The influence of sildenafil on random skin flap survival in rats: an experimental study. *Br J Plast Surg* 2004;57:769–72. [\[CrossRef\]](#)
  43. Derici H, Kamer E, Unalp HR, Diniz G, Bozdog AD, Tansug T, et al. Effect of sildenafil on wound healing: an experimental study. *Langenbecks Arch Surg* 2010;395:713–8. [\[CrossRef\]](#)
  44. Farsaei S, Khalili H, Karimzadeh I, Dashti-Khavidaki S. An old drug for a new application: potential benefits of sildenafil in wound healing. *J Pharm Pharmaceut Sci* 2012;15:483–98. [\[CrossRef\]](#)

## DENEYSEL ÇALIŞMA - ÖZET

## Yanık staz zonu üzerine sildenafil ve N-asetilsisteinin etkisi

Dr. Meriç Emre Bostancı,<sup>1</sup> Dr. Ceylan Hepokur,<sup>2</sup> Dr. Erol Kisi<sup>3</sup><sup>1</sup>Sivas Cumhuriyet Üniversitesi Tıp Fakültesi, Cerrahi Onkoloji Bilim Dalı, Sivas<sup>2</sup>Sivas Cumhuriyet Üniversitesi Eczacılık Fakültesi, Biyokimya Anabilim Dalı, Sivas<sup>3</sup>Sivas Cumhuriyet Üniversitesi Tıp Fakültesi, Genel Cerrahi Anabilim Dalı, Sivas

**AMAÇ:** Yanık yarasının iyileşmesinde, yanıkta oluşan yaralanma zonları; hiperemi, staz, koagülasyon zonu büyük önem taşımaktadır. Yanığın patofizyolojisindeki gelişmeye bağlı olarak yanık ciltte oluşan yanık zonları bulunmuş ve tedavi buna göre daha da gelişmiştir. Bu zonlar; koagülasyon, staz ve hiperemi zonedir. Nekroz zonu tedavisi eksizyon ve kaybolan cildin greft olarak onarımıdır. Staz zonu eğer 24–48 saat içinde yanık tedavisi iyi yönetilirse tam olarak iyileşir. Aksi takdirde koagülasyon zonuna dahil olur. Hiperemi zonu zaten kendiliğinden iyileşebilen bir alandır. Staz zonu nun kurtarılması yanık tedavisinde oldukça önem taşımaktadır. Yanık alanda oluşan hipermetabolizma sonucu ortaya çıkan aktif oksijen radikalleri staz zonunun koagülasyon zonuna dönüşümünü hızlandırdığı bilinmektedir. Bu deneysel çalışmanın amacı, yanık staz zonu üzerine sildenafil ve N-asetilsisteinin etkilerini incelemek ve yanıkta yara iyileşmesine katkısı olup olmadığını ortaya koymaktır.

**GEREÇ VE YÖNTEM:** Çalışmada 200±20 gr ağırlığında Wistar Albino cinsi dört aylık 32 adet dişi sıçan kullanıldı. Sıçanlar dört gruba ayrıldı. Bu 24 sıçana anestezi altında Regas ve Ehrlich tarafından tanımlanan deneysel yanık modeli uygulandı. Grup 1; sham, Grup 2; intraperitoneal kontrol, Grup 3; sildenafil çalışma (günlük 10 mg/kg dozunda intraperitoneal 10 gün süreyle), Grup 4; N-asetilsistein çalışma (günlük 100 mg/kg dozunda intraperitoneal 10 gün süreyle) grupları olarak belirlendi. Malondialdehit, glutatyon peroksidaz, süperoksit dismutaz, katalaz düzeyleri için serum ve sitopatolojik çalışma için doku örnekleri alındı. Tüm sıçanlar deneyin 10. gününde sakrifiye edildi. Ödem, hiperemi, epitel dejenerasyonu, nekroz, iltihabi infiltrasyon ve fibrozis ölçümleri yapıldı.

**BULGULAR:** Kontrol grubu ile karşılaştırıldığında tedavi edilen iki grupta doku hasar skoru düşük bulundu. MDA düzeyi; Grup 3 ve Grup 4'te, Grup 2'ye göre düşük, Grup 3'te Grup 4'e göre düşük bulundu. SOD, katalaz ve GPH-Px düzeyleri, Grup 3'te ve Grup 4'te Grup 2'ye göre yüksek, Grup 3'te, Grup 4'e göre yüksek bulundu.

**TARTIŞMA:** Çalışmamızın sonuçları, sıçanlarda oluşturulan deneysel yanık modelinde sildenafil ve N-asetilsisteinin oksidatif stres düzeyini azaltıcı, yara iyileşmesini arttırıcı olumlu etkileri olduğunu desteklemektedir. Bu konu üzerinde ileri deneysel çalışmalara ihtiyaç vardır.

**Anahtar sözcükler:** N-asetilsistein; sildenafil; yanık staz zonu; yara iyileşmesi.

Ulus Travma Acil Cerrahi Derg 2021;27(1):9-16 doi: 10.14744/tjtes.2020.25679