

Over-the-scope clip application for severe gastrointestinal bleeding, leak, or perforation: A single-center experience

Ali Kocataş, M.D., Erkan Somuncu, M.D., Mehmet Abdussamet Bozkurt, M.D.

Department of General Surgery, University of Health Sciences, Kanuni Sultan Suleyman Training and Research Hospital, İstanbul-Turkey

ABSTRACT

BACKGROUND: Over-the-scope clip (OTSC) devices are now widely used by endoscopists for gastrointestinal bleeding, perforation, or leakage. The present study aims to examine the therapeutic success rate of this technique.

METHODS: This was a single-center, retrospective study. In this study, 23 patients with gastrointestinal bleeding, leakage, or perforation were included. The procedure was performed by an experienced endoscopist.

RESULTS: Of the patients with an upper gastrointestinal tract defect, six had a perforation and there was one case of anastomosis leakage. Eight patients had a perforation in the lower gastrointestinal tract, and there were two cases of anastomosis leakage. Bleeding was detected in only six patients and all of them were upper gastrointestinal bleeding. Anastomosis leaks, perforations, and bleeding were treated with OTSC and additional procedures. The success rate of OTSC clipping alone was 56.5%. However, the success rate was 86.9% with additional therapeutic procedures (clamp, stent, sclerotherapy). Analysis according to categories of bleeding, perforation, and anastomosis leak revealed that the success rate of the clip application in bleeding was significantly higher than that of perforation or anastomosis leak ($p=0.002$). The median length of stay in the hospital was five days (min-max: 2–30 days). There were no complications associated with the OTSC procedure.

CONCLUSION: OTSC is a safe and effective method for the management of gastrointestinal bleeding, perforation, or anastomosis leak.

Keywords: Bleeding; gastrointestinal leak; over-the-scope clip; perforation.

INTRODUCTION

Minimally invasive procedures are preferred to surgery in the treatment of gastrointestinal perforation, bleeding, or anastomosis leak. The success rate is variable but increases with experience. Endoscopic coated stents, through-the-scope clips, surgical glue, and loop ligatures are available to treat patients without surgery. The over-the-scope clip (OTSC) (Ovesco Endoscopy AG, Tuebingen, Germany) is a novel endoscopic tool that can reduce the need for surgery and use continues to grow. Studies in the literature have described significant effectiveness in cases of gastrointestinal bleeding, perforation, or anastomosis leak.^[1–4]

This is a report of the experience of a single center with the OTSC clip in cases of gastrointestinal bleeding, perforation, or leak, and an analysis of the results.

MATERIALS AND METHODS

Written, informed consent was received from all of the study patients. The OTSC procedure was performed by experienced endoscopy specialists in all cases. Intravenous midazolam and pethidine were administered to all of the patients before the procedure. The OTSC system was attached to the endoscope, the site of the target lesion was completely enclosed, and the OTSC clip was deployed. The clip is positioned by stretching a wire with a handwheel on the en-

Cite this article as: Kocataş A, Somuncu E, Bozkurt MA. Over-the-scope clip application for severe gastrointestinal bleeding, leak, or perforation: A single-center experience. *Ulus Travma Acil Cerrahi Derg* 2021;27:146-150.

Address for correspondence: Erkan Somuncu, M.D.

Sağlık Bilimleri Üniversitesi, Kanuni Sultan Süleyman Eğitim ve Araştırma Hastanesi, Genel Cerrahi Kliniği, İstanbul, Turkey

Tel: +90 212 - 404 15 00 / 1424 E-mail: dr.somuncu@gmail.com

Ulus Travma Acil Cerrahi Derg 2021;27(1):146-150 DOI: 10.14744/tjtes.2020.15719 Submitted: 30.05.2020 Accepted: 23.11.2020 Online: 11.12.2020

Copyright 2021 Turkish Association of Trauma and Emergency Surgery



doscope channel. Two Nitinol half-rings with shape memory compress the tissue when released from the applicator and close the clip. To facilitate the targeting of the lesion, we used the suction technique, a twin gripper, and a crocodile hand tool.

Cases of gastrointestinal bleeding, perforation, and anastomosis leak were reviewed for this study. An anastomosis leak was defined as tissue disruption in the anastomosis area resulting in fluid collection with or without visible contrast extravasation in the radiological images. Perforation was defined as a full-thickness defect in the gastrointestinal tract. Clinical success was defined according to the results of monitoring the gastrointestinal defect during follow-up using clinical, endoscopic, and/or abdominal imaging.

RESULTS

In this study, 23 patients (median age: 50 years, range: 25–77 years) with gastrointestinal bleeding, anastomosis leakage, or gastrointestinal perforation were included. In the group, 17 of the patients were male and six were female. The characteristics and results of the patients are summarized in Table I and some case images are presented in Figure 1.

Five of the cases with upper gastrointestinal bleeding had a Dieulafoy lesion and one case had a Forrest IIb lesion in the antropyloric region. An OTSC clip was applied in one patient with leakage in the anastomosis line after low anterior resection due to a rectal tumor and in one patient with leakage from the rectal stump. OTSC clips were also used in the

upper gastrointestinal tract in six patients and 10 patients due to endoscopic perforation. The upper gastrointestinal defect area was the proximal esophagus in one patient, the distal esophagus in two patients, the gastric region in three patients, and the duodenal bulb in one patient. The lower gastrointestinal defect area was the ascending colon in one patient, the descending colon in two patients, the rectosigmoid in one patient, and the anorectal region in six patients. The defect diameter ranged between 5 and 30 mm (median diameter: 10 mm).

The length of time until the intervention was performed was between one and 72 hours (median: 1 hour). In 20 of the 23 patients treated with OTSC, the defect or bleeding was completely resolved. In some cases, additional therapeutic procedures (sclerotherapy, clamp, stent) were required. In three patients with upper gastrointestinal bleeding, sclerotherapy was performed during the first procedure in addition to applying the clip. Stenting was also required for one patient with an esophagojejunostomy leak after stomach cancer surgery and in another patient with an endoscopic esophageal perforation. Cardiac arrest occurred during the procedure in the patient with an esophageal perforation due to comorbidities. Percutaneous drainage was applied to an intra-abdominal collection that developed during follow-up in one patient, and additional surgery was required in one case following iatrogenic perforation and unsuccessful clipping in the sigmoid colon.

The success rate of OTSC clipping alone was 56.5%; however, the rate was 86.9% with additional therapeutic procedures (clamp, stent, sclerotherapy). When analyzed as three categories (bleeding, perforation, anastomosis leak), it was observed that the success rate of clip application in bleeding cases was significantly higher than that of perforation or anastomosis leak ($p=0.002$). The median length of stay in the hospital was five days (min-max: 2–30 days). There were no complications associated with the OTSC procedure.

DISCUSSION

Gastrointestinal bleeding, perforation, or anastomosis leak requires urgent and careful intervention. Disruption of hemodynamics due to bleeding and sepsis caused by perforation or anastomosis leakage should be corrected quickly. Endoscopists can now manage these complications due to new therapeutic endoscopy procedures.^[5,6] Gastrointestinal bleeding can be controlled with electrocautery, adrenaline injection, or the use of a clip. In patients with comorbidities, the ability to address the problem endoscopically rather than surgically is an advantage. Clips, surgical glue, loop ligatures, and coated metal stents can be used in the endoscopic treatment of perforations and leaks. OTSC has recently become a very important tool. However, the success rate of all of these endoscopic procedures is highly variable, and additional surgical treatment may sometimes be required.^[7,8]

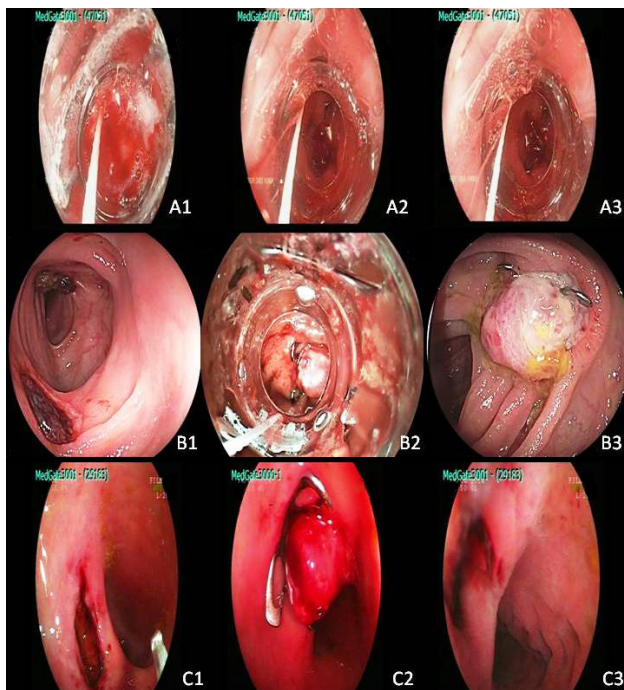


Figure 1. Over-the-scope clip (OTSC) procedure. (A1, A2, A3) Gastrointestinal bleeding; (B1, B2, B3) OTSC placed at the leakage site; (C1, C2, C3) Successful endoscopic perforation closure.

Table 1. Characteristics and outcomes of OTSC patients

Case No.	Age/ Sex	Indication	Location	Time until intervention (hours)	Diameter of defect (mm)	Additional procedure	Hospital stay (days)	Complications	Mortality	Technical success
1	38/F	Dieulafoy (Forrest IA) lesion	Gastroesophageal junction	1.	-	Sclerotherapy	5	None	None	Yes
2	45/M	Dieulafoy (Forrest IA) lesion	Gastroesophageal junction	1.	-	None	7	None	None	Yes
3	52/M	Dieulafoy (Forrest IA) lesion	Gastroesophageal junction	1.	-	Sclerotherapy	3	None	None	Yes
4	65/F	Forrest IIB lesion	Corpus	1.	-	Sclerotherapy	11	None	None	Yes
5	42/M	Dieulafoy (Forrest IA) lesion	Gastroesophageal junction	1.	-	None	4	None	None	Yes
6	67/M	Dieulafoy (Forrest IA) lesion	Gastroesophageal junction	1.	-	None	4	None	None	Yes
7	72/M	Endoscopic perforation	Bulbus	1.	5	None	5	Yes ^a	None	No
8	78/F	Endoscopic perforation	Upper esophagus	24.	10	None	5	None	Yes ^b	No
9	41/M	Endoscopic perforation	Lower esophagus	12.	5	Stent	30	None	None	Yes
10	56/M	Endoscopic perforation	Fundus	1.	10	None	5	None	None	Yes
11	41/F	Endoscopic perforation	Antrum	1.	10	None	2	None	None	Yes
12	49/M	Endoscopic perforation	Antrum	24.	5	None	3	None	None	Yes
13	71/M	Anastomotic leakage	Esophagojejunostomy	24.	10	Clamp, Stent	7	None	None	Yes
14	50/M	Endoscopic perforation	Descending colon	1.	5	None	10	Yes ^c	None	No
15	49/F	Endoscopic perforation	Ascending colon	1.	5	Clamp	2	None	None	Yes
16	31/M	Traumatic perforation	Descending colon	12.	15	None	12	None	None	Yes
17	52/M	Anastomotic leakage	Rectum	36.	30	None	8	None	None	Yes
18	25/M	Traumatic perforation	Anorectum	24.	15	None	5	None	None	Yes
19	44/M	Traumatic perforation	Anorectum	6.	10	Clamp	5	None	None	Yes
20	61/M	Anastomotic leakage	Anorectum	72.	5	Clamp	11	None	None	Yes
21	47/M	Traumatic perforation	Anorectum	72.	30	None	7	None	None	Yes
22	69/M	Endoscopic perforation	Rectum	1.	15	Clamp	5	None	None	Yes
23	77/F	Endoscopic perforation	Rectosigmoid	1.	5	Clamp	8	None	None	Yes

^aAbdominal abscess; ^bCardiac arrest; ^cOpen surgery. OTSC: Over-the-scope clip; F: Female; M: Male.

In 2007, Kirschniak et al.^[9] reported on 11 cases of severe gastric and colonic bleeding and perforation treated with OTSC. In 2011, they described bleeding, perforation, and fistula successfully treated with OTSC in a larger group of 50 patients.^[10] In 2014, Haito-Chavez et al.^[11] published an international multicenter study on the success of using OTSC for gastrointestinal fistula, perforation, and bleeding in 188 patients.

The observations of Manta et al.^[12] regarding 30 single-center patients in 2013 are consistent with our findings: OTSC was an effective and safe treatment option for severe acute gastrointestinal bleeding. Management of emergency bleeding can be very difficult. However, the application of the OTSC clip by an experienced endoscopist can avoid the vast majority of bleeding as surgical morbidity.^[13–15] Wedi et al.^[16] achieved an 85.6% clinical success rate with the OTSC clip in cases of gastrointestinal bleeding. We recorded similar clinical success.

Perforations and anastomosis leaks may lead to severe morbidity and mortality rates and require emergency intervention. Spontaneous closure of these cases is unusual and surgical treatment is often troublesome. Endoscopic management of these conditions and OTSC clip use represents a valuable contribution. Nonetheless, thus far, large patient series have been limited and most are experimental.^[16,17]

In 2006, Schurr et al.^[18,19] demonstrated that the OTSC system was a safe and simple method of closure and offered an alternative to surgery in cases of colonic perforation. In 2013, Weiland et al.^[20] evaluated 22 pre-clinical research articles with 17 case series. The OTSC success rate was 80% to 100% and the durable closure rate was 57% to 100%. Our results were similar.

Matthes et al.^[21] achieved successful closure in all stomach defects ranging from 5 to 20 mm by using 12-mm OTSCs with short teeth and colon defects ranging from 10 to 30 mm with 14-mm OTSCs with short teeth. They proposed the use of additional clips for larger defects. Similarly, we found that defects between 5 mm and 30 mm were closed safely and effectively with the OTSC procedure alone or with additional therapeutic procedures (clip, clamp, stent).

In a 45-case multicenter study published in the USA, Baron et al.^[22] examined anastomosis leakage in 31 patients and the defect was closed permanently in 20 (65%) with the OTSC procedure. Haito-Chavez et al.^[11] demonstrated similar success, achieving 60.2% permanent closure after the median follow-up period of 146 days.

The OTSC clip can successfully be used to stop bleeding in the gastrointestinal tract and for primary non-surgical closure of perforations and leaks. It is easy to use and there have been no reports of significant complications.^[7–11] There is a

potential difficulty with the OTSC system in managing the gripping tool; however, in most cases, especially in emergencies, this can be prevented if OTSC is applied using suction.^[16] Cases of complete jejunal closure secondary to clip displacement have been reported in the literature.^[22]

In our study, the proportion of patients who did not require additional therapeutic procedures after treatment with OTSC and did not develop complications was 56.5%. However, the rate increased to 86.9% with additional therapeutic procedures (clamp, stent, sclerotherapy). Our results suggested that OTSC was more successful in the treatment of gastrointestinal bleeding than it achieved in leaks and perforations. The biggest limitation of this study is the small number of patients. However, this procedure is usually performed by experienced endoscopists at centers with the necessary capabilities, and the number of patients is limited. Therefore, the number of patients treated at a single center in this study is meaningful.

Conclusion

Our study confirms that OTSC is useful in the treatment of severe gastrointestinal bleeding, perforation, or anastomosis leak. It represents a safe and effective option compared with surgery. In our country, the number of upper and lower gastrointestinal diagnostic and therapeutic endoscopies, as well as stomach and colon cancer operations, is increasing. Given the potential complications of comorbidities and the additional burdens of surgery, alternative endoscopic methods are important. Multicenter, national studies that include a large number of patients are needed.

Human subjects: Consent was obtained from all participants in this study.

Peer-review: Internally peer-reviewed.

Authorship Contributions: Concept: A.K., E.S., M.A.B.; Design: A.K., E.S., M.A.B.; Supervision: A.K., E.S., M.A.B.; Resource: A.K., E.S., M.A.B.; Materials: A.K., E.S., M.A.B.; Data: A.K., E.S., M.A.B.; Analysis: A.K., E.S., M.A.B.; Literature search: A.K., E.S., M.A.B.; Writing: E.S.; Critical revision: A.K., E.S., M.A.B.

Conflict of Interest: None declared.

Financial Disclosure: The authors declared that this study has received no financial support.

REFERENCES

1. Bartell N, Bittner K, Kaul V, Kothari TH, Kothari S. Clinical efficacy of the over-the-scope clip device: A systematic review. *World J Gastroenterol* 2020;26:3495–516. [\[CrossRef\]](#)
2. Weiland T, Rohrer S, Schmidt A, Wedi E, Bauerfeind P, Caca K, et al. Efficacy of the OTSC System in the treatment of GI bleeding and wall defects: a PMCF meta-analysis. *Minim Invasive Ther Allied Technol* 2020;29:121–39. [\[CrossRef\]](#)
3. Kobara H, Mori H, Nishiyama N, Fujihara S, Okano K, Suzuki Y, et al.

- Over-the-scope clip system: A review of 1517 cases over 9 years. *J Gastroenterol Hepatol* 2019;34:22–30. [CrossRef]
4. Singh RR, Nussbaum JS, Kumta NA. Endoscopic management of perforations, leaks and fistulas. *Transl Gastroenterol Hepatol* 2018;3:85. [CrossRef]
 5. Chavan R, Nabi Z, Karayampudi A, Jagtap N, Asif S, Yaralagadda R, et al. Outcomes of over-the-scope clip application in various gastrointestinal indications: experience from a tertiary care in India. *Ann Gastroenterol* 2020;33:473–9. [CrossRef]
 6. Lee HL, Cho JY, Cho JH, Park JJ, Kim CG, Kim SH, et al. Efficacy of the Over-the-Scope Clip System for Treatment of Gastrointestinal Fistulas, Leaks, and Perforations: A Korean Multi-Center Study. *Clin Endosc* 2018;51:61–5. [CrossRef]
 7. Repici A, Arezzo A, De Caro G, Morino M, Pagano N, Rando G, et al. Clinical experience with a new endoscopic over-the-scope clip system for use in the GI tract. *Dig Liver Dis* 2009;41:406–10. [CrossRef]
 8. Albert JG, Friedrich-Rust M, Woeste G, Strey C, Bechstein WO, Zeuzem S, et al. Benefit of a clipping device in use in intestinal bleeding and intestinal leakage. *Gastrointest Endosc* 2011;74:389–97. [CrossRef]
 9. Kirschniak A, Kratt T, Stücker D, Braun A, Schurr MO, Königsrainer A. A new endoscopic over-the-scope clip system for treatment of lesions and bleeding in the GI tract: first clinical experiences. *Gastrointest Endosc* 2007;66:162–7. [CrossRef]
 10. Kirschniak A, Subotova N, Zieker D, Königsrainer A, Kratt T. The Over-The-Scope Clip (OTSC) for the treatment of gastrointestinal bleeding, perforations, and fistulas. *Surg Endosc* 2011;25:2901–5. [CrossRef]
 11. Haito-Chavez Y, Law JK, Kratt T, Arezzo A, Verra M, Morino M, et al. International multicenter experience with an over-the-scope clipping device for endoscopic management of GI defects (with video). *Gastrointest Endosc* 2014;80:610–22. [CrossRef]
 12. Manta R, Galloro G, Mangiavillano B, Conigliaro R, Pasquale L, Arezzo A, et al. Over-the-scope clip (OTSC) represents an effective endoscopic treatment for acute GI bleeding after failure of conventional techniques. *Surg Endosc* 2013;27:3162–4. [CrossRef]
 13. Cooper GS, Chak A, Harper DL, Pine M, Rosenthal GE. Care of patients with upper gastrointestinal hemorrhage in academic medical centers: a community-based comparison. *Gastroenterology* 1996;111:385–90. [CrossRef]
 14. Rockall TA, Logan RF, Devlin HB, Northfield TC. Risk assessment after acute upper gastrointestinal haemorrhage. *Gut* 1996;38:316–21. [CrossRef]
 15. Rollhauser C, Fleischer DE. Nonvariceal upper gastrointestinal bleeding. *Endoscopy* 2002;34:111–8. [CrossRef]
 16. Wedi E, Gonzalez S, Menke D, Kruse E, Matthes K, Hochberger J. One hundred and one over-the-scope-clip applications for severe gastrointestinal bleeding, leaks and fistulas. *World J Gastroenterol* 2016;22:1844–53. [CrossRef]
 17. Rogalski P, Daniluk J, Baniukiewicz A, Wroblewski E, Dabrowski A. Endoscopic management of gastrointestinal perforations, leaks and fistulas. *World J Gastroenterol* 2015;21:10542–52. [CrossRef]
 18. Schurr MO, Hartmann C, Ho CN, Fleisch C, Kirschniak A. An over-the-scope clip (OTSC) system for closure of iatrogenic colon perforations: results of an experimental survival study in pigs. *Endoscopy* 2008;40:584–8. [CrossRef]
 19. Schurr MO, Hartmann C, Kirschniak A, Ho CN, Fleisch C, Buess G. Experimental study on a new method for colonoscopic closure of large-bowel perforations with the OTSC clip. [Article in German]. *Biomed Tech (Berl)* 2008;53:45–51. [CrossRef]
 20. Weiland T, Fehlker M, Gottwald T, Schurr MO. Performance of the OTSC System in the endoscopic closure of iatrogenic gastrointestinal perforations: a systematic review. *Surg Endosc* 2013;27:2258–74. [CrossRef]
 21. Matthes K, Jung Y, Kato M, Gromski MA, Chuttani R. Efficacy of full-thickness GI perforation closure with a novel over-the-scope clip application device: an animal study. *Gastrointest Endosc* 2011;74:1369–75. [CrossRef]
 22. Baron TH, Song LM, Ross A, Tokar JL, Irani S, Kozarek RA. Use of an over-the-scope clipping device: multicenter retrospective results of the first U.S. experience (with videos). *Gastrointest Endosc* 2012;76:202–8.

OLGU SERİSİ - ÖZET

Şiddetli gastrointestinal kanama, kaçak ve perforasyonlar için over-the-scope klip uygulamaları: Tek merkez deneyimi

Dr. Ali Kocataş, Dr. Erkan Somuncu, Dr. Mehmet Abdussamet Bozkurt

Sağlık Bilimleri Üniversitesi, Kanuni Sultan Süleyman Eğitim ve Araştırma Hastanesi, Genel Cerrahi Kliniği, İstanbul

AMAÇ: Kapsam dışı klips (OTSC) cihazları artık endoskopistler tarafından gastrointestinal kanama, perforasyon veya sızıntı için yaygın olarak kullanılmaktadır. Bu çalışmanın amacı, bu tekniğin terapötik başarı oranını incelemektir.

GEREÇ VE YÖNTEM: Bu çalışma tek merkezli ve geriye dönük olarak yapıldı. Çalışmaya gastrointestinal kanaması, sızıntısı veya perforasyonu olan toplam 23 hasta alındı. Prosedür deneyimli endoskopist tarafından gerçekleştirildi.

BULGULAR: Üst gastrointestinal sistem defekti olan hastaların altısında perforasyon, bir olguda anastomoz kaçağı vardı. Sekiz hastada alt gastrointestinal kanalda perforasyon vardı ve iki olgu anastomoz kaçağı vardı. Sadece altı hastada kanama tespit edildi ve tümü üst gastrointestinal kanama idi. Anastomoz sızıntıları, perforasyonlar ve kanama OTSC ve ek prosedürlerle tedavi edildi. Tek başına OTSC kırpmının başarı oranı %56.5 iken, ek terapötik prosedürlerle (klemp, stent, skleroterapi) başarı oranı %86.9'du. Kanama, perforasyon ve anastomoz kaçağı kategorilerine göre yapılan analizler, klip uygulamasının kanamadaki başarı oranının perforasyon veya anastomoz kaçağına göre anlamlı derecede yüksek olduğunu ortaya koydu ($p=0.002$). Hastanede ortalama kalış süresi beş gündü (min-maks: 2–30 gün). OTSC prosedürü ile ilişkili herhangi bir komplikasyon yoktu.

TARTIŞMA: OTSC, gastrointestinal kanama, perforasyon veya anastomoz sızıntısının yönetimi için güvenli ve etkili bir yöntemdir.

Anahtar sözcükler: Gastrointestinal kaçak; kanama; kapsam dışı klip; perforasyon.

Ulus Travma Acil Cerrahi Derg 2021;27(1):146-150 doi: 10.14744/tjtes.2020.15719