

Spinal cord contusion and paraplegia resulting from indirect gunshot injury

 Chen-Wei Wu, M.D.,¹  Chien-Chin Hsu, M.D.,²  Kuo-Tai Chen, M.D.³

¹Department of Emergency Medicine, Taipei Medical University School of Medicine, College of Medicine, Taipei-Taiwan

²Department of Emergency, Chi-Mei Medical Center, Tainan-Taiwan

³Department of Biotechnology, Southern Tainan University of Technology, Tainan-Taiwan

ABSTRACT

Emergency physicians may overlook spinal cord injury in patients when the direct impact of a gunshot on the spine is lacking. A 30-year-old man who was shot on his right chest wall was brought to the emergency department. He arrived in a state of shock and underwent emergent thoracotomy for massive hemothorax. After surgery, he was found to be paraplegic. Magnetic resonance imaging of the spine showed T4 spinal cord contusion. The penetrating bullet dissipates energy to the surrounding tissue and contuses the spinal cord. Another assumption of the spinal cord injury is the impairment of blood supply to the cord. No effective treatment exists for gunshot-related indirect injury to the spinal cord. These reported cases reminded emergency physicians that after stabilization of the patient with a gunshot wound, a complete neurologic examination should be performed to discover occult spinal cord injury.

Keywords: Gunshot; indirect injury; paraplegia; spinal cord injury.

INTRODUCTION

The incidence of gunshot injury in the civilian population has increased significantly in recent years; therefore, spinal cord injury caused by a gunshot has become a notable medical issue in the civilian population.^[1-3] Considering spinal cord injury, when the trajectory of the penetrating bullet passes through the spine or when imaging studies show an obvious trauma to the spine and fragments in the spinal canal is easy. However, the spinal cord can be damaged through shock wave or temporary cavitation due to the bullet.^[2,4] Trauma surgeons or emergency physicians may overlook spinal cord injury in patients when the direct impact of a gunshot on the spine is lacking, especially in patients with altered mental state or those under sedation.^[2,3,5]

CASE REPORT

A 30-year-old man who was shot intentionally on his right

chest wall was brought to the emergency department. The pistol bullet penetrated his chest wall and exited through his upper back. He arrived at our emergency department in a state of shock and drowsy consciousness (Glasgow coma scale: E4V4M5). Triage vital signs were as follows: Arterial pressure, 126/50 mmHg; heart rate, 105/min; respiratory rate 16/min; and temperature, 35.8°C. He underwent right thoracotomy for chest-penetrating injury, followed by sedation and tracheal intubation with mechanical ventilation because of irregular respiration and inability of the patient to cooperate with the medical management. Aggressive fluid supplements, including 1000 mL of 0.9% saline, six units of packed red blood cells, and six units of fresh frozen plasma, were administered to treat hypovolemic shock. A computed tomography scan of his chest revealed the right massive hemothorax and comminuted fractures of the right fourth rib and transverse process of the right fourth thoracic spine (Fig. 1). Because of persistent hypovolemic shock, we shifted him to the operation room and performed emergent thoracotomy.

Cite this article as: Wu CW, Hsu CC, Chen KT. Spinal cord contusion and paraplegia resulting from indirect gunshot injury. *Ulus Travma Acil Cerrahi Derg* 2021;27:702-705.

Address for correspondence: Kuo-Tai Chen, M.D.

No.159, Yuwen 1st St., East Dist., Tainan City 701 70163 Tainan, Taiwan

Tel: +88 6988187701 E-mail: 890502@mail.chimei.org.tw

Ulus Travma Acil Cerrahi Derg 2021;27(6):702-705 DOI: 10.14744/tjtes.2020.12686 Submitted: 19.06.2019 Accepted: 04.05.2020

Copyright 2021 Turkish Association of Trauma and Emergency Surgery



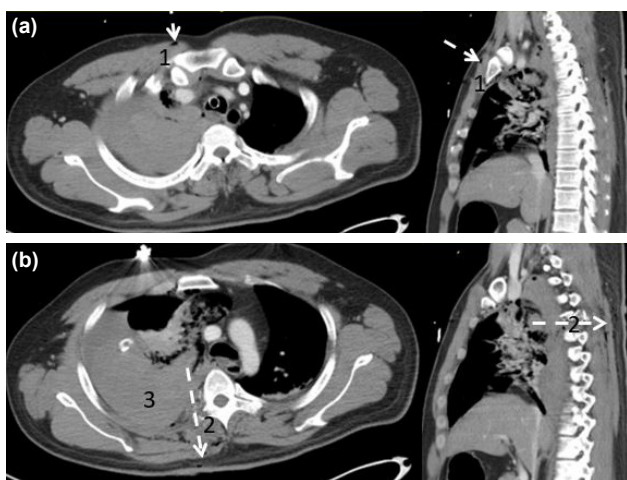


Figure 1. Computed tomography scan of the chest. The trajectory is represented by the white arrow. (a) Subcutaneous emphysema near the right first intercostal space and sternum. (b) Fracture of the right fourth transverse process and the right hemothorax.

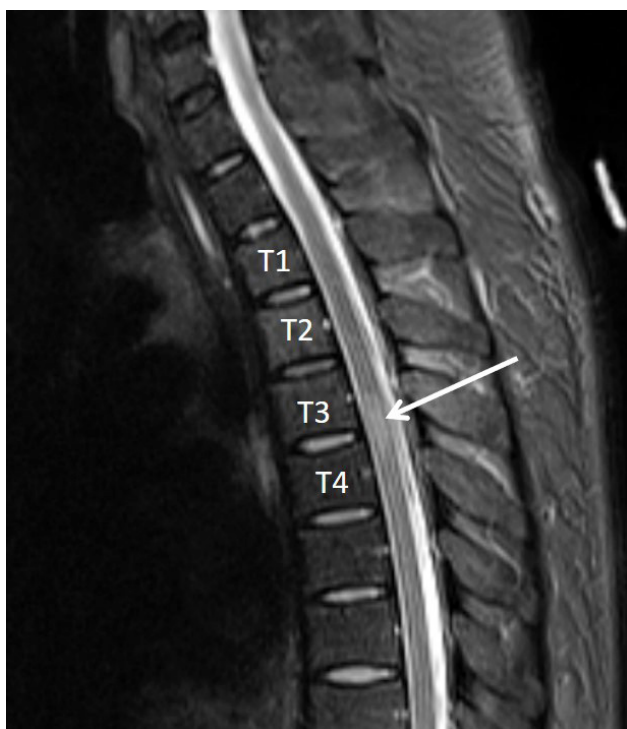

Figure 2. Magnetic resonance imaging of the thoracic spine. White arrow indicates T4 spinal cord contusion.

The patient underwent right upper lobectomy and evacuation of the hemothorax. On the next day after surgery, he was found to be paraplegic. Neurologic examination showed 0/5 muscle power of his lower extremities and loss of sensation below T4. He underwent emergent magnetic resonance imaging of the spine, which showed T4 spinal cord contusion (Fig. 2). We consulted a neurosurgeon who suggested non-operative treatment. After 16 days of mechanical ventilation, he was extubated successfully. However, he remained paraplegic and experienced complete sensory loss on follow-up after 6 months.

Table 1. Six reported cases

Author reference	Year/Nation	Age/Sex	Bullet	Trajectory	Computed tomography	Magnetic resonance imaging	Associated injuries	Treatment	Outcome
Mirovsky ^[6]	2005/Israel	34/Male	High-velocity	Right chest to right back	No spine injury	Negative	Lung	Non-operative	Paraplegia
Goonewardene ^[7]	2007/UK	31/Male	High-velocity	Right neck to left neck	C5 spinous process fracture	C2-7 cord contusion	nil	Non-operative	Tetraplegia
Klack ^[8]	2011/France	31/Female	Low-velocity	Right chest to right back	T9 transverse process fracture	T8-10 cord contusion	Lung, liver	Non-operative	Paraplegia
Patil ^[9]	2015/India	38/Male	Low-velocity	Left back, stay in right chest wall	No spine injury	Negative	Lung, spleen	Non-operative	Paraplegia
Khan ^[10]	2018/U.S.A	49/Male	Unknown	Left neck to right scapula	T1 transverse process fracture	T1 -2 cord contusion	Lung, trachea	Non-operative	Complete recovery
Wu presented case	2019/Taiwan	30/Male	Low-velocity	Right chest to right back	T4 transverse process fracture	T4 cord contusion	Lung	Non-operative	Paraplegia

DISCUSSION

A literature search of databases, including PubMed and Google Scholar, was performed from 1960 to 2017. Criteria for inclusion of studies in the review were as follows: The patient should have presented a new onset of neurologic deficits after a gunshot injury and the inflicted bullet should not have caused direct injury or left fragments in the spinal cord, vertebral body, pedicle, lamina, or canal. Five articles were identified during the database search.^[6–10] Goonewardene et al.^[6] reported three cases, and we included only one 34-year-old male patient because the other two patients did not meet the inclusion criteria.

The reviewed cases and our reported patient are listed in Table 1. Five male and one female patient were reported from six different counties. The age of patients ranged from 30 to 49 years (mean 35.5 years). Inflicted missiles included three low velocity, two high velocity, and one unknown-style bullets. The patients were shot on the neck, chest, and back, respectively. A computed tomography scan of the torso revealed three cases of a fractured spinal transverse process, one case of a fractured spinous process, and two cases of the normal spine. Every patient underwent magnetic resonance imaging examination, which showed four cord contusions and two negative findings. All patients underwent non-operative treatment, and only one patient recovered from his neurologic deficit after discharge.

The human spinal cord is more vulnerable to gunshot injury than we believed. The penetrating bullet dissipates energy to the surrounding tissue. The energy does not hurt the dense bony structure. However, it contuses the spinal cord. Another assumption of the spinal cord injury is the impairment of blood supply to the cord. The affected vessels may be disrupted or thrombosed, which combine with the hemorrhagic shock state caused by gunshot and result in spinal cord injury.^[6,7,9] No effective treatment exists for gunshot-related indirect injury to the spinal cord. Mechanical decompression or stabilization is not indicated because no bony damage or cord compression by fragments or hematoma is observed.^[11,10] Insufficient evidence supports the use of corticosteroids in patients with spinal cord injury. Proper resuscitation to maintain adequate perfusion to the spinal cord is the only promising management in these cases. These reported cases reminded the trauma surgeons and

emergency physicians that after stabilization of the patient with a gunshot wound, complete neurologic examination should be performed to discover spinal cord injury, even in patients whose imaging studies do not reveal any signs of spinal trauma.

Informed Consent: Written informed consent was obtained from the patient for the publication of the case report and the accompanying images.

Peer-review: Internally peer-reviewed.

Authorship Contributions: Concept: K.T.C.; Design: C.W.W.; Supervision: C.C.H.; Resource: C.W.W., C.C.H.; Materials: K.T.C.; Data: C.W.W.; Analysis: C.C.H.; Literature search: C.W.W., K.T.C.; Writing: C.W.W.; Critical revision: K.T.C.

Conflict of Interest: None declared.

Financial Disclosure: The authors declared that this study has received no financial support.

REFERENCES

1. Jaiswal M, Mittal RS. Concept of gunshot wound spine. *Asian Spine J* 2013; 7:359–64. [[CrossRef](#)]
2. Chittiboina P, Banerjee AD, Zhang S, Caldito G, Nanda A, Willis BK. How bullet trajectory affects outcomes of civilian gunshot injury to the spine. *J Clin Neurosci* 2011; 18:1630–3. [[CrossRef](#)]
3. Klein Y, Cohn SM, Soffer D, Lynn M, Shaw CM, Hasharoni A. Spine injuries are common among asymptomatic patients after gunshot wounds. *J Trauma* 2005; 58:833–6. [[CrossRef](#)]
4. Stefanopoulos PK, Hadjigeorgiou GF, Filippakis K, Gyftokostas D. Gunshot wounds: A review of ballistics related to penetrating trauma. *J Acute Dis* 2014; 3:178–85. [[CrossRef](#)]
5. Mirovsky Y, Shalmon E, Blankstein A, Halperin N. Complete paraplegia following gunshot injury without direct trauma to the cord. *Spine* 2005; 30:2436–8. [[CrossRef](#)]
6. Goonewardene SS, Mangat KS, Sargeant ID, Porter K, Greaves I. Tetraplegia following cervical spine cord contusion from indirect gunshot injury effects. *J R Army Med Corps* 2007; 153:52–3. [[CrossRef](#)]
7. Klack F, Tassin C, Cotton F, Luauete J, Gauthier J, David JS. Gunshot injury without direct injury to the cord may lead to complete paraplegia. *Eur J Trauma Emerg Surg* 2011; 37:49–51. [[CrossRef](#)]
8. Patil R, Jaiswal G, Gupta TK. Gunshot wound causing complete spinal cord injury without mechanical violation of spinal axis: Case report with review of literature. *J Craniovertebr Junction Spine* 2015; 6:149–57.
9. Khan K, Dieudonne B, Saeed S, Alothman S, Saeed Y, Gray S. Paraplegia following spinal cord contusion from an indirect gunshot injury. *Korean J Neurotrauma* 2018; 14:32–34. [[CrossRef](#)]
10. Gawor G, Biese K, Platts-Mills TF. Delay in spinal cord injury diagnosis due to sedation: A case report. *J Emerg Med* 2012; 43:e413–8. [[CrossRef](#)]

OLGU SUNUMU - ÖZ

Dolaylı ateşli silah yaralanmasına bağlı omurilik kontüzyonu ve parapleji

Dr. Chen-Wei Wu,¹ Dr. Chien-Chin Hsu,² Dr. Kuo-Tai Chen³

¹Taipei Tıp Üniversitesi Tıp Fakültesi, Acil Tıp Bölümü, Taipei-Tayvan

²Chi-Mei Tıp Merkezi, Acil Durum Bölümü, Tainan-Tayvan

³Güney Tainan Teknoloji Üniversitesi, Biyoteknoloji Bölümü, Tainan-Tayvan

Acil hekimleri, ateşli silahın omurgaya doğrudan etkisi olmadığı durumlarda hastalarda omurilik yaralanmasını gözden kaçırabilirler. Sağ göğüs duvarından vurulmuş 30 yaşındaki erkek hasta acil servise getirildi. Şok durumunda gelen hastaya masif hemotoraks nedeniyle acil torakotomi yapıldı. Ameliyattan sonra hastanın paraplejik olduğu tespit edildi. Spinal manyetik rezonans görüntülemesinde T4 seviyesinde kontüzyon görüldü. Delici merminin enerjisi çevre dokulara yayılır ve omurilikte kontüzyona neden olur. Omurilik yaralanmasına dair bir başka varsayım, spinal korda olan kan akışının bozulmasıdır. Ateşli silahla ilişkili dolaylı omurilik yaralanması için etkili bir tedavi mevcut değildir. Bildirilen bu olgular, acil hekimlerine ateşli silah yarası olan hastanın stabilizasyonundan sonra, gizli omurilik yaralanmasını saptamak için tam bir nörolojik muayene yapılması gerektiğini hatırlatmaktadır.

Anahtar sözcükler: Ateşli silah; dolaylı yaralanma; omurilik yaralanması; parapleji.

Ulus Travma Acil Cerrahi Derg 2021;27(6):702-705 doi: 10.14744/tjtes.2020.12686