



The hidden devil: unexpected retained knife in the chest wall

Gizli şeytan: göğüs duvarı içinde beklenmedik biçimde kalmış bıçak

Chi-chen CHANG,¹ Hung-jung LIN,¹ Ning-ping FOO,² Kuo-tai CHEN¹

We report a 52-year-old woman presenting with stab wounds on her back and upper extremities. A knife retained in her chest wall was not discovered in the emergency department. This case reminds us that an obvious foreign body can be missed even after obtaining a detailed history, complete physical examination and plain film. Particularly, a retained foreign body increases the risk of infection and may cause further internal organ injury. We suggest that patients undergo computed tomography (CT) scanning whenever a penetrating wound cannot be explored adequately or the trauma surgeons are unable to perform detailed examinations on the injured patients. The CT images could delineate the course and severity of the penetrating injury, and decrease the risk of a retained foreign body.

Key Words: Foreign body; imaging; penetrating chest trauma; stab wound.

Bu yazıda, sırtında ve üst ekstremitelerinde bıçak yaralarıyla gelen 52 yaşında bir kadın olgu sunuldu. Göğüs duvarında kalmış bıçak acil servis bölümünde fark edilmemişti. Olgu bize, ayrıntılı hasta öyküsü, tam bir fiziksel inceleme ve düz film çekilmesine rağmen belirgin bir yabancı cismin gözden kaçabildiğini hatırlatmaktadır. Çıkarılmamış bir yabancı cisim enfeksiyon riskini arttırabileceği gibi ilerde iç organ hasarına neden olabilir. Penetran yara yeterince incelenemediğinde veya travma cerrahı yaralı hastalarda ayrıntılı inceleme yapamıyorsa hastaların bilgisayarlı tomografi taramasından geçmesini öneririz. Bilgisayarlı tomografi görüntüleri penetran yaralanmayı, şiddetini ve yabancı bir cisim riskini aydınlatılabilir.

Anahtar Sözcükler: Yabancı cisim; görüntüleme; penetran göğüs travması; bıçak yarası.

We report a case of a woman presenting with stab wounds on her back and upper extremities. Neither the patient herself nor the trauma surgeons discovered the retained knife in her wound until surgery. This report highlights the unpredictability of retained foreign body in patients with penetrating injury.

CASE REPORT

An obese 52-year-old woman was taken to the emergency department by ambulance. She had suffered an assault with a knife to her back, elbow and hands. On admission, the patient was coherent but in hypovolemic state with a blood pressure of 61/50 mmHg, heart rate of 83 per minute and respiratory rate of 24 per minute. We covered the wounds and the bleeding was stopped shortly thereafter. After infusion of isotonic saline and blood, her blood pressure normalized. Chest roentgenogram revealed neither hemo-

pneumothorax nor signs of pulmonary parenchymal injury (Fig. 1). Eight hours later, the patient was transferred to the operating room for wound debridement and suture. An 18-cm knife that had entered from the back was found retained in the chest wall (Fig. 2). The blade had penetrated the right diaphragm and lung. The knife was surgically withdrawn and the postoperative recovery was uneventful.

DISCUSSION

A foreign body may be observed anywhere in the chest as a result of a traumatic event. Although there is usually evidence of penetrating thoracic wound, a retained foreign body may occur unexpectedly. Previous studies suggest that the trauma surgeons should pay attention to the clinical history and trauma mechanisms, as well as to the radiologic findings.^[1,2] However, the retained foreign bodies may be small or radiolucent

Departments of ¹Emergency, ²Emergency Medicine, Chi-mei Medical Center, Liouying, Taiwan.

Chi-mei Tıp Merkezi, ¹Acil Servis, ²Acil Tıp Kliniği, Liouying, Tayvan.

Correspondence (İletişim): Kuo-tai Chen, M.D. 901 Chung-Hwa Road, Yung Kang, Tainan 710, Taiwan.
Tel: +0886-6-2812811 (ext. 57196) e-mail (e-posta): 890502@mail.chimei.org.tw

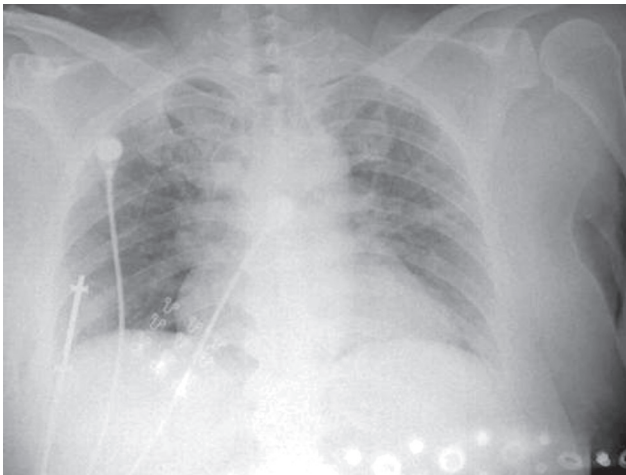


Fig. 1. Chest roentgenogram of the patient. The straight radiopaque line in her right lower chest wall was interpreted as a wire of various monitors used in the emergency department.

in character and thus difficult to discover on the plain film. In addition, the foreign bodies may migrate away from the wounds due to the exerted force from the trauma or may be pushed by the contracture of the muscles surrounding the object; further, the foreign bodies may be overlooked or misinterpreted as objects outside the patient's body.^[2,3]

In our case, the wound on the patient's back was small and the knife had penetrated deep along the chest wall, which caused it to be missed upon exploration of the wound. In addition, the patient arrived in a state of shock; therefore, the wound was covered to stop the bleeding as soon as possible instead of ensuring that a cautious examination was performed. Further, the patient had thick subcutaneous soft tissue (body mass index: 30.4) and neither the patient herself nor the trauma surgeons discovered the retained foreign body during the physical examination. The position of the knife made it appear as a metal line on the plain film. All these factors contributed to missing the retained foreign body in this patient.

A retained foreign body carries several risks to the patient. The implanted foreign bodies are highly susceptible to pyogenic infections, and the infections are resistant to antibiotic therapy before the foreign bodies are removed.^[3] Aside from possible infections, the



Fig. 2. The retained foreign body: an 18-cm knife.

foreign bodies may migrate and cause further damage to internal organs.^[4] Thus, it is crucial to discover any retained foreign bodies in penetrating chest wounds. In addition to a detailed history of the trauma mechanisms and careful physical examination, imaging studies are useful tools to identify a retained foreign body. Therefore, we suggest that patients undergo computed tomography (CT) scanning whenever a penetrating wound cannot be explored adequately or the trauma surgeons are unable to perform a detailed examination of an injured patient. The CT images provide information about the course of the penetrating object, the involved organs and the severity of organ injuries.^[1,2] Most importantly, the CT image helps the trauma surgeons discover the retained foreign bodies and arrange for their proper removal.^[2,3,5]

REFERENCES

1. Demetriades D, Velmahos GC. Penetrating injuries of the chest: indications for operation. *Scand J Surg* 2002;91:41-5.
2. de Vries CS, Africa M, Gebremariam FA, van Rensburg JJ, Otto SF, Potgieter HF. Et al. The imaging of stab injuries. *Acta Radiol* 2010;51:92-106.
3. Kim TJ, Goo JM, Moon MH, Im JG, Kim MY. Foreign bodies in the chest: how come they are seen in adults? *Korean J Radiol* 2001;2:87-96.
4. Sokouti M, Montazeri V. Delayed massive hemoptysis 20 years after lung stabbing: an unusual presentation. *Eur J Cardiothorac Surg* 2007;32:679-81.
5. Kavanagh PV, Mason AC, Müller NL. Thoracic foreign bodies in adults. *Clin Radiol* 1999;54:353-60.