

Rapid spontaneous resolution of epidural hematoma: a case report

Kendiliğinden, hızlı şekilde emilen epidural hematoma: Olgu sunumu

Fatih Ersay DENİZ,¹ Cezmi Çağrı TÜRK,² Özgür İSMAİLOĞLU,²
Gökhan BOZKURT,² Osman Ekin ÖZCAN²

Incidence of acute epidural hematoma is estimated as 1.5% of patients treated for head trauma. The condition can be fatal, and urgent surgical evacuation is recommended. Spontaneous resolution may occur in some cases. Herein, rapid spontaneous resolution of an epidural hematoma is reported and possible mechanisms are discussed.

Key Words: Epidural hematoma; head trauma; resolution.

Kafa travması nedeniyle tedavi edilen hastaların %1,5'inde epidural hematoma görülür. Bu durum hayatı tehdit edebilir ve acil cerrahi girişim gerektirir. Bazı olgularda epidural hematomun kendiliğinden emilebildiği görülür. Bu yazıda, kendiliğinden, hızlı bir şekilde emilen epidural hematoma bildirildi ve olası mekanizmalar tartışıldı.

Anahtar Sözcükler: Epidural hematoma; kafa travması; rezolüsyon.

An epidural hematoma (EDH) is thought unlikely to disappear spontaneously, and because of rapid deterioration of the patient, immediate surgical evacuation is recommended. Incidence of acute EDH is estimated as 1.5% of patients treated for head injuries. Various authors have reported resolution of EDHs managed conservatively, but rapid resolution of EDHs is rarely seen and reported by few.

We present herein a patient with an EDH showing rapid spontaneous resolution, without major neurological deficit.

CASE REPORT

On June 21, 2002, a 29-year-old woman was admitted to our clinic after a traffic accident in a car she was driving. Her vital signs were stable at presentation but she was unconscious, agitated and uncooperative. On neurological examination, the Glasgow Coma Scale score was 10, and direct and indirect papillary light reactions were intact. On her plain X-ray, there were multiple fractures of the right clavicle and on the left side of the corpus of the mandible.

Cranial computed tomography (CT) scanning on admission approximately 30 minutes after the accident showed an EDH of 0.5 cm at its maximum thickness

on the left temporal region, air in the parasellar region and air-fluid levels in the left maxillary sinus and ethmoidal sinus (Fig. 1a). There was no midline shift. Two hours later on her follow-up CT scan, the EDH had increased in size to 1 cm at its maximum thickness but was decreased on repeated CT after eight hours to 0.5 cm (Figs. 1b, c). Thirty-nine hours later, another CT scan was performed and the EDH was no longer detectable (Fig. 1d).

In this case, the patient was admitted to the neurosurgical intensive care unit (ICU) and was followed conservatively. As her clinical status settled, she was operated for fracture of the mandible by Ear, Nose and Throat (ENT) surgeons. She remained in the ICU for six days and was then moved to the neurosurgery ward, where she was followed for another week. She was discharged with a mild posttraumatic confusion.

DISCUSSION

The cited mechanism of the resolution of an EDH differs; formation of a fibrovascular neomembrane, granulation tissue acting as an absorbing structure through sinusoid vessels or transfer of the clot into diploic bone or extracranial space through the fractures are among the major hypotheses for spontaneous resolution.^[1-3]

Presented at the 19th Congress of Turkish Neurological Society
(May 27-31, 2005, Antalya, Turkey).

Türk Nöroşirürji Derneği 19. Bilimsel Kongresi'nde sunulmuştur
(27-31 Mayıs 2005, Antalya).

¹Department of Neurosurgery, Gaziosmanpaşa University Faculty of Medicine, Tokat; ²Department of Neurosurgery, Hacettepe University, Faculty of Medicine, Ankara, Turkey.

¹Gaziosmanpaşa Üniversitesi Tıp Fakültesi, Nöroşirürji Anabilim Dalı, Tokat; ²Hacettepe Üniversitesi Tıp Fakültesi, Nöroşirürji Anabilim Dalı, Ankara.

Correspondence (İletişim): Fatih Ersay Deniz, M.D. Gaziosmanpaşa Üniversitesi Hastanesi, Nöroşirürji Anabilim Dalı, 60100 Tokat, Turkey.
Tel: +90 - 356 - 212 95 00 e-mail (e-posta): ersaymd@yahoo.com

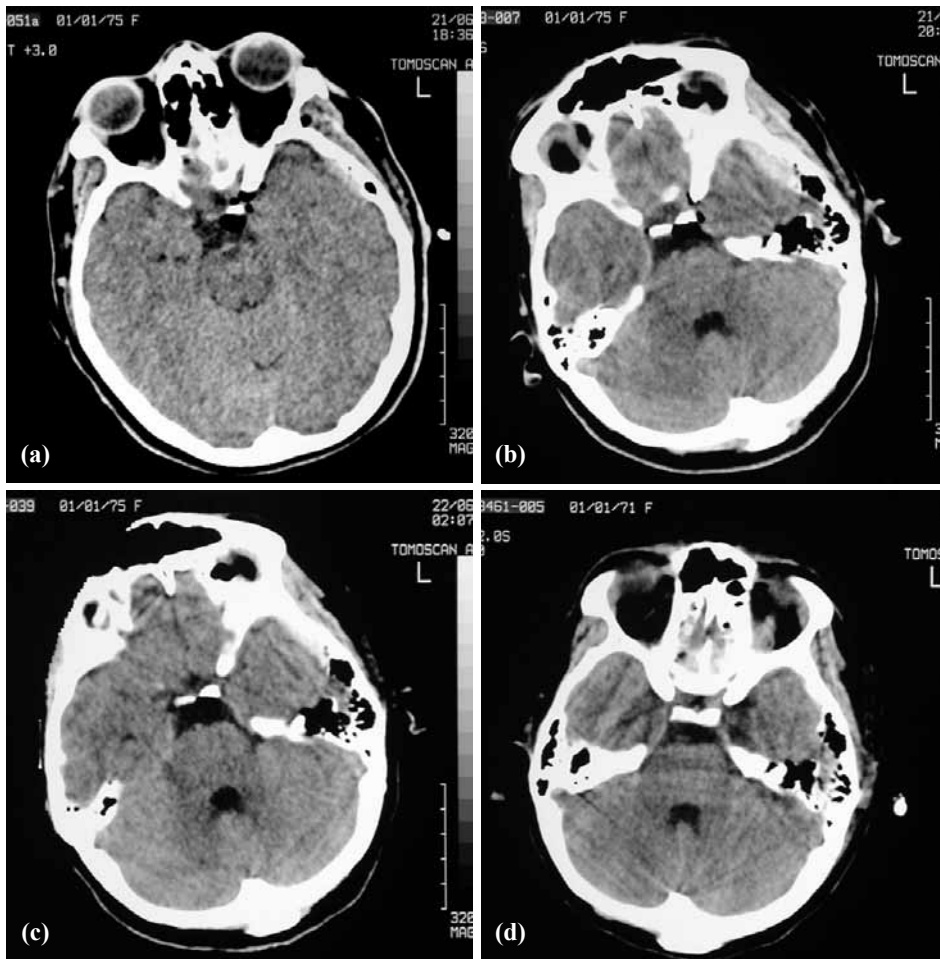


Fig. 1. (a) CT showing 0.5 cm epidural hematoma in the left temporal region. (b) CT showing 1 cm epidural hematoma. (c) CT showing 0.5 cm epidural hematoma. (d) CT showing complete resolution of the epidural hematoma in the left temporal region.

Formation of fibrovascular neomembrane or granulation tissue is particularly thought to be the mechanism in chronic EDH resolution because a time period is needed for its formation. The presence of skull fracture can allow communication between the epidural region and extracranial tissues. Transfer of collection to the subgaleal space can relieve compression caused by the hematoma. Aoki^[1] supports this finding, in a case report in which there was an increase in the volume of an epicranial hematoma, while a decrease in the size of the EDH was detected. Malek et al.^[4] reported that crush injury to subgaleal tissue and the temporalis muscle can be followed by transient elevation in interstitial fluid pressure, and in the presence of skull fracture, the elevated interstitial pressure can decompress into the epidural space, which then resolved by extruding back into the epicranial space with the relaxation of the subgaleal pressure. In addition, it is postulated that raised intracranial pressure helps in the reabsorption of the EDH through the epicranial tissue. Servadei et al.^[3] proposed that the onset of generalized brain swelling plays a fundamental role in the resolution mechanism.

Although the belief that presence of skull fracture is indicative of a good outcome, EDHs are associated

with skull fractures in 65 to 95% of cases, but nevertheless most EDHs have to be operated and are not spontaneously reabsorbed. In the process of decision-making for the management of EDHs, there are some factors that should be kept in mind, among them: age, location of the hematoma, features of each hematoma (thickness, midline shift) and associated lesions, clinical presentation of the patient, CT scan findings, and correlation of the findings with clinical features.

The majority of the cases having rapid spontaneous resolution of EDH are children. Servadei et al.^[3] reported a patient aged 65 years whose EDH was spontaneously reabsorbed although the patient died due to diffuse brain injury. In the present case, the patient was 29 years old and was discharged with mild post-traumatic confusion. Although it is thought that temporally situated EDHs are unlikely to reabsorb spontaneously, our case is an example of rapid resolution of an EDH in this region.

Tuncer et al.^[5] pointed out that initial presentation of the patient and CT scan findings in first 24 hours determine the clinical outcome and conservative management of EDHs. CT scanning is the method for follow-up of patients managed nonoperatively, and CT scan findings should be correlated with clinical

REFERENCES

findings. In the discussion about conservative versus surgical management of patients with EDH, feasibility is also important. There is a low rate of morbidity and mortality in patients subjected to surgery, thus decreasing costs because the patient does not face a prolonged hospitalization in the ICU and wards and undergoes fewer imaging studies.

There are no definitive established criteria to treat conservatively. However, it is a fact that not all EDHs have to be treated surgically and that some acute EDHs spontaneously reabsorb while a much lower number show rapid resolution.

The most appropriate management modality should be considered according to the relevant aspects in each patient.

1. Aoki N. Rapid resolution of acute epidural hematoma. Report of two cases. *J Neurosurg* 1988;68:149-51.
2. Pozzati E, Tognetti F. Spontaneous healing of acute extradural hematomas: study of twenty-two cases. *Neurosurgery* 1986;18:696-700.
3. Servadei F, Staffa G, Pozzati E, Piazza G. Rapid spontaneous disappearance of an acute extradural hematoma: case report. *J Trauma* 1989;29:880-2.
4. Malek AM, Barnett FH, Schwartz MS, Scott RM. Spontaneous rapid resolution of an epidural hematoma associated with an overlying skull fracture and subgaleal hematoma in a 17-month-old child. *Pediatr Neurosurg* 1997;26:160-5.
5. Tuncer R, Açıkbaş C, Uçar T, Kazan S, Karasoy M, Saveren M. Conservative management of extradural haematomas: effects of skull fractures on resorption rate. *Acta Neurochir (Wien)* 1997;139:203-7.