

Thymoquinone attenuates trauma induced spinal cord damage in an animal model

Nilgün Üstün, M.D.,¹ Mustafa Aras, M.D.,² Tumay Ozgur, M.D.,³ Hamdullah Suphi Bayraktar, M.D.,⁴ Fatih Sefil, M.D.,⁵ Raif Ozden, M.D.,⁶ Abdullah Erman Yagiz, M.D.¹

¹Department of Physical Medicine and Rehabilitation, Mustafa Kemal University Faculty of Medicine, Hatay;

²Department of Neurosurgery, Mustafa Kemal University Faculty of Medicine, Hatay;

³Department of Pathology, Mustafa Kemal University Faculty of Medicine, Hatay;

⁴Department of Clinical Sciences, Mustafa Kemal University Faculty of Veterinary, Hatay;

⁵Department of Physiology, Mustafa Kemal University Faculty of Medicine, Hatay;

⁶Department of Orthopaedics and Traumatology, Mustafa Kemal University Faculty of Medicine, Hatay

ABSTRACT

BACKGROUND: Spinal cord injury (SCI) is one of the most devastating conditions leading to neurological impairment and disabilities. The aim of the study was to investigate the potential neuroprotective effect of thymoquinone (TQ) histopathologically in an experimental model of traumatic spinal cord injury (SCI).

METHODS: Twenty-four male Wistar albino rats were randomly divided into 4 groups: control group; SCI group; SCI-induced and 10 mg/kg/day TQ administered group; SCI-induced and 30 mg/kg/day TQ administered group. TQ was given as intraperitoneal for three days prior to injury and four days following injury. Spinal cord segment between T8 and T10 were taken for histopathologic examination. Hemorrhage, spongiosis and liquefactive necrosis were analyzed semiquantatively for histopathological changes.

RESULTS: Administration of TQ at a dose of 10 mg/kg did not cause any significant change on the histological features of neuronal degeneration as compared to the SCI group ($p=0.269$); however, 30 mg/kg TQ significantly decreased the histological features of spinal cord damage below that of the SCI group ($p=0.011$).

CONCLUSION: Data from this study suggest that TQ supplementation attenuates trauma induced spinal cord damage. Thus, TQ needs to be taken into consideration, for it may have a neuroprotective effect in trauma induced spinal cord damage.

Key words: Experimental spinal cord injury; thymoquinone; histologic examination.

INTRODUCTION

Spinal cord injury (SCI) is one of the most devastating conditions leading to neurological impairment and disabilities.^[1] In SCIs, primary injury occurs after mechanical damage to neuronal and vascular tissues at the time of trauma. Just after mechanical injury, secondary injury occurs by the reduction of spinal cord microvascular circulation and the deleterious

biochemical effects of reactive oxygen species generation, cell membrane lipid peroxidation and inflammation.^[2,3] Therefore, agents with antioxidant and anti-inflammatory properties are proposed to be useful in trauma induced spinal cord damage.^[4] None of the clinically available anti-oxidant therapies has produced any clinically satisfactory intervention in trauma induced SCI due to its complexity.^[5] Therefore, there is still a significant need for effective and safer agents for the treatment of spinal cord injury.

Thymoquinone (TQ), the main active constituent of *Nigella saliva* seeds, is reported to have strong free radical scavenger and antioxidant^[6-9] and anti-inflammatory^[10,11] properties in different animal tissue models.

To the best of our knowledge, the neuroprotective effect of TQ in SCI has not been investigated. Therefore, this study was designed to investigate the potential protective effect of TQ in a model of traumatic SCI.

Address for correspondence: Nilgün Üstün, M.D.

Mustafa Kemal Üniversitesi Tıp Fakültesi, Fiziksel Tıp ve Rehabilitasyon Anabilim Dalı, Hatay, Turkey

Tel: +90 326 - 229 10 00 E-mail: drnustun@yahoo.com.tr

Quick Response Code



Ulus Travma Acil Cerrahi Derg
2014;20(5):328-332
doi: 10.5505/tjtes.2014.05021

Copyright 2014
TJTES

MATERIALS AND METHODS

Animals

Twenty-four adult male Wistar albino rats, weighing 300-350 g, were obtained from Mustafa Kemal University Laboratory of Experimental Animals. The animals were fed with a standard rat chaw and allowed access to water. All rats were kept in an air-conditioned room with 12-hour light and dark cycles, where the temperature ($22 \pm 2^\circ\text{C}$) and relative humidity (65–70%) were kept constant. All experimental protocols were approved by the Animal Care and Use Committee of Mustafa Kemal University, School of Veterinary Medicine.

Chemical

TQ (2 isopropyl-5-methyl-1,4-benzoquinone) was obtained from Sigma Chemical Co. (St. Louis, Missouri, USA) and dissolved in saline and heated at $60\text{--}80^\circ\text{C}$.

Experimental Design

Rats were randomly assigned into four groups of six rats each: One group served as controls where the rats received sham injury (laminectomy). Second group served as the SCI group that underwent SCI after laminectomy. Third group under-

went SCI and was given intraperitoneal administration of TQ aqueous solution at 10 mg/kg/day dose level for three days prior to and four days after SCI. Fourth group underwent SCI and was given intraperitoneal administration of TQ aqueous solution at 30 mg/kg/day dose level for three days prior to and four days after SCI.

Induction of SCI

The animals were anesthetized with intraperitoneal injection of 75 mg/kg ketamine (Ketalar, Eczacıbaşı, Istanbul, Turkey) and 10 mg/kg xylazine (Rompun, Bayer, Istanbul, Turkey). Anesthetized rats were positioned in a prone position. Their dorsal regions were shaved and cleaned with povidone-iodine. Under sterile conditions, following T6-T12 midline skin incision and paravertebral muscle dissection, spinous processes and laminar arcs of T8-T10 were removed. The dura was left intact. A well characterized weight-drop technique was performed for spinal cord trauma.^[12] The animals were subjected to an impact of 100 g/cm (10 g weight from 10 cm height) to the dorsal surface of the spinal cord. The force was applied via a stainless steel rod (3 mm diameter tip) rounded at the surface. The rod was dropped vertically through a 10 cm guide tube positioned perpendicular to the center of the spinal cord. Afterwards, the

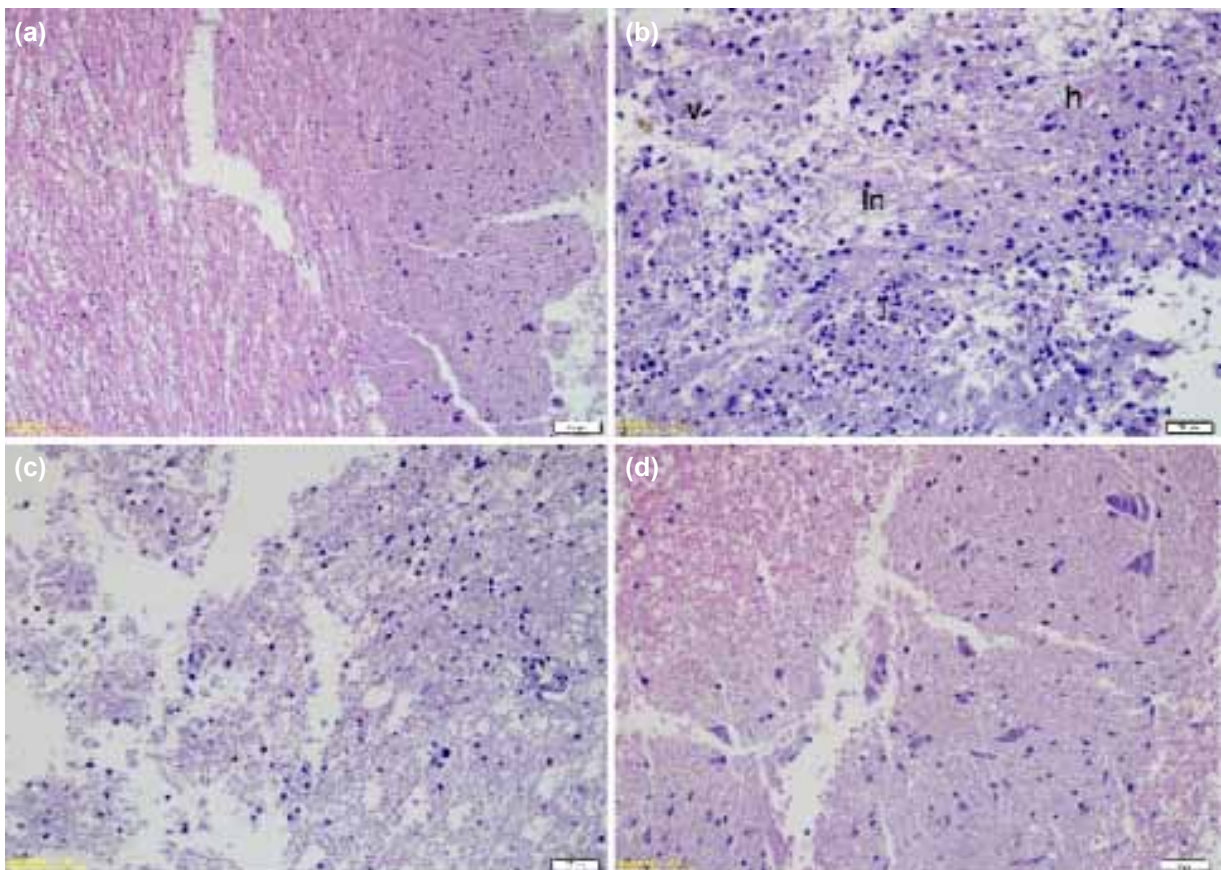


Figure 1. Light photomicrographs of the rats' spinal cord tissue sections (H&E, x 200). Sham-operated control group with preserved morphology (a). Spinal trauma group; hemorrhage (h), severe vacuolic degeneration (v), liquefactive necrosis (ln) and inflammatory infiltrate (i) (b). Degenerative changes remain with low doses of thymoquinone (TQ) (c). Improved spinal cord morphology with high doses of TQ (d).

muscles and the incision were sutured. Rats in the sham injury group underwent a similar surgical procedure as other groups; however, no spinal cord trauma was performed. A week after SCI induction, rats were sacrificed using an overdose of pentobarbital (200 mg/kg) and the same part of the injured spinal cord tissue samples were excised. The sample of the spinal cord tissue was stored in 10% buffered formaldehyde solution for histologic examination.

Histologic Analysis

For histological examination, all tissue samples were fixed at 10% buffered formaldehyde solution for 24 hours and processed according to routine light microscopic tissue processing technique. Formalin-fixed paraffin-embedded tissue sections (5 µm) were stained with hematoxylin and eosin (H&E) and examined by an Olympus DP20 camera attached-Olympus CX41 photomicroscope. To prevent inter-individual bias, all tissues were evaluated by the same pathologist (T.O.) who was uninformed of the groups and test materials. Hemorrhage, spongiosis and liquefactive necrosis were analyzed for histopathological changes. For histopathologic evaluation, a semi-quantitative grading system modified by Malinovsky et al.^[13] was used on all specimens as following: No abnormal cells and change (grade 0), mild hemorrhage, spongiosis (grade 1), moderate hemorrhage and spongiosis with liquefactive necrosis (grade 2), severe hemorrhage and spongiosis with glial cell proliferation and liquefactive necrosis (grade 3).

Statistical Analysis

Statistical analyses were performed using SPSS software package program (SPSS Inc., Chicago, IL, USA), version 13.0 for Windows. Kruskal-Wallis variance test was used to compare differences among groups. When analysis of variance showed significance, Mann-Whitney U-test was applied to determine the difference. Data were expressed as mean± SD. Values of $p < 0.05$ were accepted as statistically significant.

RESULTS

Light microscopic examination of the spinal cord tissue sections revealed a normal histological structure in the sham-operated control group (Fig. 1a). Histological examination of the spinal cord tissue sections of the SCI group showed moderate to severe hemorrhage, necrosis, inflammatory infiltrate and fibrosis (Fig. 1b). A statistically significant difference was found among the groups ($p=0.001$). Neuronal degeneration in the SCI group was significant compared to the sham-operated control group ($p=0.003$, Table 1). Administration of TQ at a dose of 10 mg/kg for three days prior to and four days after SCI did not cause any significant change on histological features of neuronal degeneration as compared to the SCI group ($p=0.269$, Table 1; Fig. 1c). However, 30 mg/kg TQ significantly decreased the histological features of the spinal cord damage below that of the SCI group ($p=0.011$, Table 1; Fig. 1d).

Table 1. Histopathologic evaluation scores of the groups

Rat	Control	SCI	SCI+TQ10	SCI+TQ30
1	0	2	2	1
2	0	3	2	1
3	0	3	3	2
4	0	3	2	1
5	0	2	3	1
6	0	3	2	1
Mean±SD	0.00±0.00	2.66±0.51	2.33±0.57	1.20±0.44
P		0.003 ^a	0.269 ^b	0.011 ^c

TQ: Thymoquinone; SCI: Spinal cord injured untreated group; SCI+TQ10: 10 mg/kg TQ treated spinal cord injured group; SCI+TQ30: 30 mg/kg TQ treated spinal cord injured group; histopathologic grading scores: 0, no abnormal cells and change; 1, mild hemorrhage, spongiosis; 2, moderate hemorrhage and spongiosis with liquefactive necrosis; 3, severe hemorrhage and spongiosis with glial cell proliferation and liquefactive necrosis. ^ap, compared with C group group; ^bp and ^cp, compared with SCI group.

DISCUSSION

This study was initiated to investigate whether TQ supplementation could reduce trauma induced spinal cord damage. The results of the present study demonstrated that treatment with 30 mg/kg TQ for three days prior to and four days after trauma had protective effects on trauma induced spinal cord damage. This was shown by marked decrease in the histopathological damage scores of the injured spinal cord tissues. This neuroprotective effect of TQ could be explained on the basis of its antioxidant^[6-9] and anti-inflammatory effects.^[10,11] To the best of our knowledge, this is the first report evaluating the neuroprotective effects of TQ on trauma induced SCI.

Reactive oxygen species are continuously produced during normal physiologic events and removed by antioxidant defense mechanism.^[14] The imbalance between reactive oxygen species and antioxidant defense mechanisms leads to lipid peroxidation and oxidative damage in the lipid bilayers surrounding both the cell itself and membrane-bound organelles.^[15] Recent studies have demonstrated that increase in reactive oxygen species and the decrease in the antioxidant defense mechanisms is a major contributor to the pathogenesis of trauma induced spinal cord damage.^[16,17] A variety of known antioxidants and anti-inflammatory agents have shown protective effects on traumatic SCI in experimental models and clinical trials.^[18-24] Toklu et al.^[18] have found that alpha-lipoic acid reduces oxidative stress on traumatic SCI. Sahin et al.^[19] have shown significant protective effects of curcumin on traumatic spinal cord tissues against oxidative damage. Karalija et al.^[20] have demonstrated better pathological findings by N-acetyl-cysteine and acetyl-L-carnitine in the early treatment of traumatic SCI by using quantitative immunohistochemistry and western blotting for neuronal and glial cell markers, and indicated a therapeutic potential for NAC and ALC in the

early treatment of traumatic SCI. Cemil B et al.^[21] have put forward better pathological findings by aged garlic extract in the traumatic SCI against oxidative damage. Erşahin et al.^[22] have reported that ghrelin could reduce SCI-induced oxidative stress and exert anti-inflammatory effects in the spinal cord following trauma.

In the present study, histological examination of trauma induced spinal cord tissue sections revealed moderate to severe hemorrhage, necrosis, inflammatory infiltrate and fibrosis. TQ at a dose of 10 mg/kg for three days prior to and four days after trauma did not cause any significant reduction in the histopathologic damage scores as compared to the spinal cord injured untreated group, while TQ at dose of 30 mg/kg for three days prior to and four days after trauma significantly reduced the histopathologic damage scores below that of the spinal cord injured untreated group. These results are consistent with the data^[25] demonstrating that TQ significantly decreased lipid peroxidation and increased the antioxidant levels in a model of hepatic ischemia reperfusion injury in a dose dependent manner.

Neuroprotective effect of TQ in the present study could be due to its free radical scavenging effect that could protect cell membranes against trauma-induced lipid peroxidation. It has been reported that TQ has strong antioxidant potentials through scavenging ability of different free radicals, especially superoxide scavenging activity that prevents oxidative injury in several tissues with the ability to inhibit lipid peroxidation and to preserve cell integrity.^[15,26]

In an injured cord, overactivation of inflammatory response is also a contributor to the trauma induced spinal cord damage.^[27] Marked neuroprotective effect with TQ in this study could also be explained by anti-inflammatory effect of TQ in addition to its antioxidant effects. TQ is reported to possess anti-inflammatory effects by inhibition of eicosanoid generation.^[10,11,26,28] The use of TQ has shown to have anti-inflammatory effects in several inflammatory diseases, including experimental allergic encephalomyelitis,^[29] colitis,^[30] arthritis,^[31] and bacterial prostatitis.^[32]

One limitation of this study was the lack of measurement of antioxidant enzyme activities and the degree of membrane lipid peroxidation in the injured spinal cord tissue. The other limitation of this study was the lack of motor testing of the animals. Although SCI results in motor dysfunction in various degrees among animals, these deficits were not unique for each animal. Therefore, motor tests are not reliable to evaluate the effects of trauma on spinal cord tissue.

In conclusion, data from this study suggest that TQ supplementation attenuates trauma induced spinal cord damage. Studies with presence of measurement of oxidant/antioxidant status and motor testing of the animals are needed to make inferences that are more reliable.

Conflict of interest: None declared.

REFERENCES

1. Wu B, Ren X. Promoting axonal myelination for improving neurological recovery in spinal cord injury. *J Neurotrauma* 2009;26:1847-56. [CrossRef](#)
2. Dumont RJ, Okonkwo DO, Verma S, Hurlbert RJ, Boulos PT, Ellegala DB, et al. Acute spinal cord injury, part I: pathophysiologic mechanisms. *Clin Neuropharmacol* 2001;24:254-64. [CrossRef](#)
3. Oyinbo CA. Secondary injury mechanisms in traumatic spinal cord injury: a nugget of this multiply cascade. *Acta Neurobiol Exp (Wars)* 2011;71:281-99.
4. Slemmer JE, Shacka JJ, Sweeney MI, Weber JT. Antioxidants and free radical scavengers for the treatment of stroke, traumatic brain injury and aging. *Curr Med Chem* 2008;15:404-14. [CrossRef](#)
5. Bains M, Hall ED. Antioxidant therapies in traumatic brain and spinal cord injury. *Biochim Biophys Acta* 2012;1822:675-84. [CrossRef](#)
6. Badary OA, Taha RA, Gamal el-Din AM, Abdel-Wahab MH. Thymoquinone is a potent superoxide anion scavenger. *Drug Chem Toxicol* 2003;26:87-98. [CrossRef](#)
7. Kruk I, Michalska T, Lichszteid K, Kładna A, Aboul-Enein HY. The effect of thymol and its derivatives on reactions generating reactive oxygen species. *Chemosphere* 2000;41:1059-64. [CrossRef](#)
8. Mansour MA, Nagi MN, El-Khatib AS, Al-Bekairi AM. Effects of thymoquinone on antioxidant enzyme activities, lipid peroxidation and DT-diaphorase in different tissues of mice: a possible mechanism of action. *Cell Biochem Funct* 2002;20:143-51. [CrossRef](#)
9. Nagi MN, Mansour MA. Protective effect of thymoquinone against doxorubicin-induced cardiotoxicity in rats: a possible mechanism of protection. *Pharmacol Res* 2000;41:283-9. [CrossRef](#)
10. Al-Ghamdi MS. The anti-inflammatory, analgesic and antipyretic activity of *Nigella sativa*. *J Ethnopharmacol* 2001;76:45-8. [CrossRef](#)
11. Houghton PJ, Zarka R, de las Heras B, Hoult JR. Fixed oil of *Nigella sativa* and derived thymoquinone inhibit eicosanoid generation in leukocytes and membrane lipid peroxidation. *Planta Med* 1995;61:33-6. [CrossRef](#)
12. Allen AR. Surgery of experimental lesion of spinal cord equivalent to crush injury of fracture dislocation of spinal column. A preliminary report. *JAMA* 1911;57:878-80. [CrossRef](#)
13. Malinovsky JM, Cozian A, Lepage JY, Mussini JM, Pinaud M, Souron R. Ketamine and midazolam neurotoxicity in the rabbit. *Anesthesiology* 1991;75:91-7. [CrossRef](#)
14. Duffy S, So A, Murphy TH. Activation of endogenous antioxidant defenses in neuronal cells prevents free radical-mediated damage. *J Neurochem* 1998;71:69-77. [CrossRef](#)
15. Dal-Pizzol F, Klamt F, Benfato MS, Bernard EA, Moreira JC. Retinol supplementation induces oxidative stress and modulates antioxidant enzyme activities in rat sertoli cells. *Free Radic Res* 2001;34:395-404. [CrossRef](#)
16. Hamann K, Durkes A, Ouyang H, Uchida K, Pond A, Shi R. Critical role of acrolein in secondary injury following ex vivo spinal cord trauma. *J Neurochem* 2008;107:712-21. [CrossRef](#)
17. Seligman ML, Flamm ES, Goldstein BD, Poser RG, Demopoulos HB, Ransohoff J. Spectrofluorescent detection of malonaldehyde as a measure of lipid free radical damage in response to ethanol potentiation of spinal cord trauma. *Lipids* 1977;12:945-50. [CrossRef](#)
18. Toklu HZ, Hakan T, Celik H, Biber N, Erzik C, Ogunc AV, et al. Neuroprotective effects of alpha-lipoic acid in experimental spinal cord injury in rats. *J Spinal Cord Med* 2010;33:401-9.
19. Sahin Kavaklı H, Koca C, Alici O. Antioxidant effects of curcumin in spinal cord injury in rats. *Ulus Travma Acil Cerrahi Derg* 2011;17:14-8. [CrossRef](#)

20. Karalija A, Novikova LN, Kingham PJ, Wiberg M, Novikov LN. Neuroprotective effects of N-acetyl-cysteine and acetyl-L-carnitine after spinal cord injury in adult rats. *PLoS One* 2012;7:e41086. [CrossRef](#)
21. Cemil B, Gökçe EC, Erdamar H, Karabörk A, Onur O, Heper Okcu A, et al. Effects of the aged garlic extract on spinal cord injury model in rat. *Ulus Travma Acil Cerrahi Derg* 2012;18:463-8. [CrossRef](#)
22. Erşahin M, Toklu HZ, Erzık C, Akakin D, Tetik S, Sener G, et al. Ghrelin alleviates spinal cord injury in rats via its anti-inflammatory effects. *Turk Neurosurg* 2011;21:599-605.
23. Hall ED. Antioxidant therapies for acute spinal cord injury. *Neurotherapeutics* 2011;8:152-67. [CrossRef](#)
24. Jia Z, Zhu H, Li J, Wang X, Misra H, Li Y. Oxidative stress in spinal cord injury and antioxidant-based intervention. *Spinal Cord* 2012;50:264-74.
25. Abd El-Ghany RM, Sharaf NM, Kassem LA, Mahran LG, Heikal OA. Thymoquinone triggers anti-apoptotic signaling targeting death ligand and apoptotic regulators in a model of hepatic ischemia reperfusion injury. *Drug Discov Ther* 2009;3:296-306.
26. El-Dakhkhny M, Madi NJ, Lember N, Ammon HP. Nigella sativa oil, nigellone and derived thymoquinone inhibit synthesis of 5-lipoxygenase products in polymorphonuclear leukocytes from rats. *J Ethnopharmacol* 2002;81:161-4. [CrossRef](#)
27. Fehlings MG, Nguyen DH. Immunoglobulin G: a potential treatment to attenuate neuroinflammation following spinal cord injury. *J Clin Immunol* 2010;30 Suppl 1:109-12. [CrossRef](#)
28. Marsik P, Kokoska L, Landa P, Nepovim A, Soudek P, Vanek T. In vitro inhibitory effects of thymol and quinones of Nigella sativa seeds on cyclooxygenase-1- and -2-catalyzed prostaglandin E2 biosyntheses. *Planta Med* 2005;71:739-42. [CrossRef](#)
29. Mohamed A, Shoker A, Bendjelloul F, Mare A, Alzrigh M, Benghuzzi H, et al. Improvement of experimental allergic encephalomyelitis (EAE) by thymoquinone; an oxidative stress inhibitor. *Biomed Sci Instrum* 2003;39:440-5.
30. Mahgoub AA. Thymoquinone protects against experimental colitis in rats. *Toxicol Lett* 2003;143:133-43. [CrossRef](#)
31. Tekeoglu I, Dogan A, Ediz L, Budancamanak M, Demirel A. Effects of thymoquinone (volatile oil of black cummin) on rheumatoid arthritis in rat models. *Phytother Res* 2007;21:895-7. [CrossRef](#)
32. Inci M, Davarci M, Inci M, Motor S, Yalcinkaya FR, Nacar E, et al. Anti-inflammatory and antioxidant activity of thymoquinone in a rat model of acute bacterial prostatitis. *Hum Exp Toxicol* 2013;32:354-61. [CrossRef](#)

DENEYSSEL ÇALIŞMA - ÖZET

Timokinon deneysel spinal kord yaralanmalı sıçanlarda spinal kord hasarını azaltır

Dr. Nilgün Üstün,¹ Dr. Mustafa Aras,² Dr. Tumay Özgür,³ Dr. Hamdullah Suphi Bayraktar,⁴ Dr. Fatih Sefil,⁵ Dr. Raif Özden,⁶ Dr. Abdullah Erman Yagiz¹

¹Mustafa Kemal Üniversitesi Tıp Fakültesi, Fiziksel Tıp ve Rehabilitasyon Anabilim Dalı, Hatay;

²Mustafa Kemal Üniversitesi Tıp Fakültesi, Beyin Cerrahisi Anabilim Dalı, Hatay;

³Mustafa Kemal Üniversitesi Tıp Fakültesi, Patoloji Anabilim Dalı, Hatay;

⁴Mustafa Kemal Üniversitesi Veterinerlik Fakültesi, Klinik Bilimler Anabilim Dalı, Hatay;

⁵Mustafa Kemal Üniversitesi Tıp Fakültesi, Fizyoloji Anabilim Dalı, Hatay;

⁶Mustafa Kemal Üniversitesi Tıp Fakültesi, Ortopedi ve Travmatoloji Anabilim Dalı, Hatay

AMAÇ: Spinal kord yaralanması (SKY) nörolojik bozukluk ve özürüllüğe yol açan en yıkıcı hastalıklarından biridir. Bu çalışmanın amacı deneysel SKY'lı sıçanlarda timokinonun (TQ) nöroprotektif etkilerinin histopatolojik olarak araştırılmasıdır.

GEREÇ VE YÖNTEM: Yirmi dört adet erkek Wistar albino sıçan dört gruba ayrıldı: Kontrol grubu; SKY grubu; SKY ve 10 mg/kg/gün TQ verilen grup; SKY ve 30 mg/kg/gün TQ verilen grup. TQ intraperitoneal günde tek doz yaralanmadan 3 gün önce ve yaralanmayı takiben 4 gün olarak verildi. T8-T10 spinal segmentleri histopatolojik inceleme için alındı. Segmentler histopatolojik olarak hemoraji, spongioz ve lifefaksiyon nekrozu açısından semikantitatif olarak analiz edildi.

BULGULAR: 10 mg/kg/gün TQ verilen SKY grubun spinal kord segmentlerinin histopatolojik incelemesinde anlamlı nöronal iyileşme saptanmazken (p=0.269), 30 mg/kg/gün TQ verilen SKY grubunda anlamlı düzeyde nöronal iyileşme saptandı (p=0.011).

TARTIŞMA: Bu çalışmadan elde edilen sonuçlar TQ takviyesinin travmaya bağlı spinal kord hasarını azalttığını göstermektedir. Bu nedenle TQ travmatik SKY'da, nöroprotektif etkileri olabileceği için, dikkate alınmalıdır.

Anahtar sözcükler: Deneysel spinal kord yaralanması; histolojik inceleme; timokinon.

Ulus Travma Acil Cerrahi Derg 2014;20(5):328-332 doi: 10.5505/tjtes.2014.05021