

**RENAL HYDATID CYST AND SITUS INVERSUS TOTALIS  
(A CASE REPORT)***BÖBREK KİST HİDATİĞİ VE SİTUR INVERTUS TOTALİS  
(OLGU SUNUMU)*Dr. Necmi KURT, Dr. Gürhan ÇELİK, Dr. H. Fehmi KÜÇÜK, Dr. Özden GÜL,  
Dr. Erol KUROĞLU, Dr. Gülüm ALTACA, Dr. Mustafa GÜLMEN,

**SUMMARY:** Although echinococcal disease is common in some parts of the world isolated renal involvement is rare. We present a single case of a renal hydatid cyst in a patient with situs inversus totalis.

**Key Words:** Renal hydatid cyst, Renal echinococcal cyst, Situs inversus totalis

A case of renal hydatid cyst which occurred in a patient with situs inversus totalis is reported. To our knowledge, there is no such case combined with situs inversus totalis reported in the literature.

**Case Report**

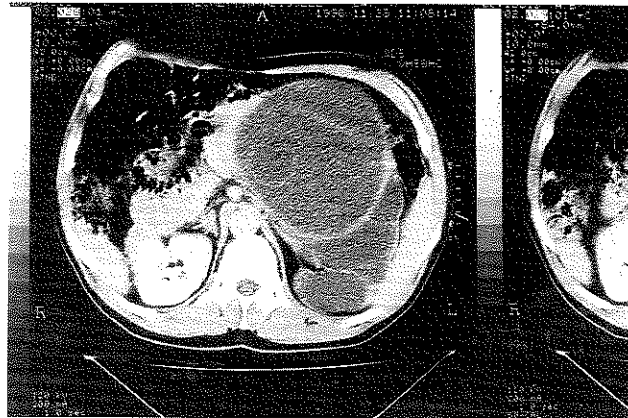
A 65 year-old man was admitted to the hospital with symptoms of abdominal pain and swelling. In physical examination, we found a mass in the left epigastrium which occupied all the left abdomen to the left inguinal region and passed across the midline to the right side. Besides, there was total situs inversus. Biochemical and urinary tests were in normal ranges. By abdominal ultrasound there was a 20x20 cm cystic, lobulated lesion which included septations in the left side of the abdomen and total situs inversus. Left kidney could not be demonstrated by the ultrasound. Weinberg complement fixation test and ELISA test were positive. By computed tomography of the abdomen and thorax, there were multiple cystic lesions containing daughter cysts which filled all the left side of the infrahepatic retroperitoneal area. According to this image cysts were stage III, but one of them was stage IV hydatid cyst (Fig1). Since the left kidney could not be seen clearly, an intravenous pyelography was performed which demonstrated a non-functional left kidney.

On exploration, there were multiple cysts located in the left retroperitoneum and also the proximal part of the left ureter was entering the cyst. The parenchyma was destroyed and almost invisible. There was another cyst at

the ureterocystic junction. Left nephrectomy together with excision of the hydatid cyst was performed.

The pathologic examination revealed a classical echinococcal cyst that involved the whole left kidney.

Fig 1: CT imaging of the cyst

**Discussion**

The life cycle of Echinococcus Granulosus and disease process of the hydatid cyst are described elsewhere (1).

Hydatid disease is usually seen in Asia, India, Africa and Middle East. Renal involvement is reported to be 2-3 % (2,3). Isolated urinary tract involvement is much rarer; the kidney is the site of involvement in such cases (2).

Renal cysts are usually single and are located in the cortex (4,5). In our case the cyst was lobulated and there

was another free cyst in the pelvic region. The cysts are reported to be asymptomatic when there is no connection with the renal collecting system. In our case although the cyst was in enormous size, it was asymptomatic. Those cysts may be infected secondarily and cause symptoms of urinary tract infection. Symptomatic patients may present with fever, palpable flank mass, hematuria and tenderness in the flank region. Cyst, communicated with the renal collecting system, may cause renal colic and hydronephrosis. Cyst fluid which enters to the renal collecting system may also cause allergic reactions including urticaria and anaphylaxis (6).

The treatment of renal hydatid disease is total excision of the cyst, whenever possible; otherwise nephrectomy can be performed. Tscholl and Ausfeld reported one case of renal hydatid cyst centrally located that was treated by orthotopic autotransplantation (7). Goel *et. al* reported four cases of renal hydatid cyst treated with percutaneous drainage (8). In the case reported here, there was a little renal parenchyma left; therefore a nephrectomy was performed. One year after the operation, the patient is healthy with no complication and recurrence of the disease.

## REFERENCES

- 1- Little JM: Hydatid Disease. In: Morris PJ, Malt RA (eds): *Oxford Textbook of Surgery*. 1<sup>st</sup> ed., Volume 2, New York, Oxford University Press Inc., 1994, pp 2507-2508
- 2- Kirkland K: Urological aspects of hydatid disease. *Br J Urol* 38:241, 1966
- 3- Ramus N, Mitchell JP: Renal hydatid disease. *Br J Surg* 61: 402, 1975
- 4- Martorana G, Giberts C, Pescatore D: Giant echinococcal cyst of the kidney associated with hypertension evaluated by CT. *J Urol* 126:99, 1981
- 5- Hartman DS: Radiologic pathologic correlation of the infectious granulomatous diseases of the kidney. *Monograph Urol* 6:43, 1985
- 6- Cohen MS: Granulomatous nephritis. *Urol Clin North Am* 13:647, 1986
- 7- Tscholl R, Ausfeld R: Renal replantation (orthotopic autotransplantation) for echinococcosis of the kidney. *J Urol* 133(3): 456, 1985
- 8- MC Goel, MR Agarwal, A Misra: Percutaneous drainage of renal hydatid cyst: early results and follow-up. *Br J Urol* 75: 724, 1995.