

RIGHT-SIDED DIVERTICULAR BLEEDING:
MANAGEMENT OF A SPECIFIC ENTITY

SAĞ KOLONDA DİVERTİKÜL KANAMISI: ÖZEL YAKLAŞIM

Dr. Selman SÖKMEN, Dr. Ahmet ÖNAL, Dr. Berna DEĞİRMENCİ, Dr. Hüseyin ASTARCIOĞLU, Dr. Mehmet FÜZÜN

ÖZET: Alt gastrointestinal kanaldan olan akut kanamaların etkin tedavisi, tanısal ve tedavisel hatalarını önlemek üzere yapılan ardışık araştırmalarla belirlenen esnek bir yaklaşım gerektirir. Tanısal çalışmaların özgül olarak sıralanması temel olarak hastanın klinik durumuna ve kanamanın hız ve yapısına bağlıdır. İzole sağ kolon divertiküler hastalığına, şiddetli alt gastrointestinal kanamanın kaynağı olarak sık rastlanmamaktadır. Sol taraf ile karşılaştırıldığında, izole sağ kolon divertiküler hastalığı divertikülit ve fistülizasyona göre daha sık oranda şiddetli kanama ile ortaya çıkmaktadır. Ayrıca, kanama için cerrahi sağ kolon hastalığında sola oranla daha çok gerekmektedir. Uygun tedavi için acil ve doğru tanı esastır. Bu olgu sonunun amacı tekrarlayan ve kendiliğinden duran kanama ile başvuran bir izole sağ kolon divertiküler hastalığının klinik özelliklerini vurgulamak ve değerlendirme basamaklarını ve cerrahi tedavisini tartışmaktır.

Anahtar Kelime: İzole sağ taraf divertiküler hastalığı, gastrointestinal sistem, hemoraji, cerrahi tedavi

SUMMARY: The effective management of acute bleeding in the lower part of the gastrointestinal (GI) tract requires a flexible approach of sequential investigations to prevent diagnostic and therapeutic errors. The specific sequence of diagnostic studies is determined primarily by the clinical status of the patient and by the rate and pattern of the bleeding. Isolated right-sided diverticular disease (IRSDD) as a source of massive lower GI bleeding is relatively infrequent. In comparison with left-sided (LS), IRSDD tended to present more often with profuse bleeding than with diverticulitis and fistulation. Surgery for bleeding was also required more often for RS than for LS disease. The need for urgent and accurate diagnosis is essential for proper management. The aim of this case report is to characterize the clinical entity of IRSDD presenting with recurrent self-limited bleeding and to discuss the evaluative steps and surgical treatment.

Key Words: Isolated right-sided diverticular disease, gastrointestinal tract, haemorrhage, surgical therapy

INTRODUCTION

Lower GI bleeding is considered massive and serious in nature if transfusions of 3 to 6 units of blood are required over 24 hours to maintain hemodynamic stability (1-4). Massive hematochezia occurs principally in the elderly, with the average age of such patients around 60 years in most series and a mortality of up to 21% (3-4). Several pathologic disorders may result in massive lower GI bleeding, however, the most common sources in the elderly include diverticula, arteriovenous malformations, inflammatory bowel disease, neoplasms, and internal haemorrhoids (1-6). Special caution must be paid to the isolated right-sided diverticular disease (IRSDD) because it is relatively infrequent in Western society, represents a heterogeneous group of cases with varying clinical presentation often confused with other disorders, and tends to present with massive bleeding more often than LS disease (1-8). Although spontaneous cessation of haemorrhage occurs commonly, massive and ongoing or recurrent haemorrhage occurs predominantly in RS colonic diverticula and requires immediate surgery usually after diagnostic interventions, if the bleeding permits, at

the same hospital admission (2,3,4,7,8). A histologically confirmed unusual case of IRSDD was presented to discuss the whole aspects of systematic assessment and proper management of massive bleeding from lower GI tract.

REPORT OF A CASE

A 76-year-old man, medical doctor, had recurrent episode of lower GI tract bleeding and was admitted to the hospital. Physical examination showed an ill-appearing, frail patient poorly defining discomfort in the abdomen. He complained of slight alterations of bowel habits and vague, intermittent abdominal pain for four months, and a bout of massive rectal bleeding ten days ago. He did not seek medical attention at that time. The abdomen was uniformly distended with no definite rigidity, tumoral lesion, or any other sign, but tenderness in the lower quadrants of the abdomen were marked. Findings from the rest of the examination were normal. He was taking antihypertensive medication for years and operated for prostatic carcinoma fifteen years ago. His initial vital functions were as follows: the pulse rate; 94 beats per minute; blood pressure, 110/60 mm Hg; and respirations, 20/min. The temperature was 37.8 C. The hematocrit and hemoglobin values were 23% and 7.3 g/dl while as the platelet, red and white blood cell count were $260 \times 10^9/L$, $3.95 \times 10^{12/L}$ and $7.4 \times 10^9/L$, respectively. Digital rectal

Dokuz Eylül University, School of Medicine
Correspondence to: Dr. Selman SÖKMEN
Department of Surgery, Dokuz Eylül University, School of
Medicine, İnciraltı, 35340 İzmir, Turkey

examination revealed melena , mimicking upper GI tract bleeding. Prompt resuscitation with crystalloid solutions, typing and cross-matching for blood, and diagnostic nasogastric intubation were the initial steps besides a coagulation screen. The nasogastric aspirate showed no obvious blood but the presence of bile. Other clinical and laboratory measures initiated to prepare the patient for emergency surgery in the event that it was required. Although the reliability of the examination after evacuation was compromised by inadequate visibility, no lesion was seen in the distal 30cm through the sigmoidoscope and concurrent esophagogastroduodenoscopy (EGD) ruled out an upper source of bleeding except atrophic gastritis. Fortunately , the patient stabilized with intravenous fluids and blood transfusions. Because of the vigorous bleeding at the initial admission and inabilities for a successful colonoscopy set-up , angiography was performed. However, urgent arteriography was unsuccessful in demonstrating the lesion. The bleeding was thought to be ongoing , so a Tc-99m-labeled RBC scan was done rapidly by using modified in vivo labeling method. In this method, the patient's blood was pretinned with an IV injection of stannous ion, and 20 minutes later blood was drawn back into an anticoagulated syringe to which 20 mCi (740 MBq) of Tc-99m Tc O4- was added. This syringe was gently inverted once a minute for 10 minutes, and the contents were reinjected into the patient. Tc-99m labeled RBC scan was performed with gamma camera equipped with low-energy

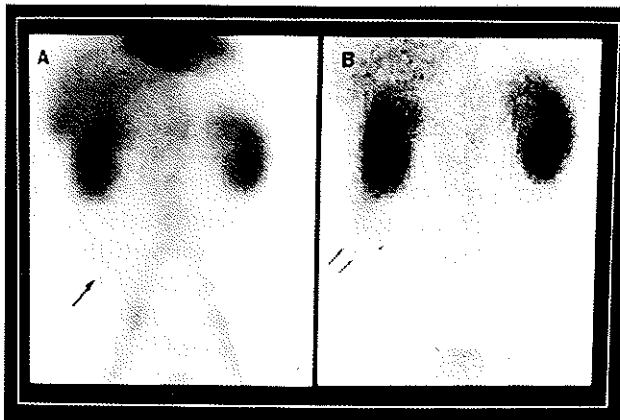


Fig. 1: Tc-99m-labeled RBC scan showed activity accumulation in the cecum and ascending colon at 6 hour (A) and in the ascending colon at 24 hour (B) suggestive of intermittent gastrointestinal bleeding.

general purpose collimator. The patient was placed under the dedector in supine position. After radiopharmaceutical was injected as an IV bolus injection, dynamic images were obtained for first 2 minutes, then 1 minute images were obtained at 5, 10, 15, 30 minutes, 1 hour, 6 hour and 24 hour. There was no evidence of gastrointestinal bleeding in the early images. But at the 6th and 24th -hour images, activity was observed in the cecum and ascending colon suggestive of intermittent

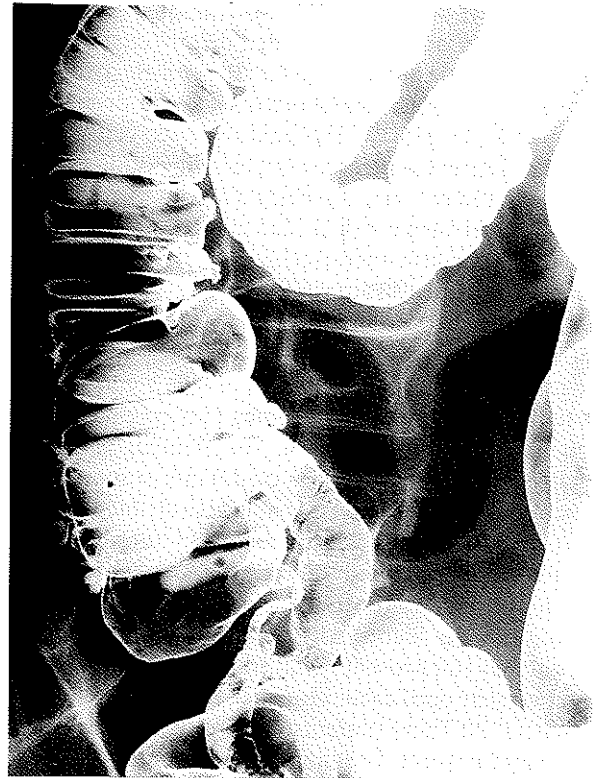

Fig. 2: This barium enema study demonstrated several right-sided Diverticula

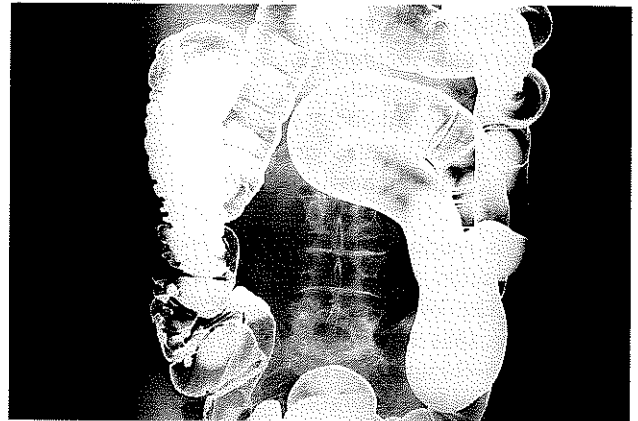


Fig. 3: Contrary to common, RSD are not associated with left-sided diverticula

gastrointestinal bleeding (Fig.1).

In the intensive critical care setting, the general condition and hemodynamic parameters of the patient were improved and reached an euvolemic state, and spontaneous resolution of bleeding episode occurred in hours. Delayed colonoscopy was performed after a mechanical bowel preparation: there were a lot of non-bleeding diverticula localized in cecum and ascending colon. The size of right -sided diverticula was about 5 to 7 mm. There were no detectable lesions in other segments of the colon. In addition to direct visualization of diverticula, barium examination was done for the other probable

manifestations of their complications and the confirmation: an isolated right sided diverticulosis (Fig.2) sparing the left side of the colon(Fig.3). Semi-elective right hemicolectomy and ileotransversostomy was performed at exploration for IRSDD. The postoperative course was uneventful. There was no recurrent bleeding during the 6-months of follow -up. Histopathologic examination revealed diverticulosis coli in the right hemicolectomy specimen, particularly mentioning that the continuity of the muscular layer was extensively damaged and replaced with hypervascularized lamina propria.

DISCUSSION

The management of lower GI bleeding is a conundrum for a number of reasons (4): Bleeding may originate from any portion of the GI tract (4-6). The bleeding is usually intermittent , and the source may be difficult or sometimes impossible to identify when it is not actively bleeding (1-4). This is a condition in which emergency surgery , with significant morbidity and mortality, may be required before a specific diagnosis or even a specific site of bleeding, can be identified(1-8). Even radical surgical treatment may not prevent recurrent bleeding(3-4). There is no universally applicable sequence of investigations of treatments.(1-8) These patients present with frank blood or dark maroon stools. The clinical specific entity of IRSDD and bleeding which is uniquely common in Asians(1,3,7,8), needs further attention: Potier is credited with reporting the first case of diverticulum of the cecum in 1912. (1) Diverticula limited to the cecum and ascending colon probably account for less than 1% of all cases of diverticulosis in the Western countries(1,4,7,8).

In other words, only about 6% to 7% of patients with diverticulosis do not have sigmoid colon involvement(3). The reason have never been discovered (1,4). It is often misstated that diverticulosis is a source of bleeding ; in fact , generally a single diverticulum is responsible for a bleeding episode, regardless of the number of other diverticula. The evaluation and treatment of painless haemorrhage, that may be minor self-limiting or may be severe and life-threatening, typical of diverticular disease begins with rapid restoration of circulating volume. Obvious sources of lower colonic bleeding should then be excluded by rectal examination and rectosigmoidoscopy(RSS)(1-8). EGD should be the next diagnostic and potentially therapeutic maneuver after stabilizing the cardiovascular system(1-8). It should be remembered that the stomach and particularly the duodenum may be site of bleeding in spite of negative nasogastric aspirate test(3-4). Spontaneous cessation of haemorrhage occurs commonly (85%) and is best followed by colon purgation to remove clot, followed by colonoscopy (1-8). If the colonoscopy is negative and bleeding does not recur, a barium enema is the next test(2). If this shows no lesion requiring surgery or is negative and there is no recurrent bleeding, "watchful waiting" policy alone is warranted(1,2,5). In the actively bleeding patient

with normal RSS and EGD (or if bleeding alternatively ceases and recurs), angiography (2,3,5,6) or scintigraphic studies (4) should be performed as soon as possible(1-8). The order in which these tests should be performed is really controversial(1-8). However, angiography is the study likely to determine the exact site and source of the bleeding, if it continues at a rate of more than about 0.5 ml/min. Should a source of active bleeding be identified, angiography facilitates selective infusion of vasopressin(0.2 units/min for 6 to 12 hours), which mostly temporarily stops or slows the ongoing exsanguination and makes possible more through resuscitation and semi-elective resection of the bleeding segment of colon (1-8). However, caution should be exercised in embolization for intestinal lesions as ischemic necrosis may occur and early recurrent bleeding can be expected in 15% to 20% of patients (1-6). At slower bleeding rates, 0.1 ml/min., arteriography may be unsuccessful or inaccurate in demonstrating the lesion. In such situations, scintigraphy with labeled erythrocytes may be useful by detecting intermittent bleeding due to longer circulating times despite a slightly lower minimal detectable bleeding rate (0.1 to 0.35 ml/min) (9). But sometimes the exact localization of the bleeding may be difficult , especially when scintigraphy is positive at delayed images (9).

Colonoscopy which offers the opportunity for both specific diagnosis and nonsurgical therapy is indicated as the initial study in stable patients (2,4,7). The diagnosis can be established in about half of the patients examined by this technique. The conundrum here is that during and immediately after bleeding episode , in the absence of a mechanical bowel preparation , colonoscopy is extremely difficult to perform with safety and is more often than not non -diagnostic because of large amounts of blood obscuring the mucosa(4). On the other side, by the time the patient presents to the hospital, the bleeding from IRSDD may already stop spontaneously; even so, the passage of blood may be ongoing owing to the large quantity of blood still in the colon (2-4). Therefore, it may be very difficult to tell whether bleeding is continuing , and whether to order a technetium- labeled RBC scan or an arteriogram, both of which are helpful only if the source continues to bleed(2-5). Ba enema should never be the initial test in patients with diverticular bleeding, because it precludes angiography or colonoscopy until the contrast medium is purged. Moreover, it excludes only mass lesions and can not localize the bleeding site (1-8). Exploratory laparotomy as a diagnostic tool was reserved for patients in whom all investigations, often including repeated examinations, remained negative (3-5). Newer techniques such as intraoperative panendoscopy and/or angiography for localization of the indeterminate bleeding site have been described but are unproven(2). The prognosis of isolated right-sided diverticular bleeding which has been localized preoperatively is generally good (1-8). Most of the diverticular bleeding stops spontaneously and does

not occur(1-8). Treatment for persistent or recurrent bleeding , occurs in 20% to 30% of patients as a separate episode, from a known diverticular source is traditionally to remove the affected segment of colon which carries a 5% to 9% mortality rate(1-8). Difficulty arises if the site of bleeding can not be localized preoperatively(10%-12%). In the past, blind segmental resection for an unidentified source of bleeding was done frequently, but the rate of rebleeding and the high eventual mortality have eliminated this practise(1-8). Today, total abdominal colectomy with ileoproctostomy is the procedure of choice ,because the patient's welfare depends on cessation of the bleeding , and blind segmental resection does not guarantee this(1-8). Although the operative risk is higher for total colectomy, it is justified to prevent the even higher morbidity and mortality when bleeding is not controlled at the initial operation. Moreover, if the patient is too unstable to undergo the complete procedure, total colectomy followed by ileostomy and closure of the distal segment can be done with bowel continuity established later under elective circumstances(1-8).

In conclusion, the authors do think that for the management of bleeding right-sided diverticular disease, several keypoints merit notation: colonoscopy should be performed initially if the bleeding has ceased. Conversely, angiography should be performed initially if bleeding persists. The most efficacious management of bleeding that is slow or transient, however, is still controversial. An aggressive and logical diagnostic work-up identifies the site of bleeding preoperatively in 85% to 90% of patients. So called "blind subtotal colectomy" for massive bleeding in the lower part of the GI tract need not be required with use of a through, and flexible systematic approach.

KAYNAKLAR

- 1- Haubrich WS. Diverticula and diverticular disease of the colon. In: Berk JE, Haubrich WS, Lakser MH, Roth JLA, Schaffner F, eds. *Bockus Gastroenterology* , 4th Ed: Philadelphia: W.B.Saunders Co., 1985.
- 2- Dietzen CB, Pemberton JH. Diverticulitis. In: Yamata T. *Textbook of Gastroenterology*, 2. Ed: Philadelphia: JB Lippincott Co., 1991.
- 3- Rege RV, Nahrwold DL. Diverticular disease. *Curr Prob Surg* 1989; 26(3): 171-174.
- 4- Billingham RP. The conundrum of lower gastrointestinal bleeding. *Surg Clin North Am* 1997; 77(1): 241-252.
- 5- Moncure AC, Tompkins RG, Welch CE, et al. Occult gastrointestinal bleeding: Newer techniques of diagnosis and therapy. *Adv Surg* 1989; 22: 141-178.
- 6- Wagner HE, Stain SC, Gilg M, et al. Systematic assessment of massive bleeding of the lower part of the gastrointestinal tract. *Surg Gynecol Obstet* 1992; 175: 445-449.
- 7- Wong SK, Ho YH, Leong AP, et al. Clinical behavior of complicated right-sided and left-sided diverticulosis. *Dis Colon Rectum* 1997; 40(3): 344-48.
- 8- Pieterse AS, Rowland R, Miliuskas JR, et al. Right-sided diverticular disease of the colon: a morphological analysis of 16 cases. *Aust NZJ Surg* 1986; 56(6):471-475.
- 9- Wilson AM. *Gastrointestinal Tract*. In: Wilson AM. *Textbook of Nuclear Medicine*. 1st Ed: Philadelphia: Lippincott-Raven Publ., 1998