

## Management of shotgun induced open fractures of the humerus with Ilizarov external fixator

Av tüfeği yaralanmalarına bağlı olarak oluşan açık humerus kırıklarının Ilizarov eksternal fiksatorü ile tedavisi

Güvenir OKCU,<sup>1</sup> Kemal AKTUĞLU,<sup>2</sup>

### BACKGROUND

Our aim was to evaluate the clinical efficacy of Ilizarov external fixator used for the management of shotgun induced open humeral fractures with special emphasize on neurovascular sequelae.

### METHODS

The authors retrospectively reviewed eleven shotgun induced open humeral fractures managed with emergent application of Ilizarov external fixator. No patient had associated neurovascular injury. All fractures were stabilized with Ilizarov external fixator immediately after meticulous debridement and irrigation under emergent conditions .

### RESULTS

With Ilizarov fixation technique complete bony union occurred in all patients within 14 to 44 weeks (average, 21 weeks) postoperatively.. One patient required a second intervention in order to adjust the external fixator rings. Two patients required a rotational fasciocutaneous flap so as to handle the soft tissue coverage problem. Superficial pin tract infection was present in eight patients, however in none of the patients deep tissue infection or osteomyelitis has been observed. Good to excellent results were achieved in 10 patients with Ilizarov fixation technique according to the rating system proposed by Smith and Cooney.

### CONCLUSION

Emergent Ilizarov external fixation is a safe method of obtaining a functional limb in the management of shotgun induced open humeral fractures with severe soft tissue damage.

**Key Words:** Humerus, Ilizarov external fixator, open fracture

### AMAÇ

Av tüfeği yaralanmaları sonucunda oluşan açık humerus kırıklarının tedavisinde Ilizarov eksternal fiksatorünün klinik etkinliğini kırık iyileşmesi ve özellikle nörovasküler sekeller açısından araştırmak.

### GEREÇ VE YÖNTEM

Açık humerus kırığı nedeni ile acil olarak debridman, irigasyon ve ardından Ilizarov eksternal fiksatorü ile kemik tespiti yapılan 11 olgu çalışma grubunu oluşturdu. Hiçbir hastada damar-sinir yaralanması oluşmamıştı.

### BULGULAR

Av tüfeği yaralanmaları sonucu açık humerus kırıkları olmuş hastaların tümünde postoperatif 14 ila 44 hafta arasında komplet kemik kaynaması olduğu gözlemlendi (ortalama 21 hafta). Bir hastaya ikinci bir girişim yapılarak rod ve halkalar yeniden düzenlendi. İki hastada yumuşak doku sorunu rotasyonel fasyökütanöz flep kullanılarak çözüldü. Sekiz hastada postoperatif dönemde yüzeysel çivi dibi enfeksiyonu gelişmesine karşın hiçbirinde derin enfeksiyon veya osteomyelit oluşmadı. Smith ve Cooney'in ileri sürdüğü kriterlere göre yapılan değerlendirmede toplam 10 hastada iyi ve çok iyi fonksiyonel sonuçlar elde edildiği gözlemlendi.

### SONUÇ

Av tüfeği yaralanmaları sonucu açık humerus kırıkları Ilizarov fiksatorüyle tedavi ettiğimiz hastalardan elde ettiğimiz bulgular ve literatür bilgileri göz önüne alındığında ciddi yumuşak doku hasarının eşlik ettiği açık humerus kırıklarında Ilizarov eksternal fiksatorü ile fiksasyon tekniğinin herhangi bir nörovasküler hasara neden olmaksızın hastaların fonksiyonel bir ekstremiteye kavuşmasında etkili bir tedavi yöntemi olduğu sonucuna varılmıştır.

**Anahtar Sözcükler:** Humerus, Ilizarov eksternal fiksatorü, açık kırık, ateşli silah yaralanması

<sup>1</sup>Celal Bayar University, Medical Faculty, Department of Orthopaedics & Traumatology, Manisa-Turkey <sup>2</sup>Ege University, Medical Faculty, Department of Orthopaedics & Traumatology, Izmir-Turkey

Celal Bayar Üniversitesi, Tıp Fakültesi, Ortopedi ve Travmatoloji Anabilim Dalı, Manisa

Close-range shotgun injuries of the upper extremity with skeletal instability and soft tissue disruption are associated with significant morbidity, prolonged periods of functional incapacity and hospitalization.<sup>[1,3]</sup> Open fractures of the humerus due to high energy traumas are usually slow to unite and multiple operations are frequently required to obtain union.<sup>[3]</sup> These injuries represent a major challenge to the orthopaedic surgeon. Besides, aggressive soft tissue management with skeletal stabilization and management of neurovascular injury are necessary for successful outcome.<sup>[4]</sup> The aims of the treatment include eradication of bacterial colonization, obtaining a stable soft tissue envelope and restoration of bony stability.<sup>[5]</sup> Internal fixation as a choice is unwise to apply as there is extensive soft tissue injury with high risk of contamination. External fixator can be a useful alternative for these fractures.<sup>[6]</sup>

The purpose of this study is to report our experience and to determine the clinical impact of Ilizarov method in the management of shotgun induced open humeral fractures.

## PATIENTS AND METHODS

From January 1992 through December 2000, 13 patients with shotgun-induced open fractures of the

humerus who had been managed with immediate Ilizarov external fixator application were reviewed retrospectively. Two patients were lost to follow-up.

After obtaining the approval of the ethical committee of our institution, all medical records and radiograms were reviewed by the authors. Eleven patients were referred back to our clinic for re-examination. All of the injuries were encountered in civilian practice and all of them were shotgun wounds leading to contaminated open fractures.

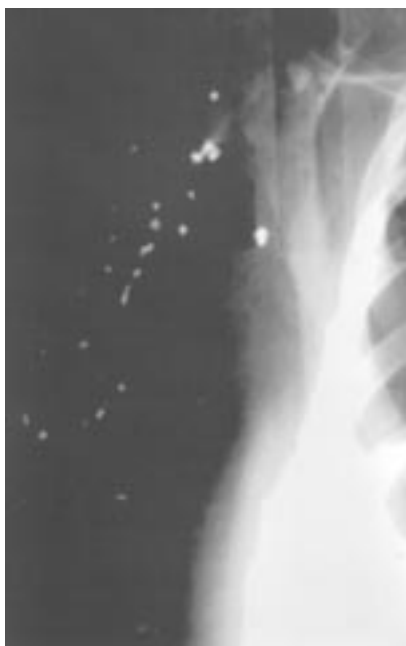The fractures were classified according to the AO Comprehensive Classification of Fractures of Long Bones.<sup>[7]</sup> Classification of the soft tissue injuries was done according to the system of Gustilo and Anderson.<sup>[8]</sup> (Table 1).

All patients were resuscitated at the emergency department. The exact location of entry and exit portals, neurovascular status of the extremity and injuries to other systems were assessed carefully during initial examination. Radiographic evaluation including ipsilateral elbow and shoulder was done. No fracture had an intraarticular extension distally and/or proximally. After samples for routine wound cultures were taken, the wounds were dressed and the limb was immobilized with a temporary splint. Tetanus toxoid (0.5 ml.) was given in the emergency

**Table 1:** Characteristic features of the patients

Patient	Sex / Age (years)	Fracture Location	Fracture Classification AO / ASIF Gustilo-Anderson	Follow up (months)	Time to union (weeks)	Additional procedures
1	M / 38	Midshaft	12-C1 / III A	40	18	
2	M / 17	Midshaft	12-C1 / III A	24	17	Skin graft
3	F / 45	1/3 distal diaphysis	12-B1 / III A	44	14	
4	M / 49	Midshaft	12-B1 / III B	33	16	Local rotational flap
5	M / 44	1/3 distal diaphysis	12-B3 / III A	90	17	
6	M / 64	1/3 distal diaphysis	12-C1 / III A	26	20	
7	M / 39	1/3 proximal diaphysis	12-C3 / III A	30	25	Skin graft
8	M / 34	1/3 proximal diaphysis	12-C1 / III B	25	21	Local rotational flap
9	F / 29	1/3 distal diaphysis	12-B3 / III A	28	22	
10	M / 56	Midshaft	12-C3 / III B	34	44	Adjustment of Ilizarov system
11	M / 47	Midshaft	12-C1 / III A	44	17	

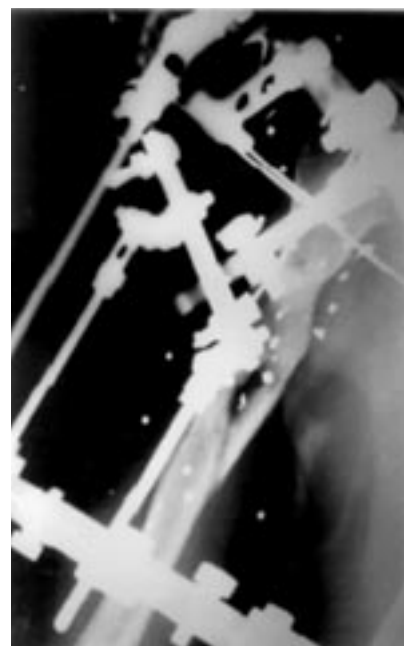
M0 male / F: female



**Figure 1:** Thirty-nine year old man, anteroposterior radiogram of a complex proximal humerus fracture.



**Figure 2:** Anteroposterior radiogram of the humerus taken after application of the Ilizarov frame.



**Figure 3:** X-rays taken 25 weeks postinjury documents fracture union before removal of the frame.

room. All patients received cefazolin (3 g.IV) and gentamicin (240 mg IV) daily. This antibiotic regimen was continued for three to ten days because of the associated injuries. Associated injuries included two hemothoraces, two pneumothoraces and one abdominal penetrating injury. No major nerve and arterial injury of the limb was encountered in any patient.

All patients were operated under emergent conditions on a radiolucent table with the patient in beach chair position. They underwent debridement, including excision of the entry and exit wounds, exposed fascia and muscle and removal of all the foreign bodies. No forceful attempt was performed to remove the deeply seated lead pellets (Figure 1). The wounds were thoroughly cleansed with 3 to 5 liters of Ringer's Lactate solution, then left open. The fractures were fixed by closed reduction under fluoroscopic guidance with continuous longitudinal traction by an assistant. If the position of the fractured ends was acceptable, Ilizarov external fixator was applied without disturbing the fracture site. The combined circular-semicircular apparatus was constructed by securing the bone fragments to the rings with the aid of 1.8 mm Kirschner wires. Schanz

screws were not used in any patient. Stabilization was achieved by a 5/8 half ring with three Kirschner wires in the proximal fragment and two full rings with two Kirschner wires in each of the distal fragment according to the Russian technique<sup>[9]</sup> (Figure 2). This type of frame was used in all patients. All of the Kirschner wires were inserted through a 1 to 2 cm. skin incision. After performing blunt dissection down to the bone, the pins were inserted by using drill guides to minimize the possibility of neurovascular injury.<sup>[10]</sup> Fluoroscopic control was done in every step in order to confirm the wire location precisely. The final reduction was checked by fluoroscopy, and if there was any malalignment of the fracture site, it was corrected by minor adjustments through the frame before tightening the connections.

The wounds were inspected every day. Second looks and staged debridements were performed as required after a delay of 48-72 hours. The wounds were closed by delayed primary sutures. Two limbs required rotational flaps to cover the soft tissue defect between 5 to 14 days after the injury. A releasing incision was done in 2 patients and the wounds were covered by split skin grafts in another two patients. All patients were encouraged vigor-

ously for active and early motion of the elbow and shoulder joints beginning from the first post-operative day . The patients were re-evaluated at every 3 to 6 weeks intervals after the discharge until the bony union was achieved. The degree of the fracture union was re-evaluated radiologically in each visit. When the radiograms showed solid union on two orthogonal projections , the frame and wires were loosened. If the patient felt no pain , they were removed (Figure 3). The range of motion of the elbow and the shoulder was assessed clinically and measured with a goniometer in the standing position at the last follow-up visit. The functional assessment of the patients was done according to the rating system of Smith and Cooney.<sup>[11]</sup>

## RESULTS

We reviewed two female and nine male patients with an average age of 42 years (17-64 years). All of the patients were right-handed. The left side was injured in four, and right side in seven patients. Eight type III A and three type III B open fractures were examined. The fractures were located in the humeral midshaft in five, one third of the proximal diaphysis in two and one third of the distal diaphysis in four patients (Table 1).

The average follow-up period was 38 months (24-90 months). The average duration of hospitalization was 18 days. Radiographic callus formation was seen at an average of 9 weeks (6 to 16 weeks). However, complete bony union occurred in all patients at an average of 21 weeks (14 - 44 weeks). The duration of external fixator averaged 22 weeks (15 to 40 weeks ). Ilizarov external fixation was the definitive treatment method in all patients. None of the patients had in the need for further surgical intervention to achieve union. But only one patient required a reoperation to adjust the external fixator rings 10 days after the first operation in order to accomplish a better alignment.

One patient developed a soft tissue coverage problem during the postoperative period but it was managed with temporary removal of some parts of the external fixator and a rotational fasciocutaneous local flap Kirschner wire breakage occurred in 2 two patients and managed successfully by replacing them with the new ones. In one patient, we had to remove external fixator before obtaining a solid

union because of psychological intolerance. The limb in this patient was protected with Sarmiento-type orthosis until the bony union was achieved. In another patient, the fractured fragments were compressed and disunited sequentially since no callus was imaged on the X-rays at 12 weeks . This fracture eventually healed at 44 weeks. All fractures healed with less than 15 degrees of varus or valgus alignment and 10 degrees of recurvatum or antecurvatum deformity. The average shortening of The extremity shortened 1,2 cm on the average.

Superficial pin tract infections developed in 8 patients. However, all patients responded to oral antibiotics and daily meticulous local pin care. No deep infection was seen in any patient. Neither neural nor arterial damage was encountered in any patient after the external fixation.

At the final follow up, the average arc of elbow motion was 80 degrees (60 to 120 degrees). Mean ranges of elbow flexion and extension were 100 degrees (70-120 degrees) and -20 degrees (0 to -40 degrees) respectively. Mean ranges of shoulder abduction, forward flexion, external rotation, and internal rotation were 120 degrees (90-160 degrees), 155 degrees (140-180 degrees), 40 degrees (30-65 degrees) and 50 degrees (40-80 degrees) respectively. Good to excellent results were achieved in 10 patients. Because of a prolonged stay of external fixator in situ due to a delayed union, one patient had limited shoulder, elbow function and working capacity.

## DISCUSSION

The incidence of gunshot wound related orthopaedic injuries in modern societies has increased at an alarming rate over the past years. It is the upper extremity that is commonly injured.<sup>[12,13]</sup> The civilian gunshot wound is usually a low-velocity injury. Damage is confined to the projectile pathway only.<sup>[12,14]</sup> Usually, these injuries do not require extensive debridement. Thereby, with minimal debridement of the soft tissues, removal of foreign material and with appropriate antibiotic regimen, the incidence of deep tissue infection and osteomyelitis is low.<sup>[12,13,15,16]</sup>

However, high-velocity bullets and close range shots may cause extensive soft tissue damage and

comminuted fractures.<sup>[17]</sup> The wounds may be contaminated by bacteria, thus potentially leading to a deep infection. Gustilo has shown that the main prognostic factor in these fractures is the extent of soft tissue injury.<sup>[8]</sup> Consequently, Oestern and Tscherne<sup>[18]</sup> defined all gunshot wounds and fractures as Grade III open fractures and proposed aggressive surgical debridement to prevent deep infection.

The goals of the management of shotgun fractures of the extremities are not only the salvage of the extremity but also prevention of colonization and infection, provision of stable soft tissue envelope and the maintenance of adequate function of the extremity. Significant morbidity has been reported following both operative and nonoperative management of gunshot fractures of the humerus.<sup>[19]</sup> Those fractures represent a major challenge to the orthopaedic surgeon because of the proximity of the neurovascular structures. According to Smith and Cooney<sup>[11]</sup>, the combination of neurovascular injury and musculoskeletal damage is usually associated with significant morbidity and a high risk of amputation.

High velocity and/or close-range shots often lead to comminuted fractures in the patients whose fractures could not be reduced and maintained with conservative methods using either a hanging arm cast or a functional brace.<sup>[19]</sup> Local management of the wound with a cast or a brace is also bothersome. Brettler<sup>[12]</sup> reported the results of conservative treatment of fractures induced by low-velocity gunshot. There were two nonunions and one delayed union in six displaced humeral shaft fractures. Chapman.<sup>[20]</sup> reviewed the results of primary internal fixation in open fractures and came across a high incidence of deep infection. He treated twenty-seven open humeral fractures (twenty Grade I, three Grade II, four Grade III) with internal fixation. The infection rate was greater than 40 percent in Grade III fractures. Higher complication rates for gunshot fractures managed with internal fixation have also been reported by Wild and Hanson.<sup>[21]</sup>

Stabilization of fractures by an external fixator can be considered as a minimal invasive surgery and it is usually preferred to stabilize open, complex fractures and in patients with polytrauma. One of the major indications of external fixation is highly con-

taminated open fractures associated with extensive soft tissue damage.<sup>[6,21,22]</sup> The use of an external fixator for gunshot fractures is proposed by many authors.<sup>[21,25]</sup> External fixation provides immediate fracture stabilization, facilitates neurovascular repair and if required subsequent soft tissue surgery and minimizes the possibility of deep infection. The fractured fragments can be compressed, distracted or realigned as needed. Local wound care can be done easily. Many authors prefer unilateral external fixator with at least two pins below and above the fracture line.<sup>[24,25]</sup> However, the tensioned transosseous wires in Ilizarov system allow firm fixation and also large butterfly fragments can be aligned with the help of olive wires with close reduction technique.<sup>[2,9,22]</sup> Ilizarov external fixator offers greater mechanical stability than the monolateral external fixators.<sup>[6]</sup> The Ilizarov method usually allows progressive reduction obviating the need for a second intervention in the case of the malalignment of the fragments during the initial surgery.<sup>[22]</sup>

Prompt return to functional integrity of the arm and shoulder is also possible with Ilizarov frame. Patients can resume their daily activities rapidly. Thus, the technique has the advantage of providing immediate functional mobilization.

Smith and Cooney<sup>[11]</sup> reported a 22% incidence for nonunion in their review of nine humeral fractures. In the present study, we did not see any incident of nonunion, which we thought that it is mainly due to the excellent stability that we achieved easily with Ilizarov method. Neither deep infection nor chronic osteomyelitis was seen in any patient. There were good to excellent functional results in ten patients which were significantly better than the previous reports. Owing to the fact that none of our patients had neurovascular injury, our functional results were better than the current literature.

## CONCLUSIONS

We recommend external fixation with Ilizarov method for shotgun induced fractures of the humerus and believe that it is a realistic method of skeletal stabilization in terms of open fractures. Provided that enough stability is maintained, this method promotes fracture healing, allows early rehabilitation and facilitates the achievement of a functional limb.

## REFERENCES

1. Brown TD, Michas P, Williams RE et al. The impact of gunshot wounds on an orthopaedic surgical service in an urban trauma center. *J Orthop Trauma* 1997; 3: 149-153.
2. Kocaoglu M, Tomak Y, Eralp L ve arkadaşları. Ilizarov yontemi ile humerus diafiz psodoartrozlarının tedavisi. *Acta Orthop Trauma Turcica* 2001; 35: 1-9 (medline'da aynı yazarların Treatment of humeral shaft non-unions by the Ilizarov method *Int Orthop*. 2001; 25 [6] 396-400
3. Simpson NS, Jupiter JB. Complex fracture patterns of the upper extremity. *Clin Orthop* 1995; 318: 43-53.
4. Soucacos PN, Beris AE, Xenakis TA, et al. Open type IIIB and IIIC fractures treated by an orthopaedic microsurgical team . *Clin Orthop* 1995; 314: 59-66.
5. Erler K, Solakoglu C, Başbozkurt M ve arkadaşları. Atesli silah yaralanmalarına bağlı dirsek bölgesi acık kırıklarındaki tedavi sonuçlarımız. *Acta Orthop Traumatol Turc* 1997; 31: 293-295.
6. Kocius M. External fixation in traumatology. In: Thorngren KG, Soucacos PN, Horan F, Scott J, eds. *European Instructional Course Lectures Vol 5*; London, British Editorial Society of Bone and Joint Surgery 2001: 35-45.
7. Murphy WM, Leu D . Fracture classification: biological significance. In : Rüedi TP , Murphy WM. *AO Principles of Fracture Management*. 4 th ed. Stuttgart: Georg Thieme Verlag 2000: 45-58.
8. Gustilo RB, Anderson JT. Prevention of infection in the treatment of one thousand and twenty-five open fractures of long bones: Retrospective and prospective analyses. *J Bone Joint Surg* 1976; 58A: 453-458.
9. Ilizarov GA. The apparatus: Components and biomechanical principles of application. In *Transosseous Osteosynthesis*. Berlin Heidelberg, Springer-Verlag, Berlin Heidelberg 1992: 63-137.
10. Gausepohl T, Koebke J, Pennig D et al. The anatomical base of unilateral external fixation in the upper limb. *Injury* 2000; 31, Suppl 1: 11-20.
11. Smith DK , Cooney WP. External fixation of high energy upper extremity injuries. *J Orthop Trauma* 1990; 4: 7-18.
12. Brettler D, Sedlin ED, Mendes G. Conservative treatment of low-velocity gunshot wounds. *Clin Orthop* 1979; 140: 26-31.
13. Hennessy MJ, Banks HH, Leach RB, et al. Extremity gunshot wound and gunshot fracture in civilian practice. *Clin Orthop* 1976; 114: 296-303.
14. Howland S, Ritchey SJ. Gunshot fractures in civilian practice. *J Bone Joint Surg* 1971; 53A: 47-55.
15. Dickson K, Watson TS, Haddad C et al. Outpatient management of low-velocity gunshot-induced fractures. *Orthopaedics* 2001; 24: 951-954.
16. Patzakis M, Harvey JP Ivler D. The role of antibiotics in the management of open fractures. *J Bone Joint Surg* 1974; 56A: 432-441.
17. Uzar Aİ, Dakak M, Öner K ve arkadaşları. Tabanca ve piyade tüfeği mermileri ile oluşturulan yumuşak doku ve kemik yaralanmalarının karşılaştırılması: Deneysel çalışma. *Acta Orthop Traumatol Turc* 2003; 37: 261-267.
18. Oestern HJ, Tscherner H. Pathophysiology and classification of soft tissue damage in fractures. *Orthopade* 1983; 12: 2-8.
19. Wiss DA, Gellman H. Gunshot wounds to the musculoskeletal system. In *Skeletal Trauma*. Vol 1, Philadelphia, Saunders 1992: 376-400.
20. Chapman MW, Mahoney M. The role of early internal fixation in the management of open fractures . *Clin Orthop* 1979; 138: 120-131.
21. Wild JJ, Hanson GW , Bennett JB, et al. External fixation use in the management of massive upper extremity trauma. *Clin Orthop* 1982; 164: 172-176.
22. Karatosun V , Alekberov C, Baran O, et al. Open fractures of the proximal humerus treated with the Ilizarov method. *Acta Orthop Scand* 2002; 73: 460-464.
23. Mostafavi HR, Tornetta P III. Open fractures of the humerus treated with external fixation. *Clin Orthop* 1997; 337: 187-197.
24. Wisniewski TF, Radziejowski MJ. Gunshot fractures of the humeral shaft treated with external fixation. *J Orthop Trauma* 1996; 4: 273-278.
25. Zinman C, Norman D, Hamoud K, et al. External fixation for severe open fractures of the humerus caused by missiles. *J Orthop Trauma* 1997; 7: 536-539.