

Necrotizing fasciitis of the scalp: a case of an uneventful healing

Saçlı derinin nekrotizan fasiiti: komplikasyonsuz bir iyileşme olgusu

Cenk ŞEN, Hakan AĞIR, Bahadır ÖZKESKİN, Deniz ÇEK

Necrotizing fasciitis is a rare, rapidly progressing soft tissue infection, characterised by extensive necrosis of subcutaneous fat and fascia with relative sparing of skin and underlying muscle. It is usually caused by toxin producing virulent bacteria. Although it can occur in otherwise healthy patients, the disease is usually seen in conjunction with immune deficiency disorders, intravenous drug abuse, peripheral vascular disease and diabetes. Necrotizing fasciitis is more frequent in abdominal wall, perineum and extremities. Involvement of the head and neck structures and especially the scalp is rare. We treated a diabetic and chronic renal failure patient with necrotizing fasciitis of the scalp without any complication.

Key Words: Necrotizing fasciitis, scalp

Nekrotizan fasiit cilt ve kas dokusu nisbeten korunacak şekilde, fasya ve ciltaltı yağ dokusunda yaygın nekrozla karakterize nadir görülen ve hızlı ilerleyen bir yumuşak doku enfeksiyonudur. Tabloya genellikle toksin üreten virulan bakteriler neden olur. Hastalık sağlıklı kişilerde de görülebilmesine rağmen, genellikle immün yetmezlik hastalıkları, intravenöz ilaç kötü kullanımını, periferik vasküler hastalıklar ve diyabetle ilişkili olarak da görülebilir. Nekrotizan fasiit karın duvarı, perine ve ekstremitelerde sık görülür. Baş-boyun ve özellikle de saçlı deriyi nadiren tutar. Diyabetik ve kronik böbrek yetersizlikli saçlı deride nekrotizan fasiiti olan bir hastayı herhangi bir komplikasyon olmaksızın tedavi ettik.

Anahtar Sözcükler: Nekrotizan fasiit, saçlı deri

INTRODUCTION

Necrotizing fasciitis is a severe and rapidly spreading soft tissue infection characterized by fascial suppuration, vascular thrombosis and serious systemic toxicity. Skin and muscle tissues are relatively spared in necrotizing fasciitis compared to fascial tissue. In the literature there has been a great variation in the terminology used for defining the cases of necrotizing fasciitis.^[1] It was first described by Hippocrates in the 5th century.^[2] But most authors credited Joseph Jones, a Confederate Army surgeon, as being the first who detailed the clinical picture of necrotizing fasciitis.^[2,3] The term necrotizing fasciitis was first used by Wilson in 1952.^[2]

Reported etiologies of soft tissue injury leading to necrotizing fasciitis include trauma, postoperative complications, cutaneous ulcers or wounds, drug injections, abscesses, and animal or insect bites.^[2] However in some studies, idiopathic causes were reported to be between 13 % and 31%. In addition to local factors, hematogenous spread of microorganisms from a distant infection site can be detected.^[2] Predisposing factors are alcoholism, parenteral drug abuse, malignancy, vasculitis, immunodeficiency and diabetes.^[1] There is no age or sex predilection since it could be encountered in young and healthy individuals^[2] If untreated, the condition carries a high risk of mortality ranging between 20 % and 60%.^[4,5]

Kocaeli Üniversitesi Tıp Fakültesi, Plastik ve Rekonstrüktif Cerrahi Anabilim Dalı, 41900 Derince, Kocaeli

Department of Plastic, Reconstructive and Aesthetic Surgery, Kocaeli University Medical School, 41900 Derince, Kocaeli

Bu çalışma, 18-20/Ekim/2002 tarihinde Ankara'da yapılan 24. Ulusal Türk Plastik, Rekonstrüktif ve Estetik Cerrahi Kongresinde poster olarak sunulmuştur.

Correspondance (İletişim): Dr. Cenk Şen, Kocaeli Üniversitesi Tıp Fakültesi, Plastik ve Rekonstrüktif Cerrahi A.D. 41900 Derince, Kocaeli
Telefon: 0 262 2335980-1399-1558 GSM: 0 532 2464339 e-posta: scenksen@yahoo.com

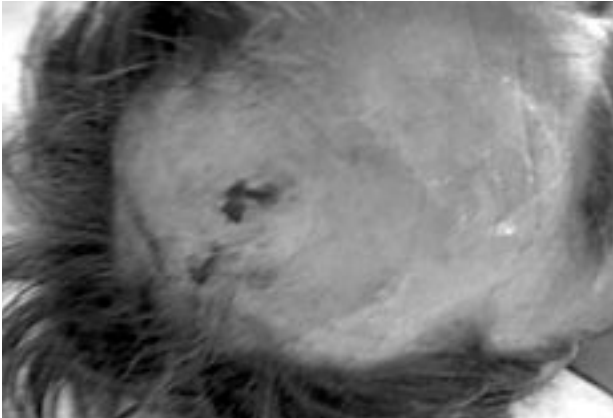


Figure 1: Preoperative view of the patient with swelling, erythema and drainage of purulent material.

CASE REPORT

A 48 year old man was referred to us from the dialysis unit with the complaints of pain, erythema and swelling of scalp and drainage of purulent material. He also had fever for the last 4 days. The patient has been followed by endocrinology and nephrology

departments with the diagnosis of diabetes mellitus and chronic renal failure. He has been under hemodialysis program for 5 years. Six days ago erythema appeared on the scalp followed by progressive swelling and drainage from a tiny spot 3 days later (Figure 1). He was under antibiotic treatment for the last 3 days. His general condition was poor. He was hypertensive. Laboratory tests revealed a high WBC count and low hemoglobin levels other than the findings of diabetes mellitus and chronic renal failure. After the initial evaluation we clinically diagnosed the patient as necrotizing fasciitis and urgently sent him to the operating room. After appropriate preparation, the scalp incisions were done. Scalp flaps were elevated. Purulent material were drained. All galeal tissue extending down to the fascia of temporal and frontal muscles and periosteum were necrotic. Temporal and frontal muscle fascia were also observed to be partially necrotic (Figure 2). After two extensive debridements during the treatment period, skin flaps were

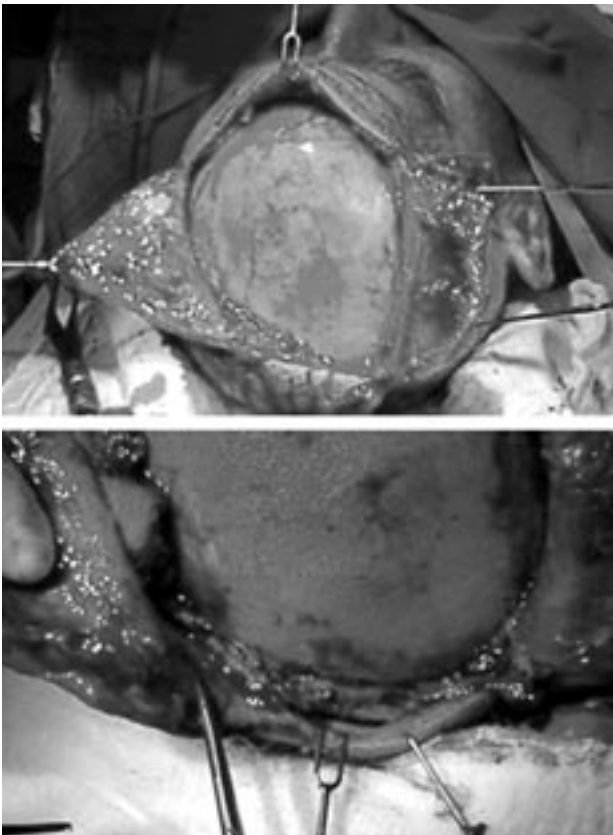


Figure 2: Intraoperative appearance with necrosis of galea, muscle fascia and periosteum.

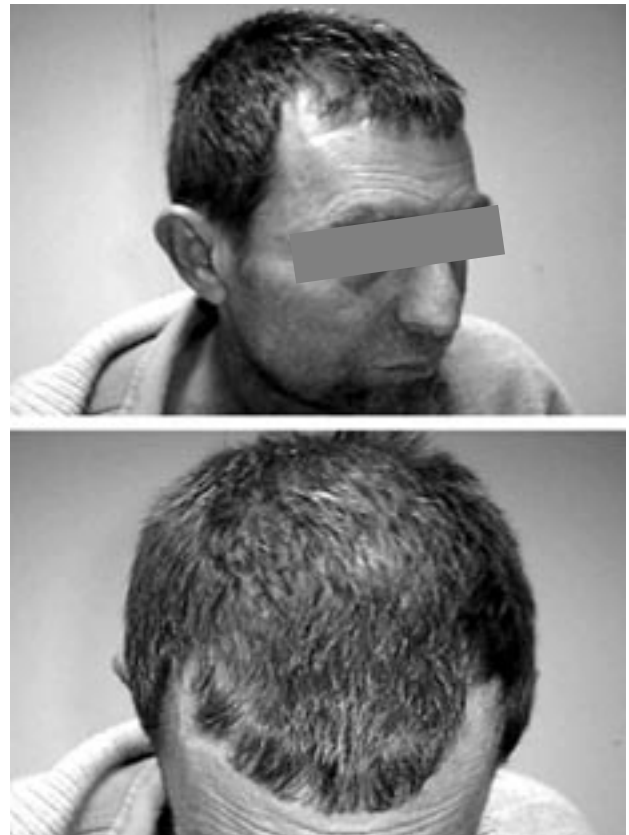

Figure 3: Appearance of the scalp at 6 months postoperatively.

brought together with minimal loss of skin. Drains were placed for irrigation. Parenteral antibiotics with broad spectrum were given. Culture results were negative due to a high dose of broad spectrum antibiotic use preoperatively. Frequent irrigation and antibiotic treatment resulted in the control of infection within 15 days. Skin flaps were stabilized and patient was discharged at 25. day postoperatively without any significant complication. All hair revived and elongated in 3 months (Figure 3).

DISCUSSION

Necrotizing fasciitis is caused by toxin producing virulent microorganisms. Although the number and type of the microorganism differ depending on the site of infection, Guillano et al divided the culture results into two groups.^[2] Type 1 is polymicrobial which involves non-group A *Streptococci* and anaerobes and/or facultative aerobes, often with *enterobacteriaceae*. In Type 2: the pathogen is group A β -hemolytic streptococci alone or in combination with staphylococcus. Polimicrobial necrotizing fasciitis is generally caused by enteric pathogens while monomicrobial ones are caused by microorganisms present in skin flora.

Clinical picture manifests itself with fever, systemic toxicity and local findings like pain, erythema and edema. Clinical picture of necrotizing fasciitis develops within 7 days of the inciting event. Within the first 36 hours the condition is obscure and mimics a simple soft tissue infection. But a rapid progression complicates the picture. The first sign is an erythematous, tender swollen, hot area of cellulitis accompanied by local pain and fever. Following this clinical picture skin darkens and blisters and bullae develop.^[6] During this time a liquefaction necrosis causes accumulation of purulent fluid.^[4] We operated our patient at this stage of purulent fluid accumulation and intervened the progression of the disease. Together with tissue destruction, inflammatory mediators and toxic substances rapidly place the patient into a septic state. Multiorgan failure, mental changes and hemodynamic lability dominate the picture. Leukocytosis or leukopenia can be seen later due to bone marrow suppression and sequestration of white blood cells in the spleen and lymphatic system.^[7] The condition must be differentiated from other skin and soft tissue infections like superficial

pyodermas, cellulitis and myonecrosis since the prognosis and treatment modalities are almost completely different.^[2] Imaging methods like plain radiographs, CT, MRI and ultrasonography are recommended to visualize the extent of infection, gas formation within soft tissue and fascial thickening.^[1,5,8,9] We unfortunately failed to demonstrate any evidence of soft tissue gas but some fascial changes have been observed in CT scan.

A delay in the diagnosis and treatment leads to a dramatic progression of the tissue damage. Therefore prompt diagnosis and early intervention greatly alter the outcome. Due to the paucity of skin findings in the early phases, the diagnosis is extremely difficult to make, and it relies mostly on the surgical findings such as lack of resistance of the normally adherent fascia during blunt dissection. Finger test is used to detect this resistance.^[3] During the emergent surgical procedure, the findings of extensive galeal and fascial necrosis, purulent collection, positive finger test and partial destruction of subcutaneous tissue with relative sparing of the skin in our patient strongly supported our first diagnosis of necrotizing fasciitis and led us to do an extensive debridement.

Prognosis of the patient depends on the prompt treatment with early surgical intervention, radical debridement, fasciotomy, fasciectomy and high dose of broad spectrum antibiotics.^[5-10] The mainstay of the treatment is the urgent surgical debridement. Hyperbaric oxygen therapy is also known to be effective for the treatment of necrotizing fasciitis.^[5-8] Repetitive debridements may be required depending on the condition of the patient as required twice in our patient. Final stage of operations is the reconstruction of the resulting defect with grafts or flaps which were not required in our patient. Skin flaps were all survived other than some small areas of necrosis around the incisions. Our success might be due to early intervention and high vascularity of the scalp flaps which were not affected at that stage by the disease process.

Although necrotizing fasciitis could be seen practically in any part of the body, generally abdominal wall, perineum and extremities are involved.^[2] Necrotizing fasciitis of the head and neck is very rare and usually seen in diabetic patients and chronic alcoholics.^[4] Cases with necrotizing fasciitis of

the head and neck can be separated into two groups according to the sites of their origin as scalp - periorbital region and face-neck fasciitis^[2] The reported cases were usually located on neck and rarely on face. The etiology of the periorbital involvement is usually trauma, surgery, eyelid infections or pruritus while blunt or penetrating trauma is the most common etiology of scalp involvement.^[1,11,12] There are reported cases of necrotizing fasciitis of the scalp in neonates due to infiltration of fluids within the subcutaneous tissue and some complications related to fetal scalp monitoring but it is a very rare localization for adults. Patients with scalp or periorbital involvement have monomicrobial infections particularly with streptococcus pyogenes and they lead a more benign course. Cervical necrotizing fasciitis usually results from progressive dental infections or pharyngeal in origin but insect bites, local traumas, burn and surgery are also encountered.

Scalp involvement is a rather rare occasion. Nallathambi in an extensive review of the literature showed that scalp involvement consisted only 14.4% of the cases with necrotizing fasciitis of head and neck region.^[13] Many cases were reported in infancy as a complication of fetal monitoring.^[14,15] Childers et al. reported that head and neck region were involved in 10% of the cases with 163 necrotizing fasciitis they treated for fourteen years and the annual incidence of NF for that period was 2.73 cases of NF per 10,000 hospital admissions.^[13] In a study examining 47 NF patients of the head and neck, Chen Lin *et al* reported 4% scalp involvement.^[4] Although the mortality is low in cases of necrotizing fasciitis of scalp the final reconstructive procedures usually lead to disfiguring results. In our patient we got an uneventful healing without any loss of skin which is not seen usually in most of the cases with necrotizing fasciitis of scalp where flap or graft reconstruction are required for resultant defects To get a satisfying result, high index of suspicion and urgent treatment are mandatory and to do this one must always bear in mind the probability of

scalp necrotizing fasciitis in order not to skip the diagnosis.

REFERENCES

1. Shindo ML, Nalbone VP, Dougherty WR. Necrotizing fasciitis of the face. *Laryngoscope*. 1997; 107: 1071-9.
2. Green RJ, Dafoe DC, Raffin TA. Necrotizing fasciitis. *Chest*. 1996; 110(1): 219-29.
3. Childers BJ, Potyondy LD, Nachreiner R et al. Necrotizing fasciitis: A fourteen year retrospective study of 163 consecutive patients. *Am Surg*. 2002; 68: 109-16.
4. Lin C, Yeh FL, Lin JT et al. Necrotizing fasciitis of the head and neck: An analysis of 47 cases. *Plast Reconstr Surg*. 2001; 107(7): 1684-93.
5. Bahu SJ, Shibuya TY, Meleca RJ et al. Craniocervical necrotizing fasciitis: An 11-year experience. *Otolaryngol Head and Neck Surg*. 2001; 125(3): 245-52.
6. Williams SR, Carruth JAS, Brightwell AP. Necrotizing fasciitis of the face without significant trauma. *Clin Otolaryngol*. 1992; 17: 344-50.
7. Chattar-Cora D, Tulsyan N, Cudjoe EA et al. Necrotizing fasciitis of the head and neck: A report of two patients and review. *Head Neck*. 2002; 24(5): 497-501.
8. Sepulveda A, Sastre N. Necrotizing fasciitis of the face and neck. *Plast Reconstr Surg*. 1998; 102(3): 814-7.
9. Becker M, Zbaren P, Hermans R et al. Necrotizing fasciitis of the head and neck: Role of CT in diagnosis and management. *Radiology*. 1997; 202: 471-6.
10. Elliot D, Kufera JA, Myers RAM. The microbiology of necrotizing soft tissue infections. *Am J Surg*. 2000; 179: 361-6.
11. Ray AM, Bressler K, Davis RE et al. Cervicofacial necrotizing fasciitis. *Arch Otolaryngol Head Neck Surg*. 1997; 123: 633-6.
12. Suner IJ, Meldrum ML, Johnson TE et al. Necrotizing fasciitis after cosmetic blepharoplasty. *Am J Ophthalmol*. 1999; 128(3): 367-8.
13. Nallathambi MN, Ivatury RR, Rohman M et al. Craniofacial necrotizing fasciitis: Critical factors in management. *Can J Surg*. 1987; 30(1): 61-3.
14. Ameh EA, Mamuda AA, Musa HH et al. Necrotizing fasciitis of the scalp in a neonate. *Ann Trop Paediatr*. 2001; 21: 91-3.
15. Siddiqi SF, Taylor PM. Necrotizing fasciitis of the scalp. *Am J Dis Child*. 1982; 136: 226-8.