

Renal artery occlusion in the late postoperative period managed with renal artery stenting after endovascular abdominal aortic aneurysm repair and renal function salvage

Abdominal aort anevrizması tamiri sonrası geç dönemde renal arter tıkanması ve stent ile böbrek fonksiyonlarının kurtarılması

Mustafa Serkan Karakaş, M.D.,¹ Necmettin Korucuk, M.D.,¹ Cemal Kemalöglü, M.D.,²
Refik Emre Altekin, M.D.,¹ İbrahim Demir, M.D.¹

¹Department of Cardiology, Akdeniz University Faculty of Medicine, Antalya, Turkey

²Department of Cardiovascular Surgery, Akdeniz University Faculty of Medicine, Antalya, Turkey

Summary– Endovascular aneurysm repair (EVAR) of abdominal aorta is a valuable treatment option in selected patients with abdominal aortic aneurysm. Renal artery occlusion is a serious complication after EVAR and may progress to permanent renal injury requiring hemodialysis. In this report, case of unexpected renal artery occlusion after EVAR treated with renal artery stenting in the late postoperative period is described.

Endovascular aneurysm repair (EVAR) of abdominal aorta is a valuable treatment option in selected patients with abdominal aortic aneurysm (AAA) that was introduced into clinical practice in 1991 by Parodi et al.^[1] EVAR provides a less invasive alternative to open AAA repair and is associated with lower perioperative mortality and morbidity rates than open surgical aneurysm repair.^[2] However, renal artery occlusion remains a serious complication after EVAR and may progress to permanent renal injury requiring hemodialysis.^[3] Renal artery occlusion can occur through various mechanisms. The most common cause is perioperative deployment of the aortic stent graft such that it covers one or both renal arteries. It may also develop with intraoperative rupture and embolization of cholesterol plaques.^[2]

Renal artery occlusion due to overstenting is typically recognized and treated immediately. In this re-

Özet– Endovasküler abdominal aort anevrizma tamiri (EVAR), abdominal aort anevrizması bulunan seçilmiş hastaların tedavisinde önemli bir tedavi seçeneğidir. Renal arter tıkanması EVAR sonrası gelişebilen ciddi bir komplikasyondur ve hemodiyaliz gerektiren kalıcı böbrek hasarına kadar ilerleyebilir. Bu yazıda, EVAR sonrası beklenmeyen renal arter tıkanması gelişen ve işlem sonrası geç dönemde renal artere stent yerleştirilerek tedavi edilen bir olgu sunuldu.

port, case of unexpected renal artery occlusion managed with renal artery stenting in the postoperative course is presented.

Abbreviations:

AAA	Abdominal aortic aneurysm
EVAR	Endovascular aneurysm repair
DMSA	Dimercaptosuccinic acid
GFR	Glomerular filtration rate
LIMA	Left internal mammary artery

CASE REPORT

A 72-year-old male had been referred to vascular surgery department for assessment of infrarenal AAA. In the operating room, bifurcated stent graft (AFX; Endologix, Inc., Irvine, CA, USA) had been implanted in the patient through conventional bilateral groin cut-down under general anesthesia. The patient had been transferred to intensive care unit with stable blood pressure and heart rate. Acetyl salicylic acid, clopidogrel, and subcutaneous enoxaparin treatment had been administered. The patient's urine output

Received: June 06, 2016 Accepted: December 28, 2016

Correspondence: Dr. Mustafa Serkan Karakaş. Akdeniz Üniversitesi Tıp Fakültesi, Kardiyoloji Anabilim Dalı, 07100 Antalya, Turkey.

Tel: +90 242 - 249 67 75 e-mail: mserkan19@hotmail.com

© 2017 Turkish Society of Cardiology



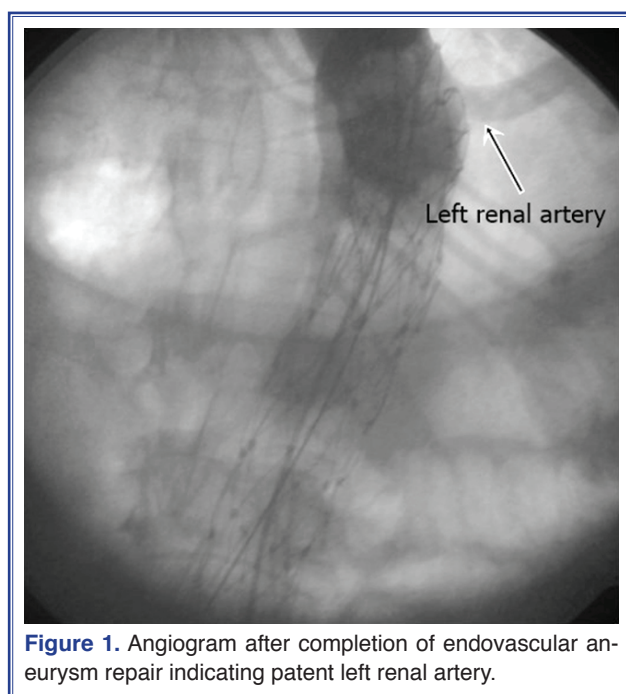


Figure 1. Angiogram after completion of endovascular aneurysm repair indicating patent left renal artery.

had been monitored for 12 hours, and progressive reduction in urine output had been observed. Cardiac surgeons suspected renal artery occlusion and renal angiography was suggested. There was hypertension and obesity in medical history of the patient. He also had congenital solitary kidney: left kidney was patent and right kidney was absent. Analysis of laboratory values indicated preoperative serum creatinine value of 1.36 mg/dL and estimated glomerular filtration rate (GFR) of 54 mL/dk/1.73m². Postoperative 12th hour

serum creatinine value was 2.72 mg/dL and estimated GFR was 22 mL/dk/1.73m². Post-EVAR angiogram revealed well-excluded AAA by the aortic endograft without evidence of proximal or distal endoleak, as well as visualization of the left renal artery (Figure 1). Angiography was performed immediately thereafter with suspicion of thrombotic occlusion of the renal artery, and ostial occlusion of the left renal artery was observed (Figure 2a).

Location of the left renal artery shown on EVAR completion angiogram was used to estimate position of the left renal artery orifice. Left renal artery was cannulated using 6F left internal mammarian artery (LIMA) catheter (Alvimedica Tıbbi Ürünler San. ve Dış Tic. A.Ş., Istanbul, Turkey). Tip of LIMA catheter was placed at the origin of the left renal ostium and an angled 0.018 Thruway guidewire (Boston Scientific Corp., Marlborough, MA, USA) was manipulated toward the ostium. After balloon dilatation with 4.5x20 mm Turquoise balloon catheter (Alvimedica Tıbbi Ürünler San. ve Dış Tic. A.Ş., Istanbul, Turkey), 6.5-15 mm Hippocampus renal stent (Medtronic, Inc., Minneapolis, MN, USA) was deployed across the obstructed renal ostium and renal artery flow was provided (Figure 2b). After renal stent placement, aspirin 100 mg daily and clopidogrel 75 mg daily therapy was initiated. The patient was transferred back to intensive care unit.

The patient's creatinine value continued to increase to 4.69 mg/dL (estimated GFR was 11.6 mL/

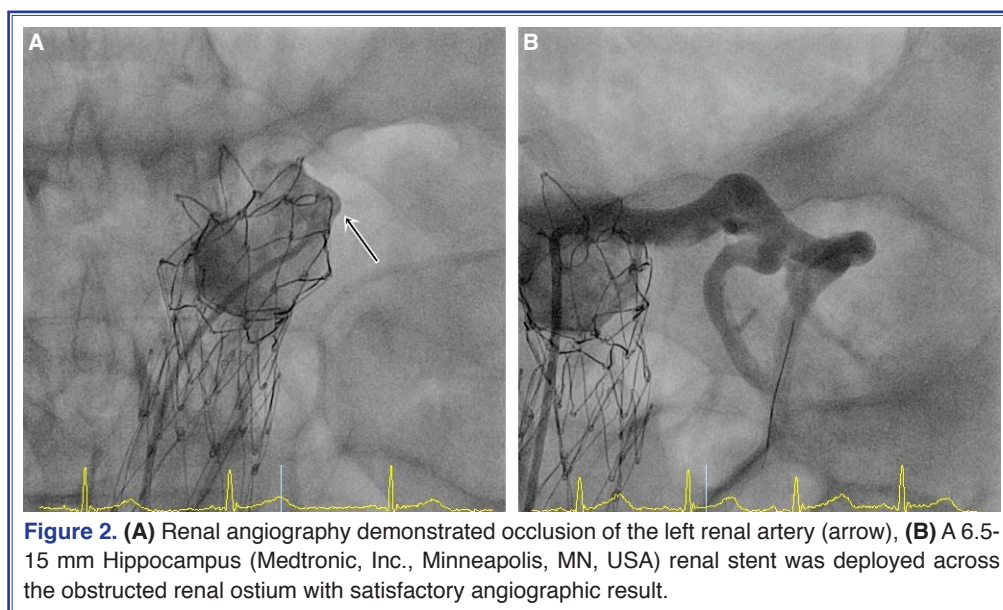


Figure 2. (A) Renal angiography demonstrated occlusion of the left renal artery (arrow), (B) A 6.5-15 mm Hippocampus (Medtronic, Inc., Minneapolis, MN, USA) renal stent was deployed across the obstructed renal ostium with satisfactory angiographic result.

dk/1.73m²) and there was no urine output 24 hours after revascularization. The patient required hemodialysis to correct metabolic acidosis. Renal dimercaptosuccinic acid (DMSA) scintigraphy showed diffuse decreased DMSA uptake in left kidney. Hemodialysis was continued 3 days a week for 4 weeks. His serum creatinine value returned to baseline value of 1.8 mg/dL (estimated GFR was 35 mL/dk/1.73m²) after effective hemodialysis. He had a remarkable recovery with increased urine output. He was discharged without need for hemodialysis. At the first month follow-up visit, the patient continued to do well. His serum creatinine value had decreased to 1.5 mg/dL (estimated GFR was 48 mL/dk/1.73m²), he did not require hemodialysis, and blood pressure was stable.

DISCUSSION

Several clinical studies have demonstrated that EVAR can be achieved with exceptional technical success.^[3] Initially, EVAR was performed for patients with abdominal AAA who were at high risk for traditional open aneurysm repair. With the development of aortic endovascular devices, procedure has begun to be used in patients eligible for open repair.^[2,3] However, as with all innovative techniques, EVAR is associated with several complications, such as migration of endovascular stent graft; endoleak; graft limb complications, including kinking, stenosis or thrombosis of the stent graft limbs; and renal artery occlusion.^[2]

Unintended renal artery occlusion remains a severe complication related to stent graft deployment.^[4] Renal artery occlusion after EVAR can occur through 3 main mechanisms. The most common cause is aortic stent graft covering one or both of the renal arteries. Aneurysm with short neck may be high-risk indicator for this complication. It has been reported that renal artery occlusion rate was between 2% to 4% upon initial stent graft deployment.^[2,4,5] In a series of 204 patients, Kalliafas et al. observed bilateral renal artery occlusion in 1 patient and unilateral renal artery occlusion in another 4 patients (2.4%).^[6] Similarly, in a study conducted by Stelter et al., 5 cases (2.5%) of renal artery occlusion were encountered, and graft was removed after 3 weeks in 1 patient.^[7] In another study, Görich et al. observed that stent graft covered 1 renal artery in 2 of 55 patients.^[8] The second mechanism of renal artery occlusion is intraoperative rupture and embolization of cholesterol plaques.^[2] This complica-

tion was reported at rate of 3.3% in the series reported by Hausegger et al. In this study, renal artery occlusion by atheromatous material was observed in 3 of 55 patients.^[5] Renal artery occlusion or stenosis can also occur due to remodeling of an irregular aneurysmal neck during stent graft deployment.^[2,5] In our patient, the renal artery was observed to be open in completion angiography after stent graft insertion. As result of progressive reduction in urine output and increase in serum creatinine level 6 hours later, we performed renal angiography and found that the renal artery was occluded. It was thought that occlusion was likely caused by atherothrombotic material. Renal artery thrombosis can be caused by partial obstruction after stent graft deployment that can be difficult to identify on intraoperative angiography. Delayed onset of renal artery thrombosis may be related to invisible filling defect in the renal artery profile, and even when the stent graft covers much of the orifice, lumen of the renal artery often fills with contrast-enhanced blood. Additionally, partial renal artery obstruction caused by the struts of the suprarenal hooks or the stent graft material may be masked by intraoperative anticoagulation.

Renal artery occlusion associated with EVAR remains an uncommon complication, and is typically found and treated intraoperatively within 30 minutes. If this is not possible, due to limited warm ischemic time of kidney, damage may occur.^[2,5] Renal artery occlusion due to stent graft maldeployment can be treated with “pull-down” method. Renal artery stenosis caused by plaque embolization may be treated by aspiration of the plaque. Stent graft covering renal artery after placement or due to chronic alteration of aneurysm geometry can be treated with implantation of bare stent into the renal artery.^[2] It may also be recognized in follow-up period. Prolonged renal artery occlusion and strategy for operative treatment are not well documented.^[9,10] This uncommon and serious complication may be treated with both open and endovascular techniques.^[9] In our case, renal artery occlusion was treated by implanting bare metal stent into the renal artery. Similarly, Hedayati et al. and Franchin et al. reported cases of renal artery occlusion treated with renal artery stenting in follow-up period. They also reported that renal salvage was achieved after renal artery stenting, despite prolonged ischemia time.^[9,10]

In conclusion, since warm ischemic time of the kidney is limited, revascularization of an occluded renal artery should be achieved as soon as possible, either endoluminally or surgically. We have demonstrated that salvage of renal function is possible even after prolonged ischemic time following EVAR. Renal artery stenting is an effective option to improve renal perfusion and may be considered a viable alternative to open surgical bypass for patients with renal artery occlusion after EVAR-related delayed onset of renal artery thrombosis.

Conflict-of-interest issues regarding the authorship or article: None declared.

REFERENCES

1. Parodi JC, Palmaz JC, Barone HD. Transfemoral intraluminal graft implantation for abdominal aortic aneurysms. *Ann Vasc Surg* 1991;5:491–9. [\[CrossRef\]](#)
2. Grande W, Stavropoulos SW. Treatment of complications following endovascular repair of abdominal aortic aneurysms. *Semin Intervent Radiol* 2006;23:156–64. [\[CrossRef\]](#)
3. Lin PH, Bush RL, Lumsden AB. Endovascular rescue of a maldeployed aortic stent-graft causing renal artery occlusion: technical considerations. *Vasc Endovascular Surg* 2004;38:69–73. [\[CrossRef\]](#)
4. Lalka S, Johnson M, Namyslowski J, Dalsing M, Cikrit D, Sawchuk A, et al. Renal interventions after abdominal aortic aneurysm repair using an aortic endograft with suprarenal fixation. *Am J Surg* 2006;192:577–82. [\[CrossRef\]](#)
5. Hausegger KA, Schedlbauer P, Deutschmann HA, Tiesenhausen K. Complications in endoluminal repair of abdominal aortic aneurysms. *Eur J Radiol* 2001;39:22–33. [\[CrossRef\]](#)
6. Kalliafas S, Albertini JN, Macierewicz J, Yusuf SW, Whitaker SC, Macsweeney ST, et al. Incidence and treatment of intraoperative technical problems during endovascular repair of complex abdominal aortic aneurysms. *J Vasc Surg* 2000;31:1185–92. [\[CrossRef\]](#)
7. Stelter W, Umscheid T, Ziegler P. Three-year experience with modular stent-graft devices for endovascular AAA treatment. *J Endovasc Surg* 1997;4:362–9. [\[CrossRef\]](#)
8. Görlich J, Rilinger N, Söldner J, Kramer S, Orend KH, Schütz A, et al. Endovascular repair of aortic aneurysms: Treatment of complications. *J Endovasc Surg* 1999;6:36–146. [\[CrossRef\]](#)
9. Franchin M, Fontana F, Piacentino F, Tozzi M, Piffaretti G. Postoperative “Chimney” for Unintentional Renal Artery Occlusion after EVAR. *Case Rep Vasc Med* 2014;2014:170198.
10. Hedayati N, Lin PH, Lumsden AB, Zhou W. Prolonged renal artery occlusion after endovascular aneurysm repair: endovascular rescue and renal function salvage. *J Vasc Surg* 2008;47:446–9. [\[CrossRef\]](#)

Keywords: Endovascular abdominal aortic aneurysm repair; renal artery occlusion; renal artery stenting.

Anahtar sözcükler: Endovasküler abdominal aort anevrizma tamiri; renal arter oklüzyonu; renal arter stentlemesi.