

Obstruction of superior vena cava flow during transcatheter atrial septal defect closure with the Atriasept ASD occluder

Atriasept ASD kapatma cihazı ile atriyal septal defektin transkateter kapatılması sırasında süperiyor vena kava akımının tıkanması

Nihan Kahya Eren, M.D., Uğur Kocabaş, M.D., Cem Nazlı, M.D., Oktay Ergene, M.D.

Department of Cardiology, Izmir Atatürk Training and Research Hospital, Izmir

Summary– In this paper, we describe a patient with a large secundum atrial septal defect ASD (26 mm) with adequate rims that were suitable for percutaneous closure. While closing this ASD, the superior vena cava (SVC) was occluded with the right atrial disc of the Atriasept ASD occluder (Cardia) and thus the device was retrieved before its release. After retrieval of this device, an Amplatzer ASD occluder was successfully implanted without disturbing the caval flow.

Percutaneous closure of secundum atrial septal defects (ASD) has become a good alternative to surgical repair. Since 1976, different devices have been developed and implanted for the percutaneous closure of ASDs.^[1-3] The closure of large defects is challenging and has more complications. In this paper, we describe a patient with a large secundum ASD (26 mm) with adequate rims that were suitable for percutaneous closure. While closing this ASD, the superior vena cava (SVC) was occluded with the right atrial disc of the Atriasept ASD occluder (Cardia) and thus the device was retrieved before its release. After retrieval of this device, an Amplatzer ASD occluder was successfully implanted without disturbing the caval flow.

CASE REPORT

A 25-year-old female patient with a large secundum ASD (26 mm) with adequate rims was admitted for transcatheter closure. When the ASD was stretched with the sizing balloon, the diameter of the defect was 26 mm and the 28 mm Atriasept ASD occluder (Cardia) was chosen for closure. The Atriasept ASD oc-

Özet– Bu yazıda, perkütan kapatma için yeterli rimleri (kenarları) olan geniş sekundum tipi atriyal septal defekti (ASD) (26 mm) bulunan hastada, işlem sırasında süperiyor vena kava akımının Atriasept ASD tıkayıcısının sağ atriyal diski ile tıkanıldığı ve bunun üzerine cihazın geri çekildiği olgu sunuldu. Bu cihazın geri çekilmesinden sonra aynı seansta Amplatzer ASD tıkayıcı cihazı vena kava akımını bozmadan yerleştirilmiştir.

cluder is a double umbrella device with left and right-sided nitinol struts and two polyvinyl alcohol discs.^[4] It is fully retrievable and has a self-centering design.^[5] Using standard techniques, the device was inserted and deployed under fluoroscopic and transesophageal echocardiogram (TEE) guidance (Fig. 1a, Video 1*). Prior to the final release of the device, TEE imaging at the bicaval plane demonstrated occlusion of the SVC orifice with the right atrial disc of the device (Fig. 1b, Video 2*). After visualization of the obstruction of SVC flow using color Doppler (Video 3*), the device was retrieved and removed. Transesophageal echocardiographic examination revealed that the caval rims were >5 mm and the defect still seemed to be suitable for percutaneous closure. Based on these observations, we postulated that the technical properties of the Atriasept ASD occluder were unsuitable for this defect and a second attempt was immediately made to close the defect with the Amplatzer ASD oc-

Abbreviations:

ASD	Atrial septal defects
TEE	Transesophageal echocardiogram
SVC	Superior vena cava
ASO	Amplatzer ASD occluder

Received: March 19, 2012 Accepted: June 22, 2012

Correspondence: Dr. Nihan Kahya Eren. İnönü Caddesi, No: 252/17, Hatay, Konak, İzmir.

Tel: +90 266 - 244 44 44 / 2552 e-mail: nkahya77@yahoo.com

© 2013 Turkish Society of Cardiology



cluder (ASO). Successful closure was achieved with a 28 mm Amplatzer ASD occluder without any residual shunt and without disruption of the caval blood flow (Fig. 1c, d). The patient was discharged on aspirin and clopidogrel.

DISCUSSION

Transcatheter closure of ASDs is a safe alternative to surgery, especially for small and medium size defects.^[6] However, closure of large defects is still challenging with more peri- and post-procedural complications.^[7] Most of the available devices other than the ASO

are not appropriate for the closure of large ASDs. The Amplatzer septal occluder has a unique self-centering design and requires less atrial septal tissue around the ASD in order to be adequately stabilized. Several reports have demonstrated that in selected patients, transcatheter closure of large secundum ASDs with the ASO is feasible with an acceptable failure and complication rate.^[7,8]

A recent multicenter study has tested the efficacy and safety of the new Atriasept ASD occluder for secundum ASD closure.^[5] A 90% clinical success rate was achieved (71 out of 79 patients) with low morbid-

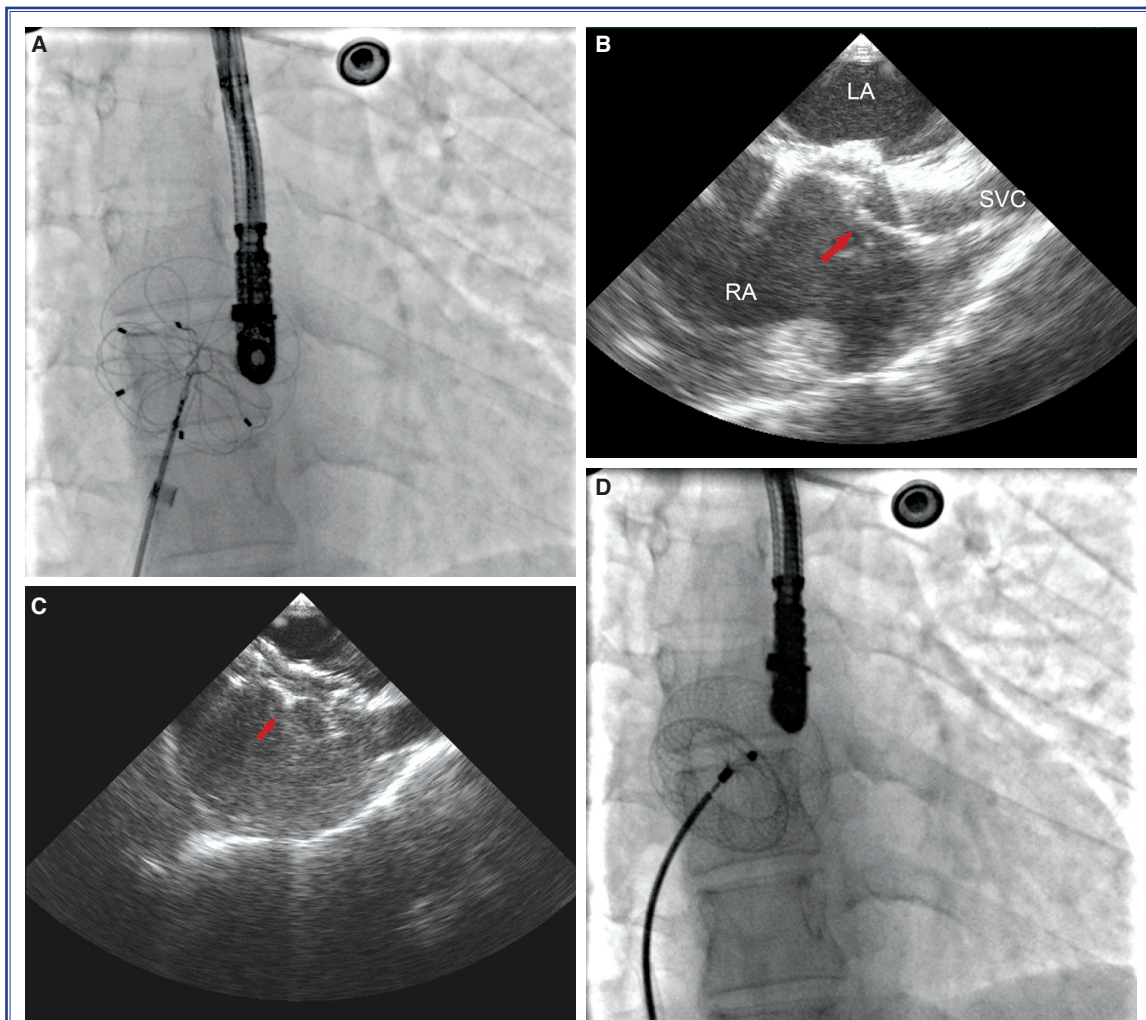


Figure 1. (A) Angiographic image demonstrating the Atriasept ASD occluder device after deployment of the right and the left atrial discs. (B) Transesophageal echocardiogram recorded at the bicaval plane revealing occlusion of the superior vena cava ostium with the right atrial disc (arrow) of the Atriasept ASD occluder. (C) Transesophageal echocardiogram recorded at the bicaval plane demonstrating the Amplatzer ASD occluder device (arrow) before its release from the delivery catheter and showing that the device is not obstructing the inferior or superior vena cava. (D) Angiographic image showing the Amplatzer ASD occluder before its release from the delivery catheter. LA: Left atrium; SVC: Superior vena cava; RA: Right atrium.

ity and no mortality. Of the reported patients, 10 had a large ASD (>20 mm) which was closed successfully with the Atrisept ASD occluder.

In our case, a 28 mm Atrisept ASD occluder initially seemed to be successfully deployed within the defect. However, intraprocedural TEE revealed that the SVC ostium was occluded by the device just before its release. Following this complication, the same defect was successfully closed with an ASO without any complications. It is possible that the ASO was more successful in this case due to the better self-centering centering design of the ASO. Unlike the ASO device, the Atrisept device may be more affected by the static forces of the surrounding septal tissue which may make the device more prone to distortion and displacement. In our case, the device may have occluded the superior caval orifice because of the relatively loose superior caval rim compared to the stiffer contralateral surrounding septal tissue.

Partial occlusion of the superior or inferior vena cava after percutaneous ASD closure has been previously reported.^[9,10] In our case the occlusion of the SVC was recognized before releasing the device and the device was retrieved. Intraprocedural TEE plays an important role in the visualization of the device position, efficacy and relationship to the adjacent cardiac structures.

Percutaneous closure of large secundum ASDs is challenging with more peri- and post-procedural complications. Intraprocedural TEE is a complementary and necessary imaging modality in addition to fluoroscopy during percutaneous ASD closure.

Conflict-of-interest issues regarding the authorship or article: None declared.

***Supplementary video files associated with this article can be found in the online version of the journal.**

REFERENCES

1. Butera G, Carminati M, Chessa M, Delogu A, Drago M, Pia-

za L, et al. CardioSEAL/STARflex versus Amplatzer devices for percutaneous closure of small to moderate (up to 18 mm) atrial septal defects. *Am Heart J* 2004;148:507-10.

2. Post MC, Suttorp MJ, Jaarsma W, Plokker HW. Comparison of outcome and complications using different types of devices for percutaneous closure of a secundum atrial septal defect in adults: a single-center experience. *Catheter Cardiovasc Interv* 2006;67:438-43.
3. Ebeid MR. Percutaneous catheter closure of secundum atrial septal defects: a review. *J Invasive Cardiol* 2002;14:25-31.
4. Brown S, Gewillig M. Perforation of the aortic sinus after closure of atrial septal defects with the Atrisept occluder. *Catheter Cardiovasc Interv* 2009;74:298-301.
5. Stolt VS, Chessa M, Aubry P, Juliard JM, Schraeder R, Berger A, Goy JJ. Closure of ostium secundum atrial septum defect with the Atrisept occluder: early European experience. *Catheter Cardiovasc Interv* 2010;75:1091-5.
6. Du ZD, Hijazi ZM, Kleinman CS, Silverman NH, Larntz K; Amplatzer Investigators. Comparison between transcatheter and surgical closure of secundum atrial septal defect in children and adults: results of a multicenter nonrandomized trial. *J Am Coll Cardiol* 2002;39:1836-44.
7. Losay J, Petit J, Lambert V, Esna G, Berthaux X, Brenot P, et al. Percutaneous closure with Amplatzer device is a safe and efficient alternative to surgery in adults with large atrial septal defects. *Am Heart J* 2001;142:544-8.
8. Kannan BR, Francis E, Sivakumar K, Anil SR, Kumar RK. Transcatheter closure of very large (>or= 25 mm) atrial septal defects using the Amplatzer septal occluder. *Catheter Cardiovasc Interv* 2003;59:522-7.
9. Soo AW, Healy DG, Walsh K, Wood F. Inferior vena cava and coronary sinus obstruction after percutaneous atrial septal defect device closure requiring surgical revision. *J Thorac Cardiovasc Surg* 2006;131:1405-6.
10. Preventza O, Sampath-Kumar S, Wasnick J, Gold JP. Late cardiac perforation following transcatheter atrial septal defect closure. *Ann Thorac Surg* 2004;77:1435-7.

Key words: Cardiac catheterization/methods; embolization, therapeutic/instrumentation; equipment design; heart diseases; heart septal defects, atrial/surgery.

Anahtar sözcükler: Kalp kateterizasyonu/yöntem; embolizasyon, terapötik / enstrümantasyon; ekipman tasarımı; kalp hastalıkları; kalp septal defektleri, atriyal/cerrahi.