

## CASE IMAGE

**Diagnosis of a rare combination of hypertrophic and left ventricular noncompaction cardiomyopathy using cardiac magnetic resonance imaging*****Nadir bir birliktelik olan hipertrofik kardiyomiyopati ve nonkompaksiyon kardiyomiyopatisinin kardiyak manyetik rezonans görüntüleme ile tanısı***

Sinem Özyılmaz

Özgür Akgül

Adem Kiriş#

Aydın Yıldırım

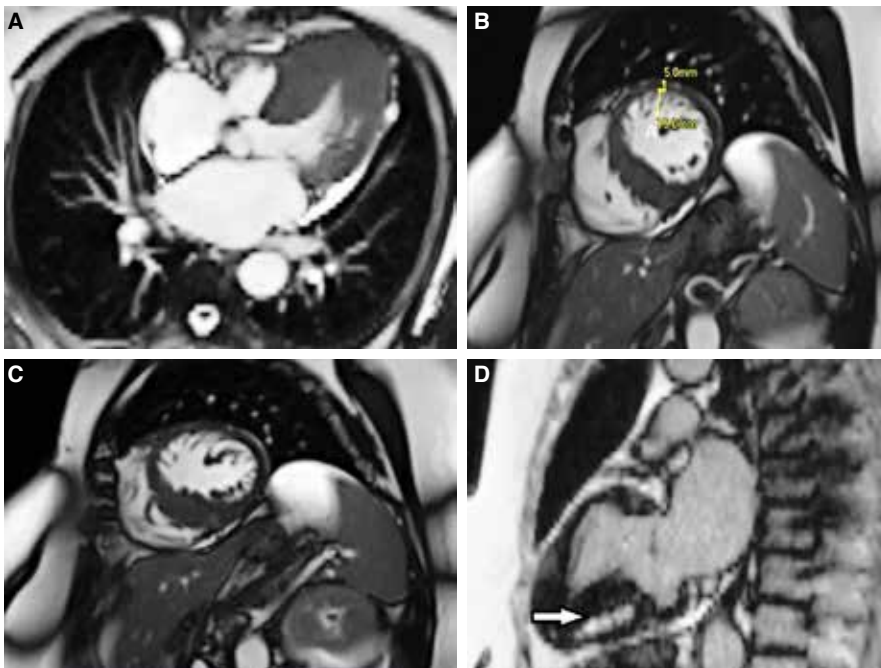
İhsan Bakır\*

Department of Cardiology,  
Mehmet Akif Ersoy Thoracic  
and Cardiovascular Surgery  
Center, Training and Research  
Hospital, İstanbul, Turkey

#Department of Radiology,  
Mehmet Akif Ersoy Thoracic  
and Cardiovascular Surgery  
Center, Training and Research  
Hospital, İstanbul, Turkey

\*Department of Cardiovascular  
Surgery, Mehmet Akif Ersoy  
Thoracic and Cardiovascular  
Surgery Center, Training  
and Research Hospital,  
İstanbul, Turkey

Hypertrophic cardiomyopathy (HCM) is the most common form of cardiomyopathy, while left ventricular noncompaction (LVNC) is uncommon. Genetic evidence has recently been documented, confirming that LVNC and HCM have overlapping causative genes. A 62-year-old woman with systolic ejection murmur was referred for further examination. She had no family history of heart disease or additional diseases. Two-dimensional transthoracic echocardiography revealed septal hypertrophy with a maximum wall thickness of 21 mm, but no highly trabeculated myocardium was detected in the left ventricle. Cine and contrast-enhanced cardiovascular magnetic resonance imaging (CMRI), performed to characterize the cardiac morphology, confirmed the presence of septal hypertrophy, with prominent trabeculations (i.e., noncompacted myocardium) noted in the apex and left ventricular lateral wall (Figure A, Video 1\*). Maximum end-diastolic ratio of noncompacted to compacted myocardial wall thickness was 3, consistent with a diagnosis of LVNC (Figure B, C; Video 2\*). In addition, contrast-enhanced CMRI demonstrated multiple areas of delayed enhancement with predominant involvement of the basal anterior septum and posterior wall, consistent with myocardial fibrosis (Figure D). Echocardiography cannot always provide an optimal image, and may be insufficient for diagnosing comorbid diseases. In these cases, diagnosis may often be overlooked or delayed. An awareness among cardiologists of the coexistence of these diseases would aid in identification and prevent misdiagnosis. CMRI is an important diagnostic tool, and should be more widely used, particularly in patients with HCM.



**Figures–** (A) Presence of left ventricular hypertrophy in the basal anterior and posterior septums. (B) End-diastolic ratio of noncompacted to compacted myocardial wall thickness was 3. (C) Presence of prominent trabeculations (i.e., noncompacted myocardium) in the apex and left ventricular lateral walls. (D) Area of delayed enhancement in the basal anterior septum and posterior wall, consistent with myocardial fibrosis. \*Supplementary video files associated with this presentation can be found in the online version of the journal.