

Multiple cardiac myxomas originating in mitral apparatus

Mitral yapılardan köken alan birden fazla kalp miksoması

Hakan Erkan

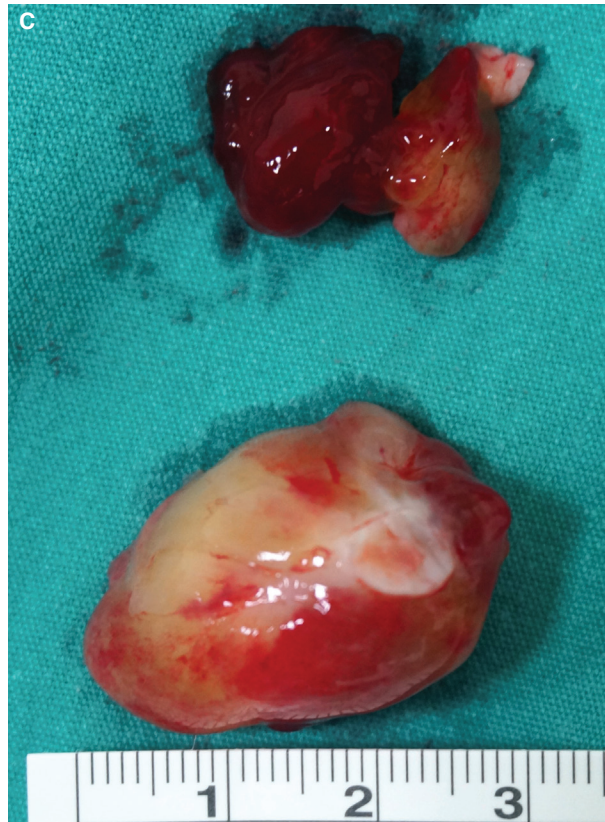
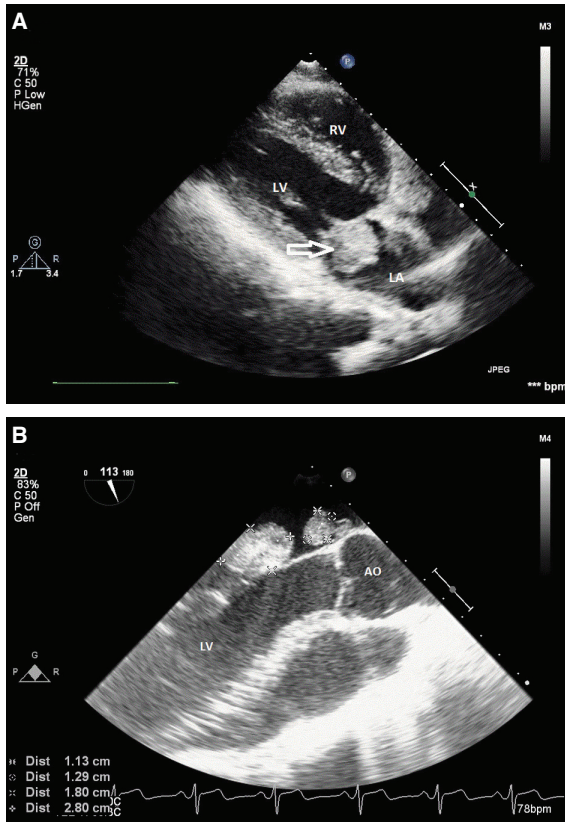
Gülhanım Kırış

Gülay Uzun Hekimoğlu

Department of Cardiology,
Ahi Evren Thoracic and
Cardiovascular Surgery
Training and Research
Hospital, Trabzon

A 20-year-old male patient was admitted to our hospital for intermittent attacks of shortness of breath and palpitations. He and his family had no notable cardiac disease in their medical history. There was no remarkable finding on his physical examination. An electrocardiogram revealed a normal sinus rhythm without abnormalities. Transthoracic echocardiography (TTE) showed normal left ventricular function and a mobile left atrial mass arising out of the anterior mitral leaflet (Figure A). Then, transesophageal echocardiography (TEE) revealed two different well-circumscribed masses origi-

nating in the mitral anterior leaflet (2.8x1.8 cm) and mitral annulus (1.2x1.1 cm) (Figure B, Video 1*). Careful examination of all cardiac chambers by TEE revealed no additional mass in the heart. The patient was examined for pigmented skin lesions, testes tumors, adrenal cortical disease and cutaneous myxomas. No findings were detected to support a diagnosis of Carney syndrome. Surgery confirmed the echocardiographic findings and the masses were excised (Figure C). The diagnosis of cardiac myxoma was confirmed by pathological evaluation. The patient was discharged on the seventh postoperative day without complications. Cardiac myxomas usually originate in the interatrial septum and those originating in the mitral apparatus are extremely rare. In this report, we present multiple myxomas arising from the mitral apparatus.



Figures– (A) Transthoracic echocardiography showing left atrial myxoma (arrow) arising from anterior mitral leaflet. **(B)** Transesophageal echocardiography demonstrating two different masses originating in mitral anterior leaflet and mitral annulus. **(C)** Myxomas in post-operative period. *Supplementary video file associated with this presentation can be found in the online version of the journal.