

Disproportionate right heart enlargement in a patient with small atrial septal defect: Hidden abnormal pulmonary venous return

*Küçük atriyal septal defekti olan bir hastada orantısız sağ kalp genişlemesi:
Saklı kalmış anormal pulmoner ven dönüşü*

-  Kumral Çağlı¹
-  Mustafa Karakurt¹
-  Halil Lütfi Kısacık¹
-  Mustafa Özdemir²
-  Zehra Gölbaşı³

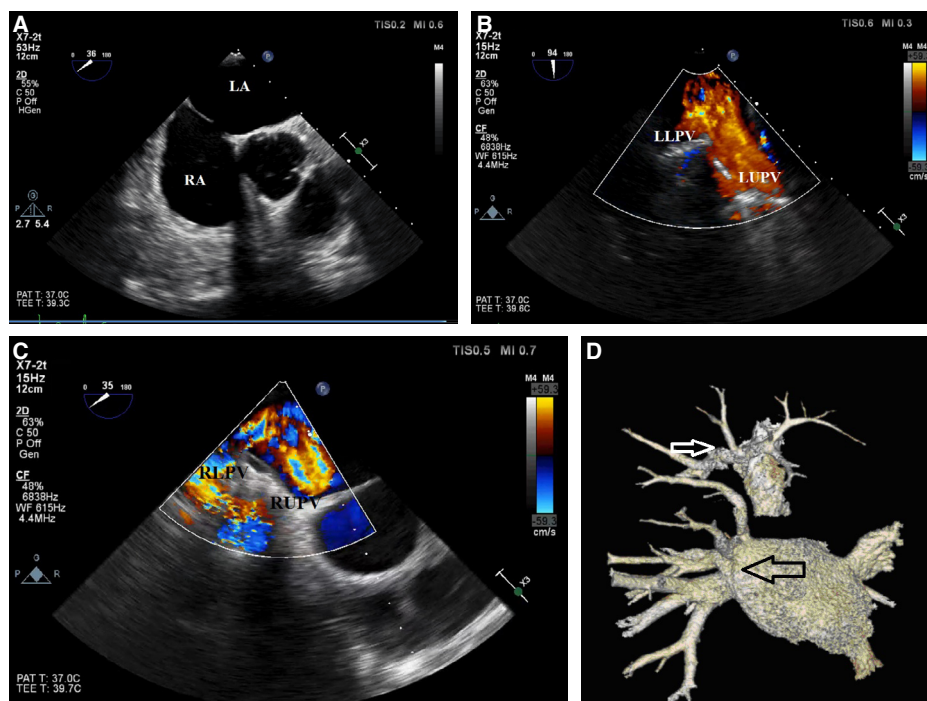
¹Department of Cardiology,
Türkiye Yüksek İhtisas
Hospital, Ankara, Turkey

²Department of Radiology,
Türkiye Yüksek İhtisas
Hospital, Ankara, Turkey

³Department of Cardiology,
Hitit University Faculty of
Medicine, Çorum, Turkey

A 39-year-old male patient admitted due to palpitations. His past medical history was unremarkable. A cardiovascular examination and surface electrocardiography results were normal. Transthoracic echocardiography revealed normal left ventricular function with moderate right heart chamber dilation, mild tricuspid regurgitation, a small secundum atrial septal defect (ASD), and systolic pulmonary artery pressure of 30 mm Hg.

Transesophageal echocardiography confirmed the presence of an ASD (10 mm in size) (Figure A, Videos 1, 2*), and 4 pulmonary veins (PVs) draining into the left atrium were identified (Figure B and C, Videos 3, 4*). Since the ASD size was inconsistent with the degree of right chamber dilation, computed tomography (CT) angiography was performed with the suspicion of abnormal PV return. CT angiography showed 4 PVs on the right side and 2 on the left side of the left atrium, and an abnormal PV draining blood from the right upper pulmonary lobe into the superior vena cava (Figure D). The patient was scheduled for corrective surgery. This case underlines that in patients with a small ASD and disproportionate right chamber dilation we have to suspect abnormal PV return, even when 4 ostia of PVs are demonstrated with echocardiography. This approach may prevent inadvertent percutaneous closure of an ASD.



Figures– (A) A secundum atrial septal defect observed in the mid esophageal short axis view. LA: Left atrium; RA: Right atrium. **(B and C)** A transesophageal echocardiography image of 4 pulmonary veins draining into the left atrium. LLPV: Left lower PV; LUPV: Left upper pulmonary vein; PV: Pulmonary vein; RLPV: Right lower PV; RUPV: Right upper PV. **(D)** In a 3-dimensional volume-rendering computed tomography image (anteroposterior view), 4 pulmonary veins (black arrow) are visible on the right side and 2 on the left side. An abnormal pulmonary vein draining into the superior vena cava (white arrow) can be seen in the upper part of the image.

*Supplementary video files associated with this presentation can be found in the online version of the journal.