

## Treatment of ineffective endocardial defibrillation with subcutaneous array: a case report

### Etkisiz endokardiyal defibrilasyonun subkutan yol ile tedavisi: Olgu sunumu

Özgür Kaplan, M.D., Sabri Demircan, M.D.

Department of Cardiology, İstanbul Bilim University Faculty of Medicine, İstanbul, Turkey

**Summary**– Defibrillation threshold (DFT) testing is an important part of ICD implantation. After placement of the ICD generator, a DFT test is performed to evaluate the integrity of the ICD system and to confirm a successful defibrillation safety margin. More than 6% of ICDs implanted are not within the DFT safety margin. Presently described is the case of a patient with a high DFT and some of the methods that can be used to manage this circumstance, including the use of a subcutaneous array.

**Özet**– Defibrilasyon eşik testi (DET) kalp içi defibrilatör (ICD) yerleştirilmesinin önemli bir parçasıdır. Başarılı defibrilasyonun güvenlik sınırı ve ICD sisteminin tümünü değerlendirmek için ICD jenaratörü yerleştirildikten sonra DET yapılır. ICD'li hastaların %6'dan fazlası DET güvenlik sınırında değildir. Yüksek DET'li hastalarda farklı tedavi yöntemleri kullanılmaktadır. Bu yazımızda yüksek DET'li hastada muhtemel tedavi yöntemi olarak subkutan yol kullanımını tartıştık.

The purpose of a defibrillation threshold (DFT) test is to evaluate the efficacy of implantable cardioverter defibrillator (ICD) therapy in the event of future ventricular tachyarrhythmia. Although DFT testing was initially popular, it was subsequently largely abandoned, in part because of the side effects. In some cases, however, the DFT test is still beneficial.

#### CASE REPORT

A 32-year-old male patient was admitted to emergency service unconscious and in ventricular fibrillation (VF). Following successful defibrillation and cardiopulmonary resuscitation, the patient was transferred to the coronary care unit. Acute management of the patient included administration of amiodarone and supportive treatment for hemodynamic and cerebral functions. Clinical history revealed aortic and mitral valve replacement 2 years earlier and dilated cardiomyopathy with Class II New York Heart Association (NYHA) functional capacity. Prior coronary angiography revealed that the coronary arteries were normal. Results of electrocardiography (ECG) indicated

normal sinus rhythm and left bundle-branch block. Echocardiographic examination revealed an ejection fraction (EF) of 25% with left ventricular diastolic and systolic diameters of 94 mm and 81 mm, respectively. Interventricular and intraventricular dyssynchrony were detected, and implantation of a biventricular ICD was recommended.

The ICD lead was actively fixed to the right ventricular (RV) apex via the left subclavian vein. The coronary sinus was cannulated with the guidance of an ablation catheter and coronary sinus angiography was performed. The coronary sinus lead was placed on the appropriate lateral coronary sinus vein. Another lead was fixed to the right atrial appendage. The pacing thresholds, sensing, and lead and shock coil impedances were within the normal range for all leads. A biventricular ICD generator (InSync Sentry, Medtronic,

#### Abbreviations:

DFT	Defibrillation threshold
ECG	Electrocardiography
EF	Ejection fraction
ICD	Implantable cardioverter defibrillator
IVC	Inferior vena cava
NYHA	New York Heart Association
RV	Right ventricular
SVC	Superior vena cava
VF	Ventricular fibrillation

Received: February 27, 2017 Accepted: May 09, 2017

Correspondence: Dr. Özgür Kaplan. Özel Şişli Florence Nittingale Hastanesi, Kardiyoloji Polikliniği, İstanbul, Turkey.

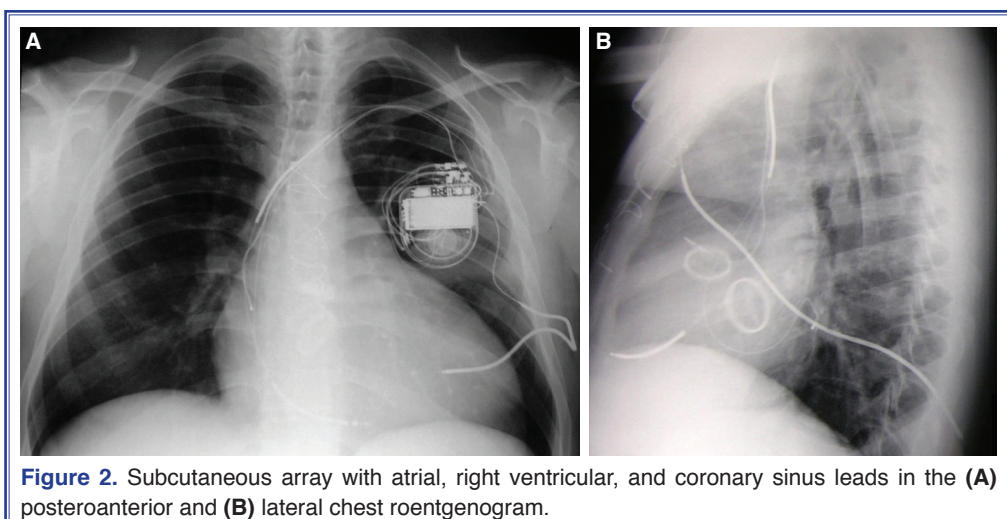
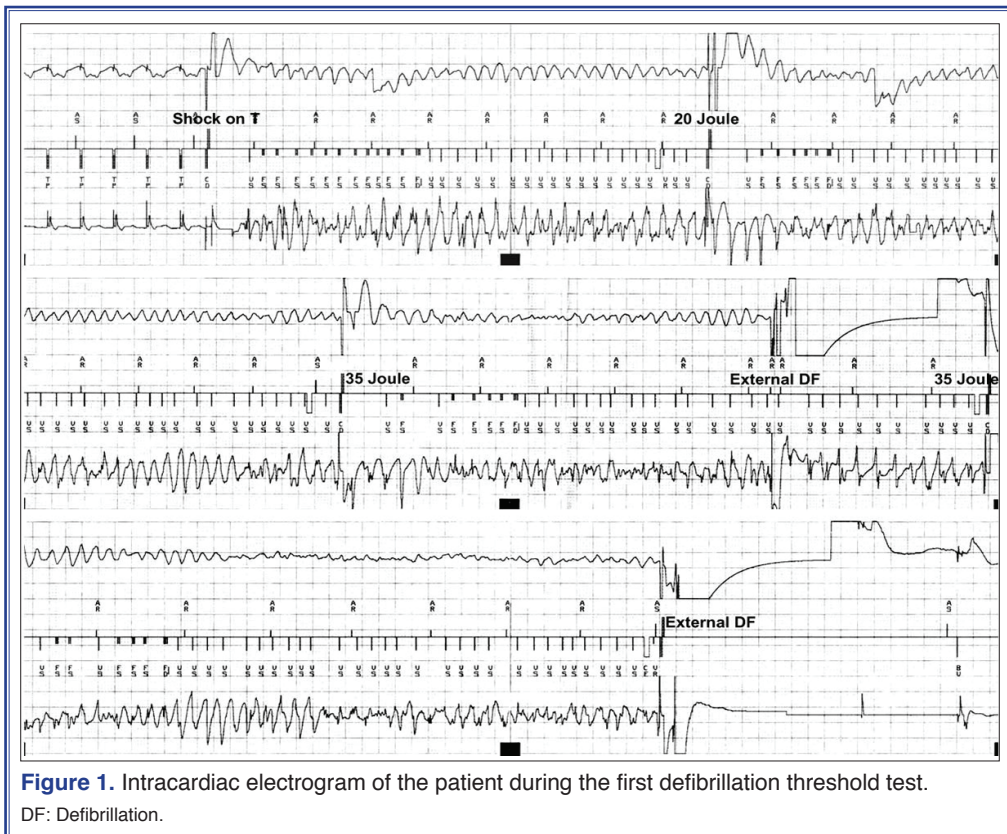
Tel: +90 212 - 444 0 436 e-mail: drozgurkaplan@yahoo.com

© 2017 Turkish Society of Cardiology



Inc., Minneapolis, MN, USA) was connected to the leads and placed in the prepectoral subcutaneous pocket. Following induction of VF with a T-wave shock, 20-J and 35-J defibrillation from the ICD was ineffective. An upper limit safety margin of 10 J had been selected. After several unsuccessful internal defibrillation attempts, the patient was defibrillated externally with 360 J (Fig. 1).

In an effort to decrease the defibrillation threshold, the ICD lead was unscrewed from the RV apex and fixed to the RV septum. The DFT test was repeated with the RV lead in the new position. However, 35-J delivery internally from the ICD via different pathways was ineffective 3 times. Sinus rhythm was recovered with external defibrillation. The superior vena cava (SVC) coil was disabled and repositioned



to provide a minimum DFT. The DFT test was postponed, and amiodarone was terminated and replaced with sotalol (80 mg 3 times per day) therapy. DFT was repeated 15 days later, and ICD therapy with 35 J was effective after once being ineffective at 25 J. Follow-up of the patient was continued in order to provide more time for amiodarone wash-out. The DFT test was repeated 20 days later and again revealed a high DFT threshold (25 J). The next option for successful defibrillation was to change the shock vector, with 2 coils in the right heart. An additional single shock coil was placed in the inferior vena cava (IVC), and with the help of a Y-connector, both the SVC and IVC coils were connected to the ICD. Finally, it was decided to implant a subcutaneous array and to pull back the IVC coil. A subcutaneous array (Medtronic, Inc., Minneapolis, MN, USA) was placed in the posterior thoracic region via a tunnel created using a tunneler with surgical back up. After pulling back the IVC coil, the array was connected to the SVC coil connector (Figs. 2a, b). A DFT test at 25 J was effective 3 consecutive times. This was the end criterion for the implantation; therefore, the SVC coil was capped and the ICD generator was placed in the pocket. Medical treatment included sotalol 80 mg 3 times a day along with a beta-blocker, angiotensin-converting enzyme inhibitor, diuretics, digoxin, and anticoagulant.

## DISCUSSION

End-stage pump failure and ventricular arrhythmia are the most common reasons for cardiac death in dilated cardiomyopathy. Biventricular ICD therapy is effective in both cases, as it provides resynchronization and thereby decreases the risk of sudden cardiac death. Clinical trials have documented the efficacy of an ICD for primary and secondary prevention of sudden death.<sup>[1]</sup>

Routine VF induction and documentation of effective defibrillation still remains a reasonable part of ICD placement because an inadequate safety margin may occur in >6% of patients.<sup>[2]</sup> The average DFT is  $9 \pm 5$  J in patients who have received an ICD.<sup>[3]</sup> Since the DFT may be influenced by many factors, including defibrillation test duration, electrolytes, sympathetic tone, use of an antiarrhythmic drug or other medications, a 10-J safety margin between the lowest successful defibrillation energy during testing and the maximum device output has been widely adapted as

standard practice.<sup>[4,5]</sup> For this reason, the DFT test is still accepted as part of the implantation.

NYHA Class III-IV heart failure, low EF, or increased left ventricular mass index can increase DFT.<sup>[6]</sup> It has also been reported that resting heart rate, age, coronary artery bypass graft, amiodarone use, left ventricle end-diastolic diameter, and duration of the ICD implantation have affected the DFT.<sup>[7]</sup>

Prolongation of the DFT test may cause temporary ventricular dysfunction, especially in patients with a low EF. In addition, anesthetic agents, potential myocardial damage and ischemia, and differences in neural activation during the test can cause increased sympathetic tonus, which can increase the DFT.<sup>[4]</sup>

Most cardiac drugs affect the DFT. It has been demonstrated in clinical trials that mexiletine, carvedilol, sildenafil, and venflaxasine increased the DFT. On the other hand, dofetilide and sotalol decreased the DFT. Furthermore, it has been shown that chronic amiodarone use increased the high DFT risk by 3 times. Despite numerous investigations in this area, there are still many opposing views.<sup>[4]</sup>

A considerable number of patients with high DFT are lost due to sudden cardiac death, possibly caused by insufficient shock energy.<sup>[8]</sup> In these patients, selection of a device with high output, changing the localization of the RV lead, use of a subcutaneous array, repositioning the proximal coil, disabling the SVC coil, coronary sinus lead implantation, changing the lead polarities, and use of a biphasic wave form may also be helpful.<sup>[4]</sup> In addition, it is important to exclude pneumothorax, which can also cause a high DFT.

In our case, dilated cardiomyopathy was present. Amiodarone treatment had been initiated because of cardiac arrest due to incessant malignant ventricular arrhythmia. Based on the presence of interventricular and intraventricular dyssynchrony, a biventricular ICD was selected for implantation. During the implantation, the DFT was high and the accepted safety margins could not be obtained. Neither lead repositioning nor disabling the SVC coil was sufficient to decrease the DFT for safe defibrillation. Repeated tests still did not produce a satisfactory DFT. Amiodarone was replaced with sotalol. Both medications are in the same group, but there are minimal differences in the mechanism. Sotalol has both beta-adrenoreceptor blocking (Class II) and cardiac



action potential duration prolongation (Class III) antiarrhythmic properties. Both isomers of sotalol have similar Class III antiarrhythmic effects, while 1 of them is responsible for virtually all of the beta-blocking activity.

Previous studies have recommended against routine DFT testing on the basis of a perceived lack of benefit, the lack of correlation between induced and spontaneous ventricular arrhythmia, and the potential for complications, including anesthesia-related risks and systemic embolism in patients with atrial fibrillation or severe left ventricular dysfunction.<sup>[9,10]</sup> The Shockless Implant Evaluation (SIMPLE) study suggested that routine DFT testing at device implantation has no significant impact on all-cause mortality.<sup>[11]</sup> Therefore, they concluded that DFT testing should no longer be routinely performed during de novo implantation. However, DFT testing may still be clinically relevant in specific patient populations, such as those with hypertrophic cardiomyopathy, channelopathies, congenital heart disease, right-sided device implants, and cases like ours.

A sufficient DFT was ultimately achieved with the implantation of a subcutaneous array and changing the shock vector. Success was confirmed during follow-up ICD interventions. Though it is an invasive method, a subcutaneous array can be safely implanted in patients with a high DFT.<sup>[12]</sup> Complications with a subcutaneous array have rarely been reported. However, patients must follow-up periodically to guard against lead fracture, which can result in mortal events.

In conclusion, a high DFT is not a rare phenomenon in patients who undergo ICD implantation. In such a case, alternatives should be employed to provide an acceptable DFT. If noninvasive manipulations do not yield an appropriate DFT, then more invasive methods, such as a subcutaneous array, should be considered.

**Informed consent:** Written informed consent was obtained from the patient for the publication of the case report.

**Peer-review:** Externally peer-reviewed.

**Conflict-of-interest:** None declared.

**Authorship contributions:** Concept – S.D.; Design – Ö.K., S.D.; Supervision – S.D.; Materials – Ö.K., S.D.; Data collection – Ö.K., S.D.; Analysis and/or interpretation – Ö.K., S.D.; Literature search – Ö.K., S.D.; Writing – Ö.K., S.D.

## REFERENCES

1. Bristow MR, Saxon LA, Boehmer J, Krueger S, Kass DA, De Marco T, et al. Cardiac-resynchronization therapy with or without an implantable defibrillator in advanced chronic heart failure. *N Engl J Med* 2004;350:2140–50. [CrossRef]
2. Kirilmaz A, Dokumaci B, Uzun M, Kilicaslan F, Dinckal MH, Yucel O, et al. Detection of the defibrillation threshold using the upper limit of vulnerability following defibrillator implantation. *Pacing Clin Electrophysiol* 2005;28:498–505. [CrossRef]
3. Shorofsky SR, Peters RW, Rashba EJ, Gold MR. Comparison of step-down and binary search algorithms for determination of defibrillation threshold in humans. *Pacing Clin Electrophysiol* 2004;27:218–20. [CrossRef]
4. Mainigi SK, Callans DJ. How to manage the patient with a high defibrillation threshold. *Heart Rhythm* 2006;3:492–5.
5. Marchlinski FE, Flores B, Miller JM, Gottlieb CD, Hargrove WC 3rd. Relation of the intraoperative defibrillation threshold to successful postoperative defibrillation with an automatic implantable cardioverter defibrillator. *Am J Cardiol* 1988;62:393–8. [CrossRef]
6. Hodgson DM, Olsovsky MR, Shorofsky SR, Daly B, Gold MR. Clinical predictors of defibrillation thresholds with an active pectoral pulse generator lead system. *Pacing Clin Electrophysiol* 2002;25:408–13. [CrossRef]
7. Schuger C, Ellenbogen KA, Faddis M, Knight BP, Yong P, Sample R; VENTAK CHF/CONTAK CD Study Investigators. Defibrillation energy requirements in an ICD population receiving cardiac resynchronization therapy. *J Cardiovasc Electrophysiol* 2006;17:247–50. [CrossRef]
8. Epstein AE, Ellenbogen KA, Kirk KA, Kay GN, Dailey SM, Plumb VJ. Clinical characteristics and outcome of patients with high defibrillation thresholds. A multicenter study. *Circulation* 1992;86:1206–16. [CrossRef]
9. Shukla HH, Flaker GC, Jayam V, Roberts D. High defibrillation thresholds in transvenous biphasic implantable defibrillators: clinical predictors and prognostic implications. *Pacing Clin Electrophysiol* 2003;26:44–8. [CrossRef]
10. Strickberger SA, Klein GJ. Is defibrillation testing required for defibrillator implantation? *J Am Coll Cardiol* 2004;44:88–91.
11. Healey JS, Hohnloser SH, Glikson M, Neuzner J, Mabo P, Vinolas X, et al. Cardioverter defibrillator implantation without induction of ventricular fibrillation: a single-blind, non-inferiority, randomised controlled trial (SIMPLE). *Lancet* 2015;385:785–91. [CrossRef]
12. Kettering K, Mewis C, Dörnberger V, Vonthein R, Bosch RF, Seipel L, et al. Long-term experience with subcutaneous ICD leads: a comparison among three different types of subcutaneous leads. *Pacing Clin Electrophysiol* 2004;27:1355–61.

**Keywords:** Defibrillation test; implantable defibrillator; subcutaneous array.

**Anahtar sözcükler:** Defibrilasyon test; implante defibrilatör; subkutan yol.