

## A rare disease causing mitral regurgitation: posterior mitral leaflet aneurysm

### Mitral yetersizliğe neden olan nadir bir hastalık: Arka mitral yaprakçık anevrizması

Uğur Aksu

Kamuran Kalkan

Pınar Demir

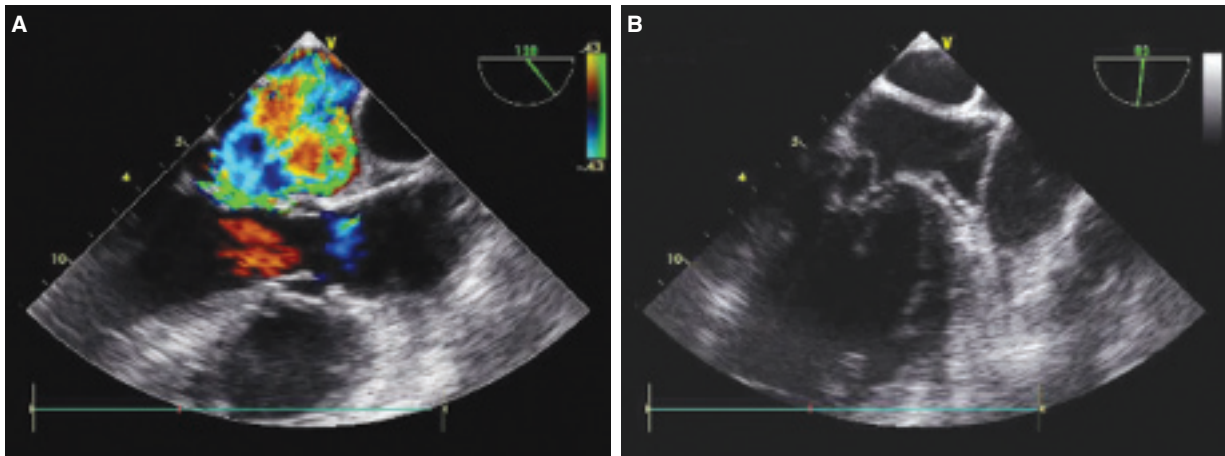
İbrahim Halil Tanboğa

Department of Cardiology,  
Atatürk University Faculty of  
Medicine, Erzurum

A 65-year-old man presented with a history of progressive dyspnea for two months and new-onset palpitation. He had no history of any cardiac disease such as congestive heart failure or endocarditis. On physical examination, his blood pressure was 100/60

mmHg, pulse rate 125 beats per minute, respiration rate 20 per minute, and oxygen saturation 85% while breathing ambient air. Auscultation revealed an api-

cal 4/6 pansystolic murmur and pulmonary crackles on both lower lungs. ECG showed atrial fibrillation with rapid ventricular response. X-ray demonstrated moderate cardiomegaly and signs of pulmonary congestion. Transthoracic echocardiography showed a severe eccentric anteriorly directed mitral regurgitation jet that encircled the entire left atrium (Fig. A, \*Video 1); there was no mitral leaflet thickening or restricted motion. Transesophageal echocardiography was performed to determine the etiology of the mitral regurgitation and showed a severe eccentric anteriorly directed mitral regurgitation jet that encircled the entire left atrium with large posterior mitral leaflet aneurysm (Fig. B, \*Video 2). The patient was referred to the cardiac surgery unit to perform mitral valve repair.



**Figures– (A)** Mid-esophageal apical long-axis view showing a severe eccentric anteriorly directed mitral regurgitation jet that encircled the entire left atrium. **(B)** Mid-esophageal long-axis view showing large posterior mitral leaflet aneurysm. \* *Supplementary video files associated with this presentation can be found in the online version of the journal.*

