

## Doppler ultrasonography in lower extremity peripheral arterial disease

### Alt ekstremitte periferik arter hastalığında Doppler ultrasonografi

Samet Verim, M.D., İlker Taşçı, M.D.#

Department of Radiology, Mevki Hospital, Ankara;

#Departments of Internal Medicine and Geriatrics, Gulhane Military Academy, Ankara

**Summary**– Systemic atherosclerosis is a condition which progresses with age, decreases quality of life, and life expectancy. Lower extremity peripheral arterial disease (PAD) is a common manifestation of systemic atherosclerosis in the elderly. These individuals have a 2 to 4 fold higher risk of coronary heart disease and stroke. In addition, systemic atherosclerosis causes overall functional disability including restricted lower extremity movements. When used alone for diagnostic purposes, claudication is an unreliable sign of PAD in all age groups especially the elderly. Moreover, claudication is difficult to define due to the advancing age and degenerative changes in lumbar and peripheral joints. Doppler ultrasonography (US) is an easily available and noninvasive means of arterial visualization in the lower extremities. In this review, supporting evidence for the use of Doppler US in the diagnosis of PAD will be discussed. Past and present recommendations regarding Doppler US in the current PAD guidelines will be overviewed.

Many of the chronic illnesses that are associated with increased age and prolonged lifespan are more frequently accompanied by significant changes in the vascular system. Narrowing and occlusions occur not only in coronary and cerebral arteries, but also in the aorta and in its branches as a result of the atherosclerotic process. This condition is called peripheral arterial disease (PAD) or peripheral arterial occlusive disease. In addition, arterial stenosis of the lower limbs is generally symmetrical and most commonly occurs in the adductor canal (Hunter's canal).<sup>[1]</sup> However, the distal part of leg and foot is less seriously affected by atherosclerosis since the popliteal artery is rich in blood supply due to collateral development.

**Özet**– Sistemik ateroskleroz yaş ile paralel olarak ilerleyen, yaşam kalitesini ve süresini azaltan bir durumdur. Alt ekstremitte periferik arter hastalığı (PAH) sistemik aterosklerozun yaşlıda oldukça sık görülen bir yansımasıdır. Alt ekstremitelerde hareket kısıtlılığına ve tüm fonksiyonlarında azalmaya neden olmaktadır. Bu hastalığı olan kişilerde koroner kalp hastalığı ve inme açısından 2-4 kat daha fazla risk bulunmaktadır. Klodikasyon tek başına tanı amacıyla kullanıldığında yaşlılarda daha fazla olmak üzere tüm olgularda PAH'yı göstermede güvenilir bir işaretir. İlerleyen yaş ile bel omurları ve çevresel eklemlerde meydana gelen dejeneratif değişiklikler tipik klodikasyonun tanımlanmasını da zorlaştırmaktadır. Doppler ultrasonografi (USG) alt ekstremitte arterlerinin görüntülenmesinde kullanılan, kolay ulaşılabilir ve invaziv olmayan bir görüntüleme yöntemidir. Bu yazıda Doppler USG'nin PAH tanısını koymadaki yeri kanıta dayalı olarak tartışıldı. PAH'ya ilişkin güncel kılavuzlarda Doppler USG'nin kullanımı ile ilişkili eski ve yeni öneriler gözden geçirildi.

The arterial system of the lower extremities begins at the level of aortic bifurcation. Thereafter, it reaches the tiptoe by following the order of external iliac artery, and ending with the dorsalis pedis artery. When examining the arteries of the lower extremities, the collaterals that develop in the presence of occlusion and anatomic variations should also be examined with caution.

#### Abbreviations:

ACC	American College of Cardiology
AHA	American Heart Association
CA	Catheter angiography
CTA	Computerized tomography angiography
CW	Continuous wave
MRA	Magnetic resonance angiography
PAD	Peripheral arterial disease
PSV	Peak systolic velocity
VR	Velocity ratio

Received: January 29, 2013 Accepted: April 02, 2013

Correspondence: Dr. Samet Verim. Mevki Hastanesi, Radyoloji Servisi, Dışkapı, Ankara.

Tel: +90 312 - 310 35 35 e-mail: drsametverim@yahoo.com

© 2013 Turkish Society of Cardiology



Arterial pathologies may be studied in two major categories: (1) occlusive arterial diseases and (2) non-occlusive arterial diseases. In the next part of this review, we will address the diagnostic value of Doppler ultrasound (US) in the chronic occlusive arterial disease of the lower limbs, its place in the current guidelines, and its limitations. One of the most important characteristics of the lower extremity PAD is that it indicates presence of disseminated and significant atherosclerosis in an affected subject.<sup>[2]</sup> The presence of PAD classifies an individual in the group of cardiovascular disease. In this case, blood pressure, glucose and lipid targets, quality of life expectations as well as prognostic approaches vary largely.

The incidence of occlusive arterial diseases of the lower extremities increases with age regardless of the presence of other risk factors for cardiovascular disease. When surveys from different countries are considered, the prevalence of the disease in the general population is about 3-10%, reaching the level of 15-20% after the age of 70.<sup>[3,4]</sup> This suggests that the occlusive arterial disease of the lower extremities is largely the problem of elderly. The prevalence of lower extremity PAD in Turkey was first investigated in the CAREFUL study.<sup>[5]</sup> In this multicenter national survey, subjects aged above 70-years-old or subjects aged 50-69 years with at least one cardiovascular risk factor were enrolled. The CAREFUL study concluded that overall prevalence of ankle brachial index and PAD was 20% in the study population and the frequency was similar in both genders. The prevalence of the disease was above 30% in subjects older than 70 years of age indicating a marked increase compared to aging. A recent multicenter study in an Aegean area in Turkey showed the prevalence of low ankle brachial index as 10.45% and 7.36% in men and woman, respectively.<sup>[6]</sup> When the authors defined the lower extremity PAD as either having a low ( $\leq 0.9$ ) or high ( $\geq 1.3$ ) ankle brachial index value, the frequency of the disease was calculated as 19.76%. However, a similar but single-center study conducted in the setting of internal medicine outpatient care at a tertiary hospital in Ankara determined a mean prevalence of 5% in subjects above 50-years-old.<sup>[7]</sup> One out of every five individuals above 40 years old among the Turkish adults could be regarded as having occlusive arterial disease of the lower extremities. These variations may be explained by several reasons.<sup>[8-11]</sup> Since the recognition of age related functional deficits in the lower

extremities is frequently complicated by a multi-etiological course, the diagnosis of lower extremity PAD becomes more important when its asymptomatic nature is considered.

### Imaging methods in PAD

Catheter angiography (CA) is recommended as the reference standard in the diagnosis of PAD.<sup>[12]</sup> However, the potential disadvantages of this method include requirement of vascular access, risk of ionizing radiation and exposure to contrast agent. Magnetic resonance angiography (MRA), computerized tomography angiography (CTA) and Doppler US are the currently the alternative imaging methods. Although, these tool are less invasive compared to CA, concerns related to the use of ionizing radiation still remain with CTA. In addition, the use of contrast substance has potential risks in angiography performed with CTA or MRA. However, performing Doppler ultrasonography possess neither of these risks. Therefore, it is important to examine the true value of the Doppler US in the diagnostic examination of PAD in the lower limbs.

### Basic principles of the Doppler US

Doppler technique was first described by the Australian physicist and mathematician, Christian Doppler. The Doppler Effect is defined as the return of a high-frequency sound wave with a different frequency when it encounters a moving structure in the vessel. The waves towards the transducer are coded with red and the waves moving away from the transducer are coded with blue. Main Doppler types may be classified as follows; i) Continuous wave (CW) Doppler, ii) Spectral (Pulse) Doppler, iii) Color Doppler, and iv) Power Color Doppler.

In the lower extremity, arterial Doppler ultrasonography B-mode images are obtained initially allowing a clear evaluation of anatomic structures and atheromatous plaques. In a normal lower extremity artery, there is a three-phase flow pattern, also called triphasic flow pattern. First, a high velocity flow results from the cardiac cycle, then an inverse flow occurs in the early diastole which is followed by a progressive flow velocity in the late diastole.<sup>[13]</sup> This triphasic waveform is characteristic of arteries supplying muscular bed, which has high peripheral resistance. During exercise or transient ischemia, there is loss of triphasic pattern (Fig. 1a). In occlusive arterial diseases, flow veloc-

ity is increased in the region where the lumen is narrowed. Conversely, vascular resistance is decreased as a result of collateral circulation and vasodilation in the distal part of the obstruction. As the disease progresses, the triphasic flow diminishes to a biphasic flow (Fig. 1b). This is due initially to the loss of elastic recoil caused by ‘hardening’ of the arteries. If the disease progresses further, the flow loses its pulsatile nature to a monophasic signal with increased diastolic flow owing to regional vasodilation (Fig. 1c).

Using ultrasound, the degree of arterial disease in the lower extremities is classified into 4 categories, including 1) normal (0% stenosis), 2) 1-49% stenosis, 3) 50-99% stenosis, and 4) total occlusion (100% stenosis).<sup>[14]</sup> Velocity criteria for the assessment of lower limb arterial stenosis are based on the peak systolic velocity (PSV) and velocity ratio (VR) when the flow velocity is normal PSV is lower than 1.5 and VR is 1.5:1.<sup>[15]</sup> In case of a 0-49% stenosis PVS is found between 1.5 and 2, and VR is found 1.5-2:1. For a stenosis between 50-99%, PVR is found >2.0 and VR is calculated as >4:1.<sup>[15]</sup> Diagnostic criteria for a hemodynamically important ‘50-99% stenosis’ require that the peak systolic velocity is double at the lesion when compared with a more-proximal segment (it is greater than 200 cm/s, with evidence of turbulence).<sup>[15]</sup>

### Doppler ultrasonography in clinical studies for the lower extremity PAD

#### i. Comparisons between Doppler US and CA

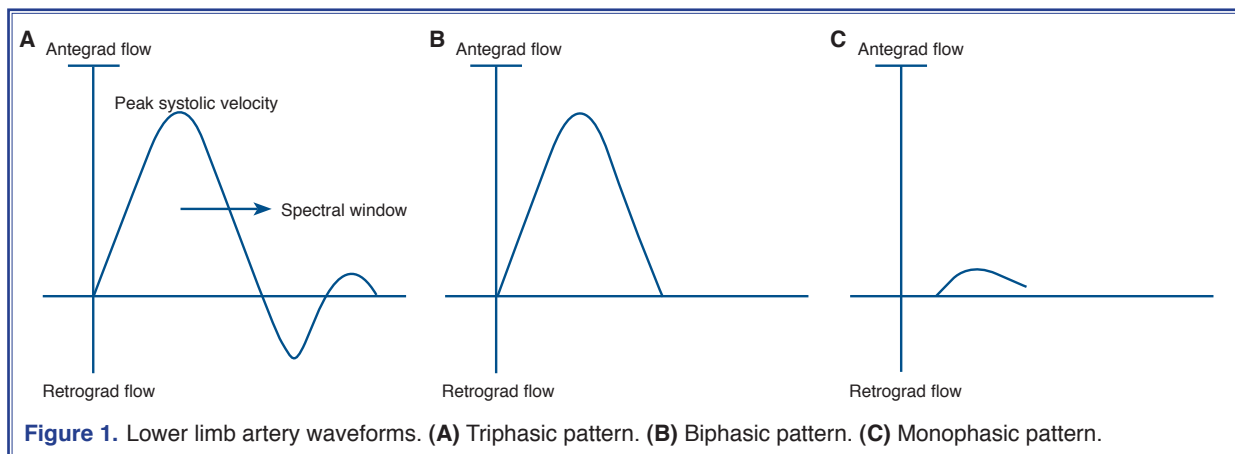
Approximately 30 years ago, initial clinical studies concluded that Doppler ultrasonography could be used in the diagnosis of PAD of the lower extremities.<sup>[16]</sup> In the following years, many authors presented data

suggesting that CA could successfully be replaced by Doppler US.<sup>[17,18]</sup> As a result of fast technological advances and reduced costs, Doppler ultrasonography equipment was used in many hospitals and clinics.

Well-designed clinical studies that performed head-to-head comparisons of Doppler ultrasonography and CA, are the focus of this review. In all studies conducted to date, sample size remained quite small because angiography (the reference standard) was an invasive method. In an early well-designed study performed on a total of 40 patients,<sup>[19]</sup> Doppler ultrasonography was found to have a sensitivity of 92% and a specificity of 98% in aortoiliac disease. For femoro-popliteal disease, these values were calculated to be 88% and 98%, respectively. For the success of Doppler ultrasonography in the demonstration of stenosis, sensitivity and specificity reached to 100% in aortoiliac arteries and to 90% and 100% in femoro-popliteal arteries.

The sensitivity of Doppler US was found to decrease in the distal parts of the extremity in a study that evaluated 24 patients and 213 arterial segments with the aim of calculating the sensitivity of Doppler US in the detection of the stenosis in the below-knee arteries.<sup>[20]</sup> However, the author concluded that ultrasonography had a quite high success in the detection of stenosis in the lower limb arteries.

In another study that evaluated 134 arterial segments in 25 patients, Doppler ultrasonography and CA were performed in patients with claudication. The combination of both methods were well-correlated in the detection of significant stenosis and total occlusions.<sup>[21]</sup> In this investigation, the authors concluded that the sensitivity and specificity of Doppler ultrasonography were 89% and 95%, respectively when



angiography was considered as the gold standard.. In addition, it was determined that angiography showed the occluded areas more extensively.

A similarly designed study conducted by Bergamini et al.<sup>[22]</sup> examined 404 arterial segments in 44 patients. Doppler ultrasonography had the following sensitivity/specificity values for the detection of a stenosis  $\geq 50\%$ ; main femoral artery 86/96%, ascending superficial femoral artery 95/98%, descending superficial femoral artery 97/90%, above-knee upper popliteal artery 84/90%, below-knee popliteal artery 47/98%, and tibioperoneal trunk 25/100%. However, the authors also reported that occurrence of stenosis in multiple regions (which is an often observed condition) decreased the sensitivity of the method.

Sensier et al.<sup>[23]</sup> were among the investigators who evaluated Doppler US for the diagnosis of PADs of the lower limbs. In a relatively large study, 1658 segments from the aortoiliac, femoropopliteal and tibial arteries from 79 patients were evaluated. They found a significant overall consistency between Doppler ultrasonography and arteriography. Sensitivity and specificity values (both 88%) were reported for the femoropopliteal segment. In a similar but retrospective trial performed by the same investigator group, it was concluded that Doppler US could also be recommended to evaluate infrapopliteal disease.<sup>[24]</sup>

In one of the best well-designed studies conducted to date, Aly et al.<sup>[25]</sup> performed both CA and Doppler US on 177 legs and 3108 arterial segments (630 aortoiliac, 531 femoral, 885 femoropopliteal and 1062 leg and ankle vessels) from 90 patients. In this work, stenosis Doppler US determined that sensitivity and specificity of femoral artery stenosis were found to be 100% and 99%, respectively. The corresponding values for occlusion were also found to be 100% and 99%, respectively in the same region. For aortoiliac artery, femoropopliteal artery and more distal artery stenosis, the sensitivity values were 88%, 95% and 82%, respectively, while specificity values were 99% for all these segments. The authors concluded that Doppler US had an overall sensitivity of 92% and a specificity of 99% for stenosis using angiography in all lower limb arteries, which were quite comparable to those invasive methods.

## **ii. Comparisons between Doppler US and MRA**

When the whole lower extremity is considered, con-

trast enhanced MRA has the highest diagnostic value for the diagnosis of stenosis, with a sensitivity of 95% (92-99.5%) and a specificity of 97% (64-99%).<sup>[26]</sup> In one of the earliest works, Doppler ultrasonography was reported to be even more sensitive than MRA for the detection of infrainguinal stenosis.<sup>[27]</sup> For the stenosis in the iliac arteries, other researchers found similar sensitivity and specificity values for MRA, CA and Doppler US.<sup>[28]</sup> During the same period, Visser and Hunink performed a meta-analysis by reviewing the already published studies collectively in an attempt to delineate the diagnostic value of Doppler ultrasonography and/or MRA in PAD.<sup>[29]</sup> They calculated the sensitivity value as 97.5% for MRA and 87.6% for Doppler US and the difference was statistically significant. Specificity values, however, were found to be similar (96.2% for magnetic resonance and 94.7% for Doppler ultrasonography). The authors recommended that MRA could replace CA as the preferred method with high diagnostic accuracy.

In a more recent study that evaluated 668 segments in a total of 249 patients, sensitivity and specificity values were found to be statistically different for Doppler ultrasonography (76% and 93%) and MRA (84% and 97%) when compared to each other.<sup>[30]</sup> Newer studies could be considered to have less methodological drawbacks due to developments in technical facilities as well as experience gained in time in recognition of pathological or nonpathological images.

In a very recent prospective study performed by Bueno et al.<sup>[31]</sup> (who examined 1720 segments on 40 patients) the utility of Doppler US and MRA was evaluated by using CA as reference point. When the detection of stenosis  $\geq 50\%$  was taken as the sole criterion, sensitivity and specificity values were calculated to be 81.4% and /99% for Doppler ultrasonography, and 91 and 99% for MRA. In the same study, the detection of total occlusion sensitivity and specificity values were calculated as 90% and /97% for Doppler US, and 95.4% and 98% for MRA. The latter study demonstrated a relatively low sensitivity value for Doppler ultrasonography in the detection of significant stenosis in the lower limb arteries whereas, the specificity value was quite acceptable.

Imaging techniques are also used to determine the preoperative period in subjects with lower extremity PAD. Although very high quality visualization is obtained by MRA, it is less accurate than ultrasound



based arterial mapping for formulation of a preoperative plan for lower extremity revascularization.<sup>[32,33]</sup> Indeed, high-quality Doppler ultrasonography has been proposed as a reasonable alternative to CA in subjects with lower limb ischemia.<sup>[34,35]</sup> In addition to diagnostic purposes, Doppler ultrasonography is recommended to be used simultaneously during balloon angioplasty and stent placement for infrainguinal arterial occlusive disease due to its ease of use, safety and reliability.<sup>[36]</sup>

### Doppler ultrasonography in recent guidelines for lower extremity PAD

Although the clinical importance of the disease gained recognition in the early 1990s, the first well-organized and evidence-based PAD management guideline was published by the American College of Cardiology (ACC) and the American Heart Association (AHA) in 2006 with the title ‘‘ACC/AHA 2005 Practice Guidelines for the management of patients with PAD’’.<sup>[37]</sup> The guideline committee recommended that subjects with claudication should be first screened by using Doppler ultrasonography. It was advised that Doppler US should be used for the determination of the anatomic localization, the grade of the stenosis (with high level of evidence class I, level A), and for the follow-up of post-operative femoropopliteal and femorotibial-pedal vein grafts (evidence class I, level A). Doppler ultrasonography was also recommended for the selection of subjects that could benefit from endovascular intervention (evidence class IIa, level B). Moreover, the ACC/AHA guideline addressed Doppler ultrasonography as a quality tool to select those individuals that could benefit from the revascularization surgery by identifying the level of arterial segments that require surgical anatomoses (evidence class IIa, level B). It was noted that the utility of Doppler ultrasonography in identification of long-term success of the percutaneous transluminal angioplasty was not clear (evidence class IIb, level B). However, it could be an option for the evaluation of patency of the synthetic femoro-popliteal bypass grafts in the routine follow-up (evidence level B).

In the international ‘‘Inter-Society Consensus for the Management of PAD’’ (TASC II) (2) guideline that was published one year later, the imaging methods in the detection and localization of stenosis in the lower limb vessels were reported to be Doppler ultrasonog-

raphy, MRA and CTA (with the level of evidence as ‘‘B’’ without giving priority to any of these three options). TASC II guideline noted that, while some patients might be operated based only on the ultrasonography results, angiography-based imaging methods were used in the majority of the cases in the clinical practice. TASC II guideline has not been updated but, the need for an angiogram is still left only for the people who are seriously considered for revascularization.

With the emergence of new evidence, ACC/AHA 2005 guideline was updated in 2011<sup>[38]</sup> with an attempt to establish a harmony with the TASC II guideline.<sup>[2]</sup> Following this update, Doppler ultrasonography still maintained its diagnostic value by itself or with other tools for the diagnosis of the PAD of the lower extremities. For European countries, the first guideline of PAD was recently published by the European Society of Cardiology in 2012.<sup>[39]</sup> Similarly to other guidelines, ESC guidelines recommended non-invasive Doppler ultrasonography among the first diagnostic tests to confirm and localize stenosis lesions (evidence class I, level B). To localize stenosis lesions and consider revascularization options, this latest guideline also indicated the need for either of Doppler ultrasonography, CTA or MRA (evidence class I, level A), without giving superiority to any of them. Finally, the ECS guideline recommended that any patient suggested for surgery based on any of the imaging tools should also be tested hemodynamically, which can be achieved only by Doppler arteriography.

The most recent guideline recommendations on the management of PAD were published by the ACC foundation in 2013.<sup>[40]</sup> In this update, Doppler US measurements were demonstrated among the top diagnostic tests to provide an accurate assessment of lower extremity PAD location and severity (evidence class I, level A), and to provide accurate follow-up after revascularization (evidence class I, level A). Doppler arteriography was also addressed as a useful tool to select patients as candidates for endovascular intervention and surgical bypass (evidence class IIa, level B). Finally, the guideline notes that the use of Doppler US is not well established to assess long-term patency of percutaneous transluminal angioplasty (evidence class IIb, level B) but, may be considered for routine surveillance after femoral-popliteal bypass with a synthetic conduit (evidence class IIb, level B).

## Doppler ultrasonography in stenoses in other vascular beds

### *i. Extracranial carotid artery disease*

2011 ACCF/AHA coordinated guideline<sup>[41]</sup> recommends ultrasonography to evaluate asymptomatic patients with known or suspected carotid stenosis as the initial diagnostic test to detect hemodynamically significant stenosis (evidence class I, level C). For symptomatic individuals, ultrasonography is recommended to detect carotid stenosis in patients who develop focal neurological symptoms (evidence class I, level C). The same guideline recommends use of other contrast enhanced techniques for the lesions that are not adequately assessed by ultrasonography.

### *ii. Renal and mesenteric arterial diseases*

The latest guideline on PAD recommends Doppler ultrasonography as a screening test in the diagnosis of renal artery stenosis (evidence class I, level B), similar to MR or CT angiography.<sup>[40]</sup> Doppler US, along with CTA and gadolinium-enhanced MRA is recommended as an initial test for supporting the clinical diagnosis of chronic intestinal ischemia (evidence class I, level B).<sup>[40]</sup> However for acute intestinal ischemia, Doppler ultrasonography of the abdomen is not recommended as an appropriate diagnostic tool for suspected disease (evidence class III, level C).

### *iii. Aneurysms of the abdominal aorta and its branch vessels*

For the aortic aneurism, ultrasound is recommended as a screening tool for the subjects at the risk of the condition (evidence class I, level B). Moreover, men who are 65 to 75 years of age who have ever smoked are recommended for physical examination and 1-time ultrasound screening for detection of aortic aneurism (evidence class IIa, level B). Ultrasound screening is also recommended for any suspected aneurism of the aortic branches including popliteal aneurism (evidence class I, level B).<sup>[40]</sup>

## Limitations of Doppler ultrasonography

Doppler ultrasonography is comparable in sensitivity to angiography, especially in the femoropopliteal arterial stenosis or occlusions. However, its sensitivity in the crural area is relatively lower. This may be explained in part by inter-observer variability of the technique, which may be more pronounced as the

vessel diameter decreases. Indeed, the degree of inter-observer variations have been examined scientifically in clinical studies. When a stenosis of  $\geq 50\%$  is considered, operator-dependent differences were found to be quite low, except for the pedal arteries.<sup>[42,43]</sup> In addition, the presence of diabetes mellitus (which is known to cause early calcifications in the vascular wall) does not cause inter-observer variations in Doppler ultrasonography readings.

In several studies, Doppler ultrasonography was reported to have difficulty in differentiating a 99% stenosis from complete occlusion.<sup>[18,20,23,25,44]</sup> In addition, obesity and presence of intestinal gas may complicate the quality imaging of the arteries. There is limited number of studies conducted on below-knee arteries and the sensitivity and the specificity were found to be 75-83% and 77-95%, respectively.<sup>[20,45]</sup> Distal arteries are frequently difficult to be imaged due to their small size. Moreover, age related or accelerated vessel wall calcifications easily impair the conduct of the Doppler signals.<sup>[46]</sup> However, this latter issue has the advantage of the use of Doppler ultrasonography in the detection of less calcified areas appropriate for anastomosis in subjects for whom a surgical approach is planned.<sup>[47]</sup>

Although Doppler US is a non-invasive technique, approximately one fifth of the patients report mild pain or discomfort during or immediately after the procedure.<sup>[26]</sup> In addition, successful application of the method may not be possible in the areas with ulcers or marked scars. However, in contrast with CA and MRA, the occurrence of a life-threatening adverse event is unlikely. Finally, Doppler arteriography in the entire lower extremities is operator dependent and labor intensive, which might be further difficult in individuals with poor cooperation or mobility.

Current evidence suggests that Doppler ultrasonography can successfully be used in the diagnosis and follow-up of PADs of the lower extremities which is a prevalent and serious condition. As the disease is much more frequent in the elderly, Doppler ultrasonography has the advantage of being a noninvasive procedure without the need for contrast agents. Especially in subjects with claudication, Doppler ultrasonography is recommended by the latest guidelines as the first diagnostic tool to be chosen when the ankle brachial index measurement is not available. With its high specificity, especially the demonstration of the absence of a stenosis  $\geq 50\%$  using Doppler ultraso-

nography mostly excludes the presence of PAD in the lower limbs. Although this technique does not allow imaging of the arterial tree as a whole, valuable and quality information on vessel hemodynamics can easily be obtained in the perioperative period.

**Conflict-of-interest issues regarding the authorship or article: None declared**

## REFERENCES

- Schwartz SM, Heimark RL, Majesky MW. Developmental mechanisms underlying pathology of arteries. *Physiol Rev* 1990;70:1177-209.
- Norgren L, Hiatt WR, Dormandy JA, Nehler MR, Harris KA, Fowkes FG, et al. Inter-society consensus for the management of peripheral arterial disease. *Int Angiol* 2007;26:81-157.
- Selvin E, Erlinger TP. Prevalence of and risk factors for peripheral arterial disease in the United States: results from the National Health and Nutrition Examination Survey, 1999-2000. *Circulation* 2004;110:738-43. [CrossRef]
- Fowkes FG. Epidemiology of atherosclerotic arterial disease in the lower limbs. *Eur J Vasc Surg* 1988;2:283-91. [CrossRef]
- Bozkurt AK, Tasci I, Tabak O, Gumus M, Kaplan Y. Peripheral artery disease assessed by ankle-brachial index in patients with established cardiovascular disease or at least one risk factor for atherothrombosis-CAREFUL study: a national, multi-center, cross-sectional observational study. *BMC Cardiovasc Disord* 2011;11:4. [CrossRef]
- Karabay Ö, Karaçelik M, Yılık L, Tekin N, İriz AB, Kundereli S, et al. Ischemic peripheral arterial disease: A screening survey. [Article in Turkish] *Türk Göğüs Kalp Damar Cerrahisi Dergisi* 2012;20:450-7.
- Gezer M, Tasci I, Demir O, Acikel C, Cakar M, Sağlam K, et al. Low frequency of a decreased ankle brachial index and associated conditions in the practice of internal medicine in a Turkish population sample. *Int Angiol* 2012;31:454-61.
- Tasci I, Verim S, Kabul HK, Aydogdu A. Ankle brachial index as a predictor of subclinical atherosclerosis in the elderly. *Int J Cardiol* 2012;160:147. [CrossRef]
- Tasci I. Best practice in ankle brachial index measurement. *J Wound Ostomy Continence Nurs* 2012;39:238. [CrossRef]
- Kabul HK, Aydogdu A, Tasci I. Calculation methods of ankle brachial index and correct diagnosis of peripheral arterial disease. *J Atheroscler Thromb* 2012;19:691-2. [CrossRef]
- Tasci I, Kabul HK. Diagnosing PAD by calculating the ankle brachial index: adherence to the guidelines. *J Vasc Nurs* 2012;30:3-4. [CrossRef]
- Rooke TW, Hirsch AT, Misra S, Sidawy AN, Beckman JA, Findeiss LK, et al. 2011 ACCF/AHA Focused Update of the Guideline for the Management of Patients With Peripheral Artery Disease (updating the 2005 guideline): a report of the American College of Cardiology Foundation/American Heart Association Task Force on Practice Guidelines. *J Am Coll Cardiol* 2011;58:2020-45. [CrossRef]
- Hatsukami TS, Primozich J, Zierler RE, Strandness DE Jr. Color Doppler characteristics in normal lower extremity arteries. *Ultrasound Med Biol* 1992;18:167-71. [CrossRef]
- Lau JF, Weinberg MD, Olin JW. Peripheral artery disease. Part 1: clinical evaluation and noninvasive diagnosis. *Nat Rev Cardiol* 2011;8:405-18. [CrossRef]
- Allen PL, Gallagher K. The peripheral arteries. In: Allen PL, Dubbins PA, Pozniak MA, McDicken N, editors. *Clinical Doppler ultrasound*. 2nd ed. London, England: Churchill Livingstone; 2006. p. 73-99.
- Demorais D, Johnston KW. Assessment of aorto-iliac disease by non-invasive quantitative Doppler waveform analysis. *Br J Surg* 1981;68:789-92. [CrossRef]
- Kohler TR, Nance DR, Cramer MM, Vandenburghe N, Strandness DE Jr. Duplex scanning for diagnosis of aortoiliac and femoropopliteal disease: a prospective study. *Circulation* 1987;76:1074-80. [CrossRef]
- Legemate DA, Teeuwen C, Hoeneveld H, Ackerstaff RG, Eikelboom BC. Spectral analysis criteria in duplex scanning of aortoiliac and femoropopliteal arterial disease. *Ultrasound Med Biol* 1991;17:769-76. [CrossRef]
- Legemate DA, Teeuwen C, Hoeneveld H, Eikelboom BC. Value of duplex scanning compared with angiography and pressure measurement in the assessment of aortoiliac arterial lesions. *Br J Surg* 1991;78:1003-8. [CrossRef]
- Hatsukami TS, Primozich JF, Zierler RE, Harley JD, Strandness DE Jr. Color Doppler imaging of infrainguinal arterial occlusive disease. *J Vasc Surg* 1992;16:527-31. [CrossRef]
- Linke RJ, Davies RP, Giles AJ, Walsh JA, Thompson BW. Colour duplex ultrasound: a screening modality for femoropopliteal disease in patients with intermittent claudication. *Australas Radiol* 1994;38:320-3. [CrossRef]
- Bergamini TM, Tatum CM Jr, Marshall C, Hall-Disselkamp B, Richardson JD. Effect of multilevel sequential stenosis on lower extremity arterial duplex scanning. *Am J Surg* 1995;169:564-6. [CrossRef]
- Sensier Y, Hartshorne T, Thrush A, Nydahl S, Bolia A, London NJ. A prospective comparison of lower limb colour-coded Duplex scanning with arteriography. *Eur J Vasc Endovasc Surg* 1996;11:170-5. [CrossRef]
- Sensier Y, Fishwick G, Owen R, Pemberton M, Bell PR, London NJ. A comparison between colour duplex ultrasonography and arteriography for imaging infrapopliteal arterial lesions. *Eur J Vasc Endovasc Surg* 1998;15:44-50. [CrossRef]
- Aly S, Sommerville K, Adiseshiah M, Raphael M, Coleridge Smith PD, Bishop CC. Comparison of duplex imaging and arteriography in the evaluation of lower limb arteries. *Br J Surg* 1998;85:1099-102. [CrossRef]
- Collins R, Burch J, Cranny G, Aguiar-Ibáñez R, Craig D, Wright K, et al. Duplex ultrasonography, magnetic resonance angiography, and computed tomography angiography for diagnosis and assessment of symptomatic, lower limb peripheral arterial disease: systematic review. *BMJ* 2007;334:1257.
- Mulligan SA, Matsuda T, Lanzer P, Gross GM, Routh WD, Keller FS, et al. Peripheral arterial occlusive disease: prospective comparison of MR angiography and color duplex US with conventional angiography. *Radiology* 1991;178:695-700.
- Wikström J, Holmberg A, Johansson L, Löfberg AM, Smedby O, Karacagil S, et al. Gadolinium-enhanced magnetic reso-



- nance angiography, digital subtraction angiography and duplex of the iliac arteries compared with intra-arterial pressure gradient measurements. *Eur J Vasc Endovasc Surg* 2000;19:516-23. [\[CrossRef\]](#)
29. Visser K, Hunink MG. Peripheral arterial disease: gadolinium-enhanced MR angiography versus color-guided duplex US—a meta-analysis. *Radiology* 2000;216:67-77.
30. Leiner T, Kessels AG, Nelemans PJ, Vasbinder GB, de Haan MW, Kitslaar PE, et al. Peripheral arterial disease: comparison of color duplex US and contrast-enhanced MR angiography for diagnosis. *Radiology* 2005;235:699-708. [\[CrossRef\]](#)
31. Bueno A, Acín F, Cañibano C, Fernandez-Casado JL, Castillo E. Diagnostic accuracy of contrast-enhanced magnetic resonance angiography and duplex ultrasound in patients with peripheral vascular disease. *Vasc Endovascular Surg* 2010;44:576-85. [\[CrossRef\]](#)
32. Soule B, Hingorani A, Ascher E, Kallakuri S, Yorkovich W, Markevich N, et al. Comparison of Magnetic Resonance Angiography (MRA) and Duplex Ultrasound Arterial Mapping (DUAM) prior to infrainguinal arterial reconstruction. *Eur J Vasc Endovasc Surg* 2003;25:139-46. [\[CrossRef\]](#)
33. Hingorani A, Ascher E, Markevich N, Kallakuri S, Hou A, Schutzer R, et al. Magnetic resonance angiography versus duplex arteriography in patients undergoing lower extremity revascularization: which is the best replacement for contrast arteriography? *J Vasc Surg* 2004;39:717-22. [\[CrossRef\]](#)
34. Ascher E, Hingorani A, Markevich N, Schutzer R, Kallakuri S. Acute lower limb ischemia: the value of duplex ultrasound arterial mapping (DUAM) as the sole preoperative imaging technique. *Ann Vasc Surg* 2003;17:284-9. [\[CrossRef\]](#)
35. Ascher E, Hingorani A, Markevich N, Yorkovich W, Schutzer R, Hou A, et al. Role of duplex arteriography as the sole preoperative imaging modality prior to lower extremity revascularization surgery in diabetic and renal patients. *Ann Vasc Surg* 2004;18:433-9. [\[CrossRef\]](#)
36. Ascher E, Marks NA, Hingorani AP, Schutzer RW, Mutyala M. Duplex-guided endovascular treatment for occlusive and stenotic lesions of the femoral-popliteal arterial segment: a comparative study in the first 253 cases. *J Vasc Surg* 2006;44:1230-8. [\[CrossRef\]](#)
37. Hirsch AT, Haskal ZJ, Hertzner NR, Bakal CW, Creager MA, Halperin JL, et al. ACC/AHA 2005 Practice Guidelines for the management of patients with peripheral arterial disease (lower extremity, renal, mesenteric, and abdominal aortic): a collaborative report from the American Association for Vascular Surgery/Society for Vascular Surgery, Society for Cardiovascular Angiography and Interventions, Society for Vascular Medicine and Biology, Society of Interventional Radiology, and the ACC/AHA Task Force on Practice Guidelines (Writing Committee to Develop Guidelines for the Management of Patients With Peripheral Arterial Disease): endorsed by the American Association of Cardiovascular and Pulmonary Rehabilitation; National Heart, Lung, and Blood Institute; Society for Vascular Nursing; TransAtlantic Inter-Society Consensus; and Vascular Disease Foundation. *Circulation* 2006;113:463-654. [\[CrossRef\]](#)
38. Creager MA, Belkin M, Bluth EI, Casey DE Jr, Chaturvedi S, Dake MD, et al. 2012 ACCF/AHA/ACR/SCAI/SIR/STS/SVM/SVN/SVS key data elements and definitions for peripheral atherosclerotic vascular disease: a report of the American College of Cardiology Foundation/American Heart Association Task Force on Clinical Data Standards (Writing Committee to Develop Clinical Data Standards for Peripheral Atherosclerotic Vascular Disease). *Circulation* 2012;125:395-467. [\[CrossRef\]](#)
39. Tendera M, Aboyans V, Bartelink ML, Baumgartner I, Clément D, Collet JP, et al. ESC Guidelines on the diagnosis and treatment of peripheral artery diseases: Document covering atherosclerotic disease of extracranial carotid and vertebral, mesenteric, renal, upper and lower extremity arteries: the Task Force on the Diagnosis and Treatment of Peripheral Artery Diseases of the European Society of Cardiology (ESC). *Eur Heart J* 2011;32:2851-906. [\[CrossRef\]](#)
40. Anderson JL, Halperin JL, Albert N, Bozkurt B, Brindis RG, Curtis LH, et al. Management of Patients With Peripheral Artery Disease (Compilation of 2005 and 2011 ACCF/AHA Guideline Recommendations): A Report of the American College of Cardiology Foundation/American Heart Association Task Force on Practice Guidelines. *J Am Coll Cardiol* 2013;61:1555-70. [\[CrossRef\]](#)
41. Brott TG, Halperin JL, Abbara S, Bacharach JM, Barr JD, Bush RL, et al. 2011 ASA/ACCF/AHA/AANN/AANS/ACR/ASNR/CNS/SAIP/SCAI/SIR/SNIS/SVM/SVS guideline on the management of patients with extracranial carotid and vertebral artery disease. *Circulation* 2011;124:e54-130. [\[CrossRef\]](#)
42. Winter-Warnars HA, van der Graaf Y, Mali WP. Interobserver variation in duplex sonographic scanning in the femoropopliteal tract. *J Ultrasound Med* 1996;15:421-30.
43. Koelemay MJ, Legemate DA, van Gorp JA, de Vos H, Balm R, Jacobs MJ. Interobserver variation of colour duplex scanning of the popliteal, tibial and pedal arteries. *Eur J Vasc Endovasc Surg* 2001;21:160-4. [\[CrossRef\]](#)
44. Legemate DA, Teeuwen C, Hoeneveld H, Ackerstaff RG, Eikelboom BC. The potential of duplex scanning to replace aorto-iliac and femoro-popliteal angiography. *Eur J Vasc Surg* 1989;3:49-54. [\[CrossRef\]](#)
45. Karacagil S, Löfberg AM, Granbo A, Lörelus LE, Bergqvist D. Value of duplex scanning in evaluation of crural and foot arteries in limbs with severe lower limb ischaemia—a prospective comparison with angiography. *Eur J Vasc Endovasc Surg* 1996;12:300-3. [\[CrossRef\]](#)
46. Hingorani AP, Ascher E, Marks N, Puggioni A, Shiferson A, Tran V, et al. Limitations of and lessons learned from clinical experience of 1,020 duplex arteriography. *Vascular* 2008;16:147-53. [\[CrossRef\]](#)
47. Hingorani A, Ascher E, Marks N. Preprocedural imaging: new options to reduce need for contrast angiography. *Semin Vasc Surg* 2007;20:15-28. [\[CrossRef\]](#)

**Key words:** Atherosclerosis; cardiovascular diseases; diagnosis, differential; diagnostic imaging; intermittent claudication; peripheral arterial disease; ultrasonography, Doppler.

**Anahtar sözcükler:** Ateroskleroz; kardiyovasküler hastalık; tanı, ayırıcı; tanısal görüntüleme; geçici topallama; periferik arter hastalığı; ultrasonografi, Doppler.