

A case of Mobitz type II atrioventricular block due to Nerium oleander poisoning successfully managed with digoxin-specific Fab antibody fragments

Zakkum zehirlenmesine bağılı olarak gelişen Mobitz tip II atriyoventriküler bloklı olgunun digoksin-spesifik Fab antikoru ile başarılı tedavisi

Mustafa Adem Tatlısu, M.D., Elif İjlal Çekirdekçi, M.D.,# Şükrü Akyüz, M.D.,* Zekeriya Nurkalem, M.D.†

Department of Cardiology, Sivas Numune State Hospital, Sivas

#Department of Cardiology, Corlu State Hospital, Tekirdag

*Department of Cardiology, Dr. Siyami Ersek Cardiovascular and Thoracic Surgery Hospital, Istanbul

†Department of Cardiology, Istanbul Medipol University Faculty of Medicine, Istanbul

Summary– *Nerium oleander* is a popular ornamental plant grown in many tropical and subtropical countries and in the Mediterranean region. It is dangerous because it has been shown to contain several types of cardiac glycosides, and hence can cause cardiac arrhythmias resembling digoxin in their toxicologic manifestations. We report a patient presenting to our hospital with Mobitz type II atrioventricular block after drinking herbal tea prepared from oleander leaves. Three hours after admission, a 200-mg empiric dose of digoxin-specific Fab antibody fragments was administered intravenously over 30 minutes. A 12-lead electrocardiogram (ECG) revealed sinus rhythm at the end of infusion. After 72 hours, the patient was discharged without any symptoms.

Özet– Zakkum (*Nerium oleander*) tropikal, subtropikal ve Akdeniz bölgesinde yetişen popüler bir süs bitkisidir. Çeşitli kalp glikozidleri içerdiği gösterilmiştir ve tehlikeli olabilmektedir. Bu yüzden zakkum zehirlenmesi, digoksinin toksik bulgularını taklit eden aritmilere neden olabilmektedir. Yazımızda zakkum yapraklarından yaptığı çayı içtikten sonra Mobitz tip II atriyoventriküler blok ile başvuran bir hasta sunuldu. Başvurusundan üç saat sonra, 200 mg'lık ampirik dozda digoksin-spesifik antikoru 30 dakikalık infüzyon şeklinde uygulandı. İnfüzyonun bitiminde, 12 derivasyonlu elektrokardiyogramda (EKG) sinüs ritmi izlendi. Hasta, 72 saat sonra herhangi bir semptomu olmadan taburcu edildi.

Herbal remedies are widely used for self-medication among the public, but if used indiscriminately can result in death.^[1,2] *Nerium oleander* is grown in many warmer regions worldwide as an ornamental shrub,^[3] and is also used in folk medicine for its antinociceptive and anti-inflammatory activity.^[4] However, because it contains cardiac glycosides, *Nerium oleander* poisoning can cause cardiac arrhythmias resembling digoxin in their toxicologic manifestations.^[5,6] All parts of the plant and the smoke from its being burned can cause poisoning.^[7]

Abbreviations:

ECG Electrocardiogram
RBBB Right bundle branch block

We report a patient presenting to our hospital with Mobitz type II atrioventricular block after drinking herbal tea prepared from oleander leaves.

CASE REPORT

A 18-year-old female presented to the emergency room with nausea, vomiting, lightheadedness, and abdominal pain 8 hours after drinking a cup of oleander tea. She had been advised to prepare oleander tea as part of weight loss regime.

On presentation, her blood pressure was 90/50 mmHg in the right arm and 85/50 mmHg in the left

Received: March 08, 2015 Accepted: June 11, 2015

Correspondence: Dr. Mustafa Adem Tatlısu. Sivas Numune Hastanesi, Kardiyoloji Kliniği, Rahmi Günay Caddesi, 58000 Sivas.

Tel: +90 346 - 444 44 58 e-mail: ademtatlısu@gmail.com

© 2015 Turkish Society of Cardiology



arm, with an irregular pulse of 40/min. The lungs were clear. A 12-lead electrocardiogram (ECG) on admission showed Mobitz type II atrioventricular block with right bundle branch block (RBBB), left anterior hemiblock, and T-wave inversions in leads V4 through V6 (Figure 1a). Transthoracic echocardiography showed a left ventricular ejection fraction (LVEF) of 65%, with mild tricuspid regurgitation, and no evidence of pulmonary hypertension or atrial septal defect. She was not taking any medical therapy. She was a non-alcoholic drinker and a non-smoker. Liver, renal, thyroid function tests were in normal range, and serum digoxin level was 4.1 ng/mL at admission. A temporary transvenous pacemaker was inserted via the right internal jugular vein under fluoroscopic visualization in order

to improve hemodynamic status. 6 mg intravenous atropine sulfate was administered, but failed to resolve the bradycardia. It was decided to treat the patient with digoxin-specific Fab antibody fragments. Three hours after admission, a 200-mg empiric dose of digoxin-specific Fab antibody fragments (DigiFab[®], 40 mg/vial Digoxin Immune Fab Powder for Solution for infusion, BTG International Ltd.) was administered intravenously over a period of 30 minutes. After 15 minutes of infusion, a 12-lead ECG showed first degree heart block, and a serum digoxin level of 2.08 ng/mL. A 12-lead ECG revealed sinus rhythm with RBBB at the end of infusion (Figure 1b). Serum digoxin level was 0.64 ng/mL 4 hours after infusion. After 72 hours, the patient was discharged without any symptoms.

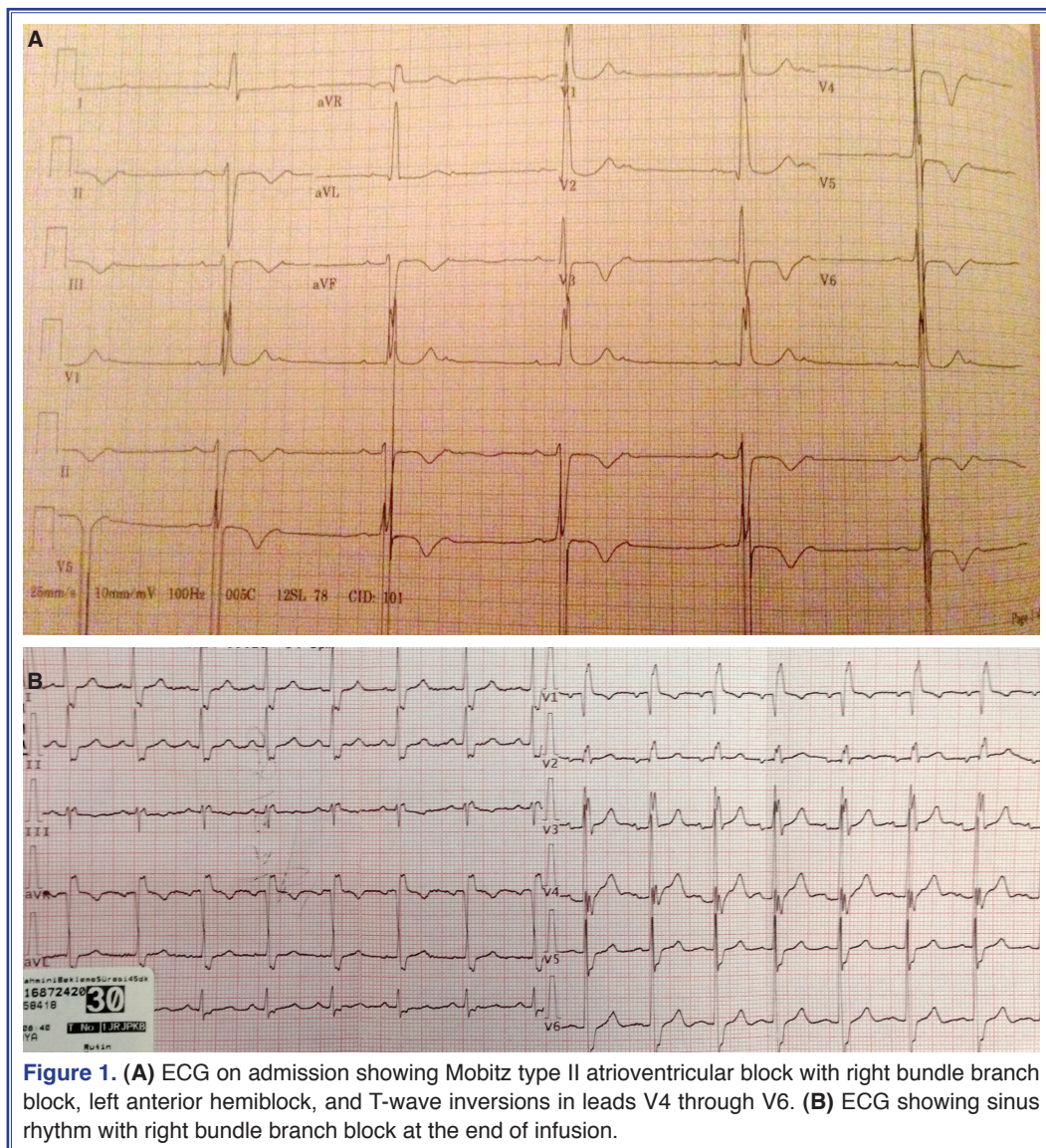


Figure 1. (A) ECG on admission showing Mobitz type II atrioventricular block with right bundle branch block, left anterior hemiblock, and T-wave inversions in leads V4 through V6. (B) ECG showing sinus rhythm with right bundle branch block at the end of infusion.

DISCUSSION

The oleander plant contains two potent cardiac glycosides: oleanderin and neriine.^[8] The mechanism of action of the oleander cardenolides is similar to that of the digitalis glycosides, i.e. inhibition of the cell membrane Na⁺/K⁺-adenosine triphosphatase pump.^[9] Thus, treatment of oleander intoxication is similar to digoxin intoxication treatment and includes the administration of fluids, atropine, isoproterenol, and temporary use of a cardiac pacemaker. Activated charcoal is recommended to interrupt enterohepatic circulation.^[10,11] Since the patient presented 8 hours after ingestion, the latter treatment was not used in our case.

In light of current evidence, the treatment of digoxin-specific Fab antibody fragment in the treatment of severe digoxin intoxication is commonly used.^[12] In severe cases of oleander poisoning complicated by hemodynamic instability, digoxin-specific Fab antibody fragments can be administered.^[13] Each vial of DigiFab® Digoxin Immune Fab (Ovine) contains 40 mg of purified digoxin-specific Fab, which will bind approximately 0.5 mg of digoxin. If the dose of ingestion is unknown, the number of vials can be calculated by a simple formula ($[\text{Serum digoxin concentration, ng/mL} \times \text{weight, kg}] \div 100$). Our patient weighed over 120 kg, hence our empiric dose was 200 mg (5 vials).

This report presented a rare case of Mobitz type II atrioventricular block due to Nerium oleander poisoning which was successfully managed with digoxin-specific Fab antibody fragments. It should be noted that as elevated pacing threshold or asystole unresponsive to pacing might occur in a portion of cases admitted with high degree atrioventricular block due to Nerium oleander poisoning, the authors strongly encourage the immediate use of digoxin-specific Fab antibody fragments in an effort to speed up hemodynamic improvement in these cases, particularly when the exact time of ingestion is unknown.

Conflict-of-interest issues regarding the authorship or article: None declared.

REFERENCES

1. Ansford AJ, Morris H. Fatal oleander poisoning. Med J Aust 1981;1:360–1.
2. Papi L, Luciani AB, Forni D, Giusiani M. Unexpected double lethal oleander poisoning. Am J Forensic Med Pathol 2012;33:93–7. [CrossRef](#)
3. Geehr E. Common toxic plant ingestions. Emerg Med Clin North Am 1984;2:553–62.
4. Erdemoglu N, Küpeli E, Yeşilada E. Anti-inflammatory and antinociceptive activity assessment of plants used as remedy in Turkish folk medicine. J Ethnopharmacol 2003;89:123–9.
5. Shaw D, Pearn J. Oleander poisoning. Med J Aust 1979;2:267–9.
6. Ansford AJ, Morris H. Fatal oleander poisoning. Med J Aust 1981;1:360–1.
7. Senthilkumaran S, Meenakshisundaram R, Michaels AD, Thirumalaikolundusubramanian P. Electrocardiographic changes during inhalational oleander toxicity. J Electrocardiol 2011;44:470–2. [CrossRef](#)
8. Shumaik GM, Wu AW, Ping AC. Oleander poisoning: treatment with digoxin-specific Fab antibody fragments. Ann Emerg Med 1988;17:732–5. [CrossRef](#)
9. Hollman A. Plants and cardiac glycosides. Br Heart J 1985;54:258–61. [CrossRef](#)
10. Driggers DA, Solbrig R, Steiner JF, Swedberg J, Jewell GS. Acute oleander poisoning. A suicide attempt in a geriatric patient. West J Med 1989;151:660–2.
11. Küçükdurmaz Z, Karapinar H, Gül I, Yılmaz A. Complete atrioventricular block after self-ingestion of Nerium oleander for relief of hemorrhoidal complaints. Turk Kardiyol Dern Ars 2012;40:168–70. [CrossRef](#)
12. Mann DL. Management of patients with heart failure with reduced ejection fraction. In: Mann DL, Zipes DP, Libby P, Bonow RO, Braunwald E, editors. Braunwald's Heart Disease: A Textbook of Cardiovascular Medicine. 10th ed. Philadelphia: Elsevier Saunders; 2015. p. 534.
13. Safadi R, Levy I, Amitai Y, Caraco Y. Beneficial effect of digoxin-specific Fab antibody fragments in oleander intoxication. Arch Intern Med 1995;155:2121–5. [CrossRef](#)

Keywords: Atrioventricular block; Nerium oleander; digoxin/adverse effects.

Anahtar sözcükler: Atriyoventriküler blok; Nerium oleander; digoxin/yan etki