

The use of low molecular weight heparin during pregnancy in patients with mechanical heart valves carries potential risk for valve thrombosis: a report of three cases

Mekanik protez kalp kapağı olan gebelerde düşük molekül ağırlıklı heparinlerin kullanımı protez kapak trombozu riski taşır: Üç olguluk bir sunum

Utku Şenol, M.D., Taner Ulus, M.D., Alparslan Birdane, M.D., Yüksel Çavuşoğlu, M.D.

Department of Cardiology, Eskisehir Osmangazi University Faculty of Medicine, Eskisehir

Summary– Pregnancy is associated with an increased risk of valve thrombosis, hemorrhagic complications, and offspring complications in patients with metallic prosthetic heart valve (MHV). Warfarin treatment is the best regimen against thromboembolic complications, but its use in the first trimester can result in embryopathy. Low molecular weight heparin (LMWH) does not cross the placenta and has some potential advantages. However, the pharmacokinetics of LMWHs change during pregnancy, and serial monitoring of anti-Xa levels is strongly recommended. Despite this recommendation, LMWH therapy in a fixed dose is still used in pregnant women with MHV without monitoring anti-Xa activity in clinical practice. We present three cases of MHV thrombosis occurring while on therapy with LMWH during pregnancy. One of these patients showed cerebrovascular event, one presented with pulmonary edema, and one underwent reoperation for MHV thrombosis.

Pregnancy is associated with an increased risk of valve thrombosis, hemorrhagic complications, and offspring complications in patients with metallic prosthetic heart valve (MHV). For this reason, pregnancy increases maternal risk in such patients. The magnitude of the risk is related with the anticoagulant regimen used during pregnancy and the effectiveness of anticoagulation.^[1]

Warfarin treatment is the best and most reliable strategy against thromboembolic complications in pregnant women with MHV. However, warfarin crosses the placenta and its use in the first trimester can result

Özet– Mekanik protez kalp kapağı (MPK) olan hastalarda gebelik artmış kapak trombozu, kanama ve fetal komplikasyon riski ile ilişkilidir. Tromboembolik komplikasyonlara karşı en etkili tedavi varfarin kullanımı olmakla birlikte, ilk trimesterde varfarin kullanımı embriyopatiye sebep olabilir. Düşük molekül ağırlıklı heparinler (DMAH) plasentayı geçmez ve potansiyel bazı avantajları vardır. Bununla birlikte, DMAH'lerin farmakokinetiği gebelik esnasında değişir ve faktör 10a seviyelerinin düzenli monitörizasyonu kuvvetle önerilir. Bu öneriye rağmen, halen DMAH'ler MPK olan gebelerde faktör 10a düzeyi takip edilmeden sabit dozda kullanılmaktadır. Burada gebelikleri esnasında DMAH tedavisi altında MPK trombozu gelişen üç olguyu sunduk. Bir olguda serebrovasküler olay gelişti, bir olgu akut akciğer ödemi tablosuyla başvurdu, bir diğeri ise MPK trombozu nedeniyle tekrar kapak operasyonuna alındı.

in embryopathy in 6.4% of the cases.^[2]

Low molecular weight heparin (LMWH) in therapeutic doses is an alternative method in patients with MHV.

Embryopathy does not occur with LMWH because it does not cross the placenta.^[1] Anticoagulation is more stable and predictable with LMWH than unfractionated heparin (UFH). On the other hand, LMWHs are

Abbreviations:

INR	International normalization ratio
LMWH	Low molecular weight heparin
MHV	Metallic prosthetic heart valve
MVR	Mitral valve replacement
OACs	Oral anticoagulants
TEE	Transesophageal echocardiography
TTE	Transthoracic echocardiography
UFH	Unfractionated heparin

Received: August 22, 2013 Accepted: November 20, 2013

Correspondence: Dr. Taner Ulus. Eskisehir Osmangazi Üniversitesi Tıp Fakültesi, Kardiyoloji Anabilim Dalı, 26200 Eskisehir, Turkey.

Tel: +90 222 - 239 29 79 / 3700 e-mail: tanerulusbuca@gmail.com

© 2014 Turkish Society of Cardiology



also associated with the risk of MHV thrombosis.^[3,4] Despite some advantages, the use of LMWH during pregnancy in women with MHV is still controversial.

We present three pregnant women with MHV referred to our hospital between 2010 and 2012. They were not on acetylsalicylic acid therapy on admission. Enoxaparin had been given in therapeutic fixed doses in all cases.

CASE REPORT

Case 1— An 18-year-old female with rheumatic mitral stenosis and aortic regurgitation had undergone surgery two years before for mitral and aortic valve replacement (MVR and AVR) with a bileaflet MHV (Sorin 33 mm) for mitral valve and bileaflet MHV (Sorin 23 mm) for aortic valve. She was referred to our hospital in the 9th week of pregnancy with palpitation and acute neurological deficit in the left arm, which resolved completely in 24 hours. The electrocardiogram (ECG) revealed normal sinus rhythm. She had been treated with subcutaneous enoxaparin, 70 mg twice daily, since the beginning of the pregnancy. Transthoracic and transesophageal echocardiography (TTE and TEE) depicted 6 mm fibrillar thrombus in the aortic prosthetic valve and thrombi in the mitral prosthetic valve (Figure 1a, b). The mean gradient was 10.5 mmHg in the mitral valve and 31 mmHg in the aortic valve. Cerebral computed tomography (CT) was normal and transient ischemic attack was diag-

nosed. The patient was hospitalized based on echocardiographic findings. Enoxaparin was stopped and UFH was started. She and her husband were informed about the risks and the pregnancy was terminated after their approval. UFH was started six hours after delivery and was given for four days until international normalization ratio (INR) was >2.5 . Warfarin was started one day after delivery and INR was maintained between 3.5 and 4.5. She had no complaints, and no prosthetic valve thrombus was seen in the follow-up echocardiography performed three months later. The mean gradient was 5.2 mmHg in the mitral valve and 25.9 mmHg in the aortic valve.

Case 2— A 36-year-old female with rheumatic mitral stenosis had undergone surgery four years before for MVR with a bileaflet MHV (Sorin 29 mm) for the mitral valve. The patient was admitted to our coronary care unit with pulmonary edema in the 33rd week of pregnancy. Subcutaneous enoxaparin had been initiated 60 mg twice daily since the beginning of her pregnancy. The ECG revealed normal sinus rhythm. Urgent TTE and TEE demonstrated thrombi and a 10.5 mmHg mean gradient in the mitral prosthetic valve (Figure 2). The patient was hospitalized, enoxaparin was stopped, and UFH was started. Nitroglycerine (up to 80 $\mu\text{g}/\text{min}$) and furosemide (up to 120 mg/day) were given. She and her relatives were informed, and cesarean section was carried out upon the obstetrician's suggestion in the 34th week of pregnancy. Healthy twins were delivered. Postpartum

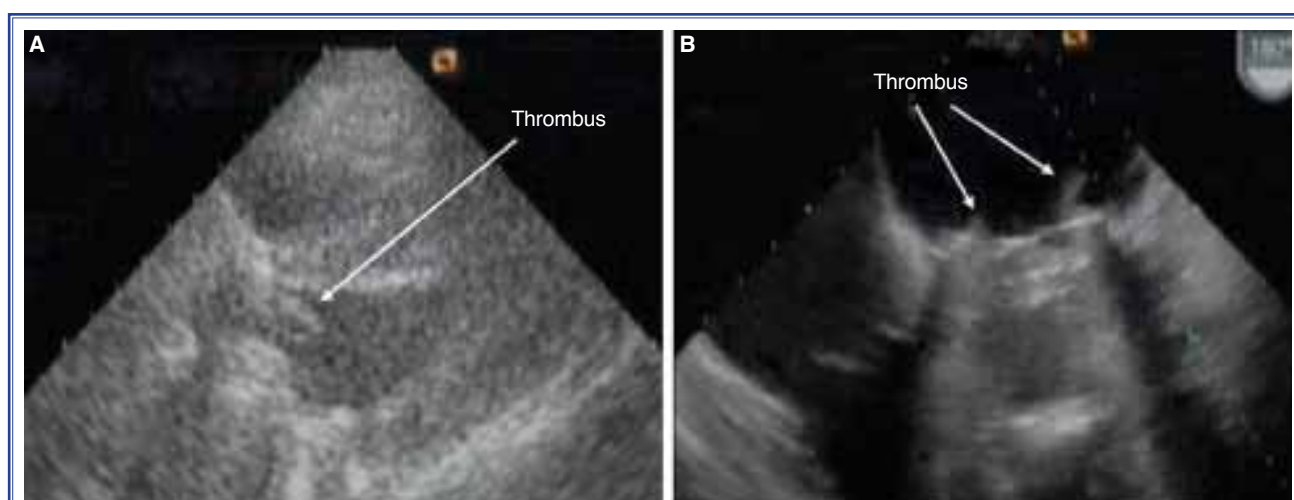


Figure 1. (A) The TEE view of Case 1 demonstrating multiple thrombi on the left atrial aspect of the mitral prosthesis; (B) A TTE demonstrating a fibrillar thrombus on the left ventricular aspect of the aortic prosthesis. TEE: Transesophageal echocardiography, TTE: Transthoracic echocardiography.

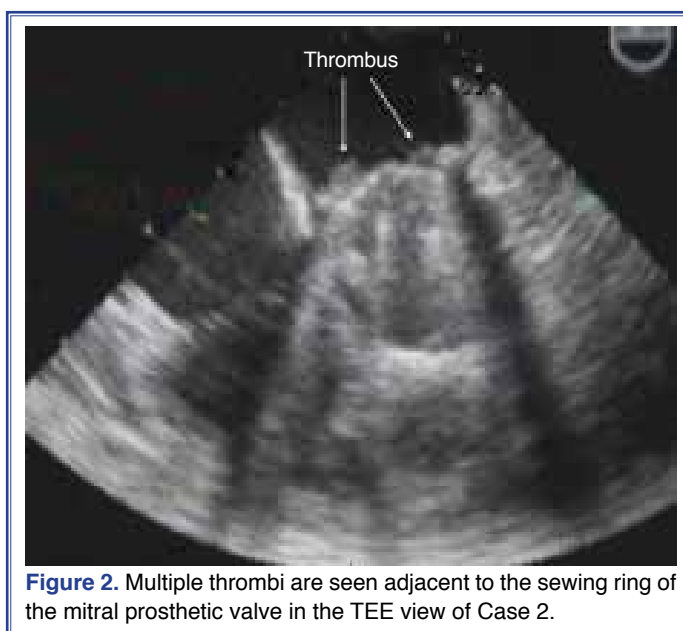


Figure 2. Multiple thrombi are seen adjacent to the sewing ring of the mitral prosthetic valve in the TEE view of Case 2.

hemorrhage of 100 ml was detected after the delivery. No further hemorrhage occurred during the follow-up. UFH was started 12 hours after delivery and was given for five days until INR was >2.5 . Warfarin was started two days after delivery. The patient had no complaint three months later, and the INR ratio was maintained between 3.5 and 4.5 in this period. Mitral prosthetic valve thrombus was seen, but diminished, in the follow-up echocardiography performed three months later.

Case 3– A 25-year-old female with rheumatic mitral stenosis and regurgitation had undergone surgery nine years before for MVR with a bileaflet MHV (Sorin 27 mm) for mitral valve. She was admitted with New

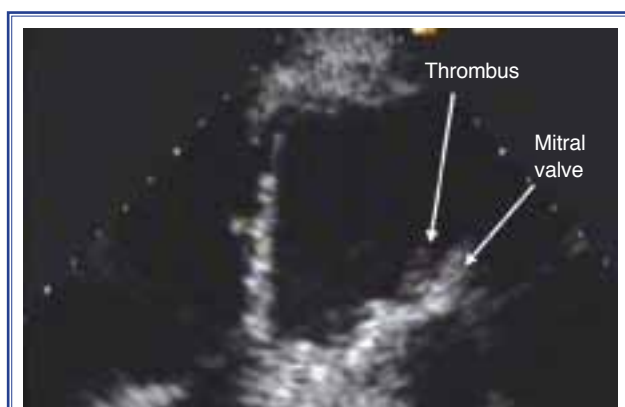

Figure 3. The TEE view of Case 3 demonstrating a thrombus on the left atrial aspect of the mitral prosthesis.

York Heart Association (NYHA) class II dyspnea for 10 days in the 21st week of pregnancy. On the physical examination, MHV sound was heard, and the lung examination was normal. The ECG revealed atrial fibrillation. TTE demonstrated thrombus and a mean gradient of 12 mmHg in the mitral prosthetic valve (Figure 3). She had been treated with subcutaneous enoxaparin, 60 mg twice daily, since the 2nd week of her pregnancy. The patient was hospitalized, enoxaparin was stopped, and warfarin was started. UFH was added and continued until INR was >2.5 . She and her relatives were informed about the risks of pregnancy, and continuation of the pregnancy was decided. The patient was followed closely, and INR was maintained between 3.5 and 4.5. The patient became symptomatic (NYHA class III dyspnea and palpitation) in the 34th week. Cesarean section was carried out in the 35th week of pregnancy without complication, and the baby was healthy. Warfarin was stopped seven days before the delivery and UFH was started. Warfarin was restarted two days after the delivery. Postpartum hemorrhage of 150 ml occurred after the delivery, and one unit of erythrocyte suspension was administered. Follow-up hemoglobin level was 12.0 g/dl. She had dyspnea at rest, palpitation and fatigue after the delivery. No change in the thrombus or the mean gradient (12 mmHg) was detected in the follow-up echocardiography. The patient underwent MVR through a right atriotomy and a transseptal approach. A large thrombus was observed on the mitral prosthesis block-

ing one disk. A new mechanical bileaflet valve (Sorin 27 mm) was implanted. The postoperative course was uneventful, and warfarin was resumed.

DISCUSSION

We present herein three cases of MHV thrombosis while under treatment with LMWH during pregnancy in the absence of anti-Xa level monitoring. All the patients had been referred to our hospital from other clinics after the development of thromboembolic complications. One of these patients showed cerebrovascular event, one presented with pulmonary edema, and one underwent reoperation for MHV thrombosis. Unfortunately, we could not determine the incidence of thrombosis related to LMWHs in pregnant women with MHV without anti-Xa level monitoring because we do not prefer LMWHs in such patients.

Mechanical heart valves are related to thrombotic complications, which are more frequent during pregnancy. Effective anticoagulation is mandatory in pregnant women with MHV. Anticoagulation with oral anticoagulants (OACs) throughout pregnancy is the best method in such cases. With OACs throughout pregnancy, the risk of valve thrombus is 3.9%.^[2] This risk is the highest with adjusted-dose or low-dose UFH throughout pregnancy (33%).^[2] The risk was between 7.1-12.3% with LMWH throughout pregnancy in studies with patients compliant with medication and with testing of anti-Xa levels.^[3,4] These data were compiled from three non-randomized studies.^[2-4] The risk of fetal malformation with OACs throughout pregnancy suggests this regimen should be preferred only when warfarin dose is <5 mg, a safe level for embryopathy, or in women with highly thrombogenic MHV.^[2,5]

Unfractionated heparin (UFH) and LMWH do not cross the placenta, and embryopathy does not occur. Substitution of OACs with UFH or LMWH between 6 and 12 weeks greatly decreases the risk of fetal malformations.^[2] The risk of thromboembolism is lower when UFH or LMWH is used in the first trimester only rather than throughout pregnancy. With LMWH in the first trimester, the risk was found to be 3.6%.^[6]

Low molecular weight heparins (LMWH) have improved pharmacokinetics and side effect profile compared to UFH. They cause less heparin-induced thrombocytopenia and less osteoporosis when compared to UFH usage.^[7] On the other hand, the clearance and volume of distribution of LMWHs are high-

er during pregnancy. Therefore, regular monitoring of anti-Xa levels in pregnancy is necessary, and the administration of LMWHs on the basis of weight alone is inadequate.^[8,9] The European Society of Cardiology guidelines advise weekly monitoring of peak anti-Xa levels, which should be maintained between 0.8 and 1.2 U/mL, 4-6 hours after application.^[2]

Despite several potential advantages, the use of LMWH in pregnancy is limited due to the lack of data about its efficacy and safety and regular monitoring of anti-Xa levels. The risk of thromboembolism may be as high as 20% in the absence of monitoring.^[10]

Our cases indicate LMWH therapy in a fixed dose is still used in pregnant women with MHV without monitoring anti-Xa activity and is related with serious thromboembolic complications, such as cerebrovascular event, pulmonary edema and reoperation for prosthetic valve thrombus. For this reason, in the absence of anti-Xa level monitoring, pregnant women with MHV should not be treated with a fixed dose of LMWH, as such treatment likely results in ineffective anticoagulation.

Conflict-of-interest issues regarding the authorship or article: None declared.

REFERENCES

1. Regitz-Zagrosek V, Blomstrom Lundqvist C, Borghi C, Cifkova R, Ferreira R, Foidart JM, et al. ESC Guidelines on the management of cardiovascular diseases during pregnancy: the Task Force on the Management of Cardiovascular Diseases during Pregnancy of the European Society of Cardiology (ESC). *Eur Heart J* 2011;32:3147-97. [CrossRef](#)
2. Chan WS, Anand S, Ginsberg JS. Anticoagulation of pregnant women with mechanical heart valves: a systematic review of the literature. *Arch Intern Med* 2000;160:191-6. [CrossRef](#)
3. Oran B, Lee-Parritz A, Ansell J. Low molecular weight heparin for the prophylaxis of thromboembolism in women with prosthetic mechanical heart valves during pregnancy. *Thromb Haemost* 2004;92:747-51.
4. McLintock C, McCowan LM, North RA. Maternal complications and pregnancy outcome in women with mechanical prosthetic heart valves treated with enoxaparin. *BJOG* 2009;116:1585-92. [CrossRef](#)
5. Arnaout MS, Kazma H, Khalil A, Shasha N, Nasrallah A, Karam K, et al. Is there a safe anticoagulation protocol for pregnant women with prosthetic valves? *Clin Exp Obstet Gynecol* 1998;25:101-4.
6. Elkayam U, Singh H, Irani A, Akhter MW. Anticoagulation in pregnant women with prosthetic heart valves. *J Cardiovasc Pharmacol Ther* 2004;9:107-15. [CrossRef](#)

7. Abildgaard U, Sandset PM, Hammerstrøm J, Gjestvang FT, Tveit A. Management of pregnant women with mechanical heart valve prosthesis: thromboprophylaxis with low molecular weight heparin. *Thromb Res* 2009;124:262-7. [CrossRef](#)
8. Saeed CR, Frank JB, Pravin M, Aziz RH, Serasheini M, Dominique TG. A prospective trial showing the safety of adjusted-dose enoxaparin for thromboprophylaxis of pregnant women with mechanical prosthetic heart valves. *Clin Appl Thromb Hemost* 2011;17:313-9. [CrossRef](#)
9. Casele HL, Laifer SA, Woelkers DA, Venkataramanan R. Changes in the pharmacokinetics of the low-molecular-weight heparin enoxaparin sodium during pregnancy. *Am J Obstet Gynecol* 1999;181:1113-7. [CrossRef](#)
10. Elkayam U, Bitar F. Valvular heart disease and pregnancy: part II: prosthetic valves. *J Am Coll Cardiol* 2005;46:403-10.

Key words: Heart valve diseases/diagnosis; heart valve prosthesis; heparin, low-molecular-weight; pregnancy; thromboembolism.

Anahtar sözcükler: Kalp kapak hastalıkları/tanı; kalp kapak protezi; heparin, düşük molekül ağırlıklı; hamilelik; tromboemboli.