

Heart failure after transvenous closure of atrial septal defect associated with atrial standstill and thiamine-responsive megaloblastic anemia

Sessiz atriyum ve tiyamin yanıtli megaloblastik aneminin eşlik ettiği atriyal septal defekti olan bir çocukta transvenöz kapatma sonrası gelişen kalp yetersizliği

Vehbi Doğan, M.D., Filiz Şenocak, M.D.,# Utku Arman Örün, M.D.,# Özben Ceylan, M.D.#

Department of Pediatric Cardiology, Gaziosmanpaşa University Faculty of Medicine, Tokat;

#Department of Pediatric Cardiology, Dr. Sami Ulus Maternity And Children, Ankara

Summary– Despite advances in device closure for atrial septal defect, post-closure heart failure remains a clinical problem in adult patients but is seen only rarely in children. An eight-year-old boy, who had been followed by a local pediatrician with the diagnosis of diabetes mellitus and congenital heart disease, was consulted to us for cardiac re-evaluation. Electrocardiography demonstrated absent P waves, and echocardiography revealed enlargement of the right ventricle and both atria and secundum atrial septal defect. With the diagnosis of atrial standstill, secundum atrial septal defect and thiamine-responsive megaloblastic anemia, acute heart failure developed after transvenous closure of the atrial septal defect, which improved dramatically with thiamine and supportive treatment.

Özet– Atriyal septal defektlerin transvenöz yolla kapatılması konusunda kaydedilen gelişmelere rağmen, kapatma sonrası özellikle erişkin hastalarda kalp yetersizliği halen problem olmaya devam etmekte iken çocuklarda bu sorun nadirdir. Diabetes mellitus ve doğumsal kalp hastalığı tanılılarıyla bir merkezde izlenmekte olan 8 yaşında erkek hasta için kardiyak açıdan tekrar değerlendirilmesi amacıyla konsültasyon yapıldı. Elektrokardiyografide P dalgasının olmadığı, eko-kardiyografide ise sağ ventrikül ve her iki atriyumun normalden geniş olduğu ve atriyumlar arası septumda sekundum tip atriyal septal defekt bulunduğu saptandı. Sessiz atriyum, sekundum atriyal septal defekt ve tiyamin yanıtli megaloblastik anemi tanısı konan hastada transvenöz yolla atriyal septal defektin kapatılmasının ardından tiyamin ve destek tedavisi ile dramatik olarak gerileyen kalp yetersizliği gelişti.

Heart failure after device closure of an atrial septal defect remains a clinical problem for adult patients, but it is seen only rarely in children.^[1-4] In these patients, successful occlusion of the left-to-right shunt imparted an acute volume loading to the poorly compliant left ventricle, resulting in pulmonary edema due to hyperacute diastolic heart failure. Post-closure heart failure was also reported in young adult patients with hypertrophic cardiomyopathy.^[4] In this report, a case of acute post-closure heart failure observed in an eight-year-old boy is presented.

CASE REPORT

The patient's first admission to our clinic was because of heart murmur at the age of five months. Echocardiography revealed enlarged right ventricle and right/left atria with secundum atrial septal defect. Since there was no detectable "P" wave in electrocardiography, his family was advised that additional investigations and follow-up were necessary, but they did not present again until May 2009, when the patient was eight years old. During this period, he had been

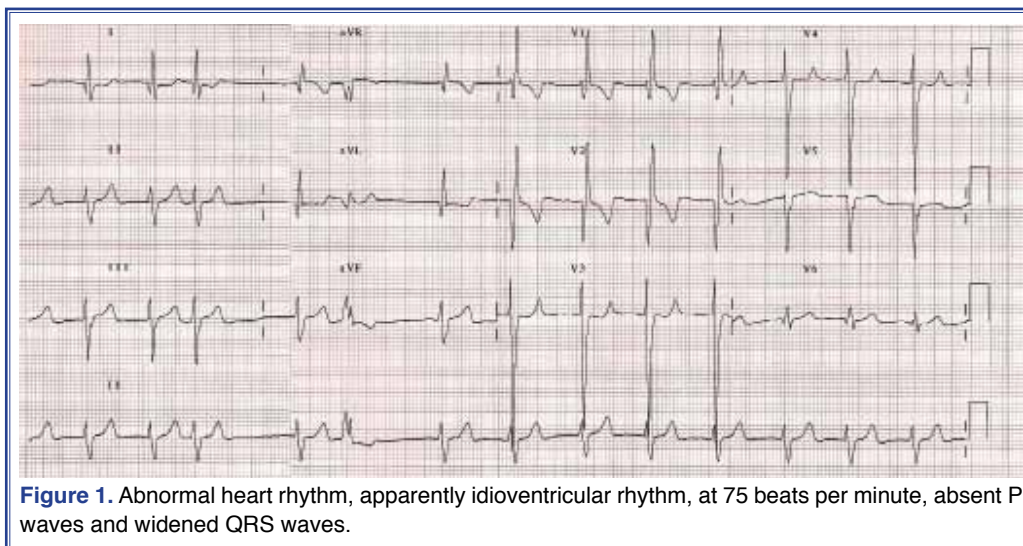
Received: December 10, 2012 Accepted: January 28, 2013

Correspondence: Dr. Vehbi Doğan. Gaziosmanpaşa Üniversitesi Hastanesi, Pediatrik Kardiyoloji Bölümü, 60100 Tokat, Turkey.

Tel: +90 356 - 212 95 00 e-mail: vdogan86@yahoo.com

© 2013 Turkish Society of Cardiology





followed by a local pediatrician with the diagnosis of type-1 diabetes mellitus and congenital heart disease, and was treated with insulin and angiotensin converting enzyme inhibitor.

The patient was referred to the pediatric Cardiology and Endocrinology Departments for reevaluation at eight years of age. Cardiovascular examination demonstrated II/VI systolic low-pitched murmur heard best at the mid left sternal border, heart rate of 72 bpm and blood pressure of 105/60 mmHg. Physical examination also revealed periumbilical lipodystrophy and bilateral sensorineural deafness, for which he was using a hearing aid.

Hemoglobin concentration was 11.8 g/dl, with a mean corpuscular volume of 85 fL. Liver, kidney and

thyroid function tests were normal. HbA1C concentration was 13.2%. Peripheral smear showed macrocytosis, anisocytosis and poikilocytosis, suggesting megaloblastic anemia. Serum ferritin, vitamin B12, and red blood cell folate levels were in normal range.

The 12-channel electrocardiography demonstrated absent P waves and junctional QRS complex (Fig. 1). Echocardiography revealed enlarged right ventricle and right/left atria, secundum atrial septal defect, tricuspid regurgitation, absence of “a” waves in the atrial pressure curve, and absence of atrial contraction with tissue Doppler imaging (Fig. 2). Ejection fraction and fractional shortening were found to be 62% and 33%, respectively. Average heart rate in 24-hour Holter electrocardiogram was 72 bpm. Atrial standstill was

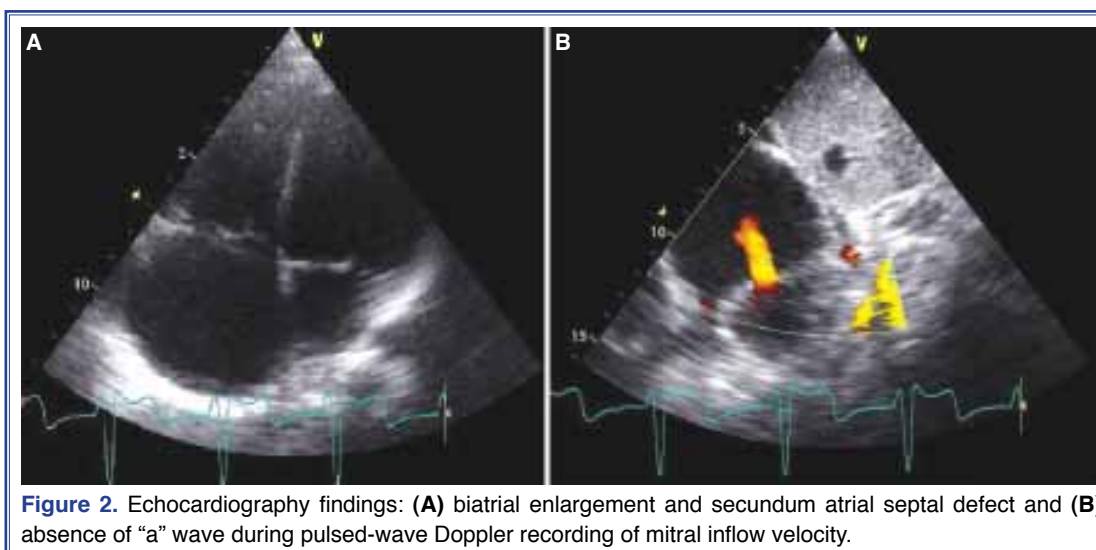

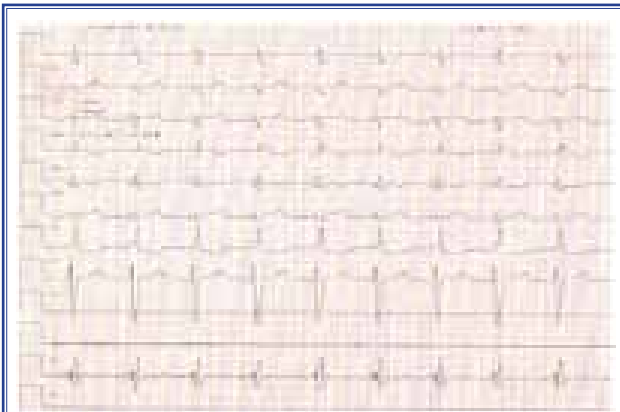


Figure 3. Transesophageal electrophysiologic study showed absence of atrial electrical activity in basal state.

considered, and transesophageal electrophysiologic study was performed to ascertain the cause for absent P waves and the junctional rhythm. No atrial electrical activity was recorded in basal state (Fig. 3). Cardiac catheterization accompanied with transesophageal echocardiography was performed, with the following findings of mean pressures (mmHg): pulmonary artery 23, left atrium 8 and descending aorta 66. The ratio of pulmonary to systemic flow (Q_p/Q_s) was found to be 2.77. Atrial septal defect was closed with 9 mm Amplatzer Septal Occluder[®].

Twenty-four hours after the procedure, hepatomegaly, mild tachypnea and tachycardia were noted. On auscultation of lungs, bilateral fine crackles were detected and cardiomegaly was present in the chest X-

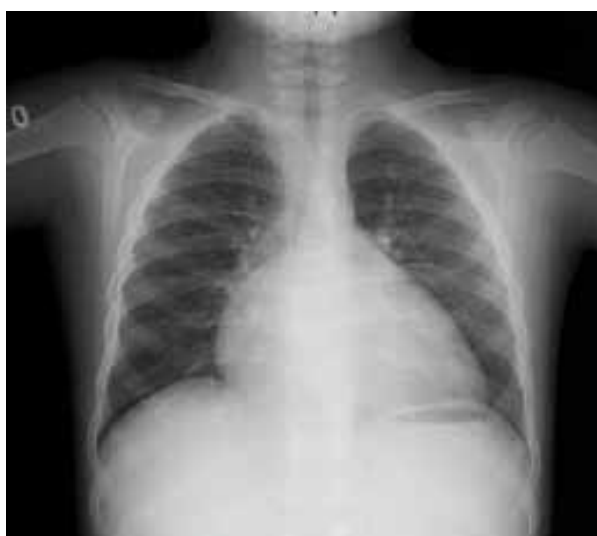

Figure 4. Chest X-ray after transvenous closure of atrial septal defect demonstrating cardiomegaly.

ray (Fig. 4). Echocardiographic examination revealed an enlarged right ventricle, reduced left ventricular ejection fraction (EF: 40%), low cardiac output, and significant tricuspid and mitral regurgitation without any residual shunt in the atrial septum. Serious congestive heart failure developed, and dopamine 7 mcg/kg/min was added to the treatment protocol. Meanwhile, with the findings of megaloblastic anemia, diabetes mellitus and sensorineural deafness, the diagnosis of thiamine-responsive megaloblastic anemia was considered. Plasma thiamine concentration was found to be 20 g/dl (normal range: 25-75 g/dl), which supported this diagnosis. Thiamine hydrochloride (100 mg/day, per oral) was added. Heart failure improved dramatically in the next 48-72 hours of treatment.

The diagnosis of thiamine-responsive megaloblastic anemia was proven with demonstration of a 2 base-pair deletion in exon 4 (1147delGT) of the *SLC19A2* gene. At the follow-up at 12 months, transthoracic echocardiography demonstrated improved left ventricular function without any residual shunt. There was no improvement in the rhythm, and a mean heart rate of 74 bpm was recorded in the 24-hour Holter electrocardiogram.

DISCUSSION

In our case, both diastolic and systolic heart failure developed on the day following successful closure of the defect, and it improved dramatically with supportive treatment accompanied by thiamine hydrochloride. The associated conditions of atrial standstill and possible cardiomyopathy due to thiamine-responsive megaloblastic anemia were thought to be the most important contributing factors in the development of heart failure.

Our patient was diagnosed with thiamine-responsive megaloblastic anemia, associated with congenital cardiac defects, atrial dysrhythmia and cardiomyopathy. Especially right heart-predominant cardiomyopathy has been reported with thiamine-responsive megaloblastic anemia. Varying degrees of improvement in cardiomyopathy and cardiac rhythm have been achieved with thiamine treatment.^[5-7]

Atrial standstill was considered as another contributing factor for the heart failure in our patient. Although the heart rate of our patient was normal, absence of atrial contraction in the case of acute volume

overload to the left ventricle and probable cardiomyopathy due to thiamine-responsive megaloblastic anemia might have played a role in the development of heart failure. Malav et al.^[8] discussed a three-year-old patient with isolated secundum atrial septal defect, congenital atrial standstill and congestive heart failure. Surgical closure of the secundum atrial septal defect and permanent endocardial pacemaker implantation was done. Congestive heart failure, which was attributed to the large shunt as well as atrial standstill, improved after surgery. In cases of atrial standstill, prognosis depends on the underlying disease, and permanent pacemaker implantation is suggested in symptomatic patients.^[9,10] Heart failure symptoms in our patient resolved after simultaneous administration of dopamine and thiamine therapy. We could not distinguish whether dopamine or thiamine therapy was more effective. Since our patient's heart rate was in normal ranges, and heart failure resolved dramatically, we did not consider pacemaker for the patient.

To the best of our knowledge, this is the first case of atrial standstill and secundum atrial septal defect in which transcatheter closure was performed. With the observation of similar cases, more information can be gathered about the hemodynamics and electrophysiology in these cases. In conclusion, although known as a problem for adult patients, in younger patients such as our case, contributing factors like atrial dysrhythmia and poor ventricular compliance due to associated conditions (thiamine-responsive megaloblastic anemia in our patient) may lead to post-closure heart failure. A thorough understanding of the hemodynamic condition of atrial septal defect and associated conditions will reduce the complication of atrial septal defect closure.

Conflict-of-interest issues regarding the authorship or article: None declared.

REFERENCES

1. Viaene D, Vermeersch P, Van den Branden F. Pulmonary oedema after percutaneous ASD-closure. *Acta Cardiol* 2010;65:257-60.
2. Masutani S, Senzaki H. Left ventricular function in adult patients with atrial septal defect: implication for development of heart failure after transcatheter closure. *J Card Fail* 2011;17:957-63.
3. Masutani S, Taketazu M, Ishido H, Iwamoto Y, Yoshida S, Matsunaga T, et al. Effects of age on hemodynamic changes after transcatheter closure of atrial septal defect: importance of ventricular diastolic function. *Heart Vessels* 2012;27:71-8.
4. Zhang CJ, Huang YG, Huang XS. Acute left ventricular failure after transcatheter closure of a secundum atrial septal defect in a patient with hypertrophic cardiomyopathy. *Chin Med J (Engl)* 2011;124:618-21.
5. Porter FS, Rogers LE, Sidbury JB Jr. Thiamine-responsive megaloblastic anemia. *J Pediatr* 1969;74:494-504.
6. Lorber A, Gazit AZ, Khoury A, Schwartz Y, Mandel H. Cardiac manifestations in thiamine-responsive megaloblastic anemia syndrome. *Pediatr Cardiol* 2003;24:476-81.
7. Gritli S, Omar S, Tartaglino E, Guannouni S, Fleming JC, Steinkamp MP, et al. A novel mutation in the SLC19A2 gene in a Tunisian family with thiamine-responsive megaloblastic anaemia, diabetes and deafness syndrome. *Br J Haematol* 2001;113:508-13.
8. Malav IC, Juneja R, Choudhary SK, Ramakrishnan S, Ray R, Jain A. Atrial standstill causing congestive heart failure in a child with ostium secundum atrial septal defect. *Pediatr Cardiol* 2010;31:283-6.
9. Bensaid J, Vallat JM, Amsallem D, Bernard Y, Rauscher M, Borsotti JP. Total permanent auricular paralysis. Review of the literature apropos of 109 cases. *Ann Cardiol Angeiol (Paris)* 1995;44:139-45.
10. Bensaid J. Persistent atrial standstill documented over a 22-year period. *Am Heart J* 1996;131:404-7.

Key words: Anemia, megaloblastic; atrial standstill; child; electrocardiography; heart failure/etiology; heart septal defects, atrial; thiamine.

Anahtar sözcükler: Anemi, magloblastik; atriyal duraklama; çocuk; elektrokardiyografi; kalp yetersizliği/etiyojisi; kalp septal defekti, atriyal; tiyamin.